

UNIVERSITY OF VIRGINIA  
DEPARTMENT OF ORTHOPAEDIC SURGERY



STUDENT HANDBOOK FOR ORTHOPAEDIC SURGERY 2022

## **Table of Contents**

### **Part 1: Overview**

1. Introduction
  - How to Use this Handbook
  - About the Authors
2. UVA Program Information
  - Residents Welcome Message
  - Current Residents
  - General Information
  - Academics (Conference Schedule, etc)
  - UVA Health System Map

### **Part 2: Work Environments**

3. The Operating Room
4. The Floor
5. The Emergency Department
6. Nights On Call
7. Student Talks and Journal Article Presentations

### **Part 3: Orthopaedic Divisions**

9. Adult Reconstruction
10. Foot and Ankle
11. Hand/Upper Extremity
12. Pediatrics
13. Spine
14. Sports Medicine
15. Trauma

### References

### Acknowledgements

## **PART 1: OVERVIEW**

### **I. Introduction**

#### **How to Use This Handbook**

The goal of this handbook is to aid medical students with a wide background of orthopaedic interest and experience. Whether you are a third-year student on your 2-week surgical subspecialty, a fourth year on your 4-week Advanced Clinical Elective (ACE), or a visiting student, this “book” has information that is pertinent to your success during your time with UVA Orthopaedic Surgery. Some of the information is specific to UVA, but general principles and fundamental practices can be applied to other programs or fields of medicine. Orthopaedic Surgery is a field with unique conditions and treatments that you will not see often on other rotations, so the first days can be disorienting. From navigating the hospital to finding the right books for an upcoming surgery, the following pages are here to make your rotation as smooth and as rewarding as possible. By knowing what to study and how to help out, you’re far more likely to impress the right people! We hope you enjoy your time with us!

#### **About the Authors**

In collaboration with current residents and faculty, this booklet has been refined to reflect the most up-to-date experiences and information available. A special thank you to Christopher Cosgrove, Jack Renahan, Justin Griffin and Anjan Kaushik, who were the coauthors of the original Student Handbook. Additionally, thank you Dan Hess and Jourdan Cancienne for the continued updates and input as well as Alyssa Althoff and Jeffrey Ruland ( both of whom you will hopefully meet on your rotation). Years of preparation, effort, and dedication have allowed us arrive at the most current version.

I will be your initial resident contact as you get settled in Charlottesville, so please feel free to reach out with questions. We hope that your time with us is educational and fun, we look forward to working with you!

Vaib Tadeipalli

## **II. University of Virginia Orthopaedic Surgery Program Information**

### **Residents Welcome Message**

We would like to welcome you to your rotation at the University of Virginia and thank you for electing to spend time with us. Here at UVA, we take great pride in our program and we hope you will thoroughly enjoy your time here. We are very fortunate to have an extremely well-rounded program, with outstanding research opportunities as well as excellent faculty in all specialties. During our training we cover two large Level 1 trauma centers; one university-based and one private community hospital, providing an excellent breadth of experience. Ivy Mountain Musculoskeletal Center is our outpatient orthopaedic center, complete with clinics and operating rooms, that is currently under construction and will provide a comprehensive musculoskeletal center to our patients in less than 1 year (go check this place out while you're here it's gonna be amazing). Our hospital coverage experiences, both at UVA and at Roanoke, offer tremendous graduated early operative experiences led by attending surgeons who truly enjoy teaching.

Each faculty member in the Department of Orthopaedic Surgery is devoted to one or more subspecialties. The Department of Orthopaedic Surgery is the busiest surgical service at UVA, providing considerable volume in both the inpatient and outpatient surgery settings. Research projects are constantly available in both basic and clinical arenas. Resident participation in research projects is an important component of our program. As a student, we welcome your participation in on-going research projects. Connect with a faculty member or resident to get further plugged in if a certain topic interest you.

Teaching is integrated into everything we do, and it is our hope that this is evident in your time with us. Drs. Chhabra, Gwathmey, Bachmann and the rest of the faculty have devoted a significant amount of time to cultivating the culture and academic curriculum that you will see this month. It was once said that the medical student is the only person in the room besides the patient paying to be there. We hope you take ownership of your own education, and we will do our part to support you as well. Faculty members supervise resident clinical work, and each resident gains experience in managing orthopaedic patients in the OR, clinic, as well as in the classroom. Our faculty have developed an excellent curriculum that covers all areas of training and prepares us well not only for clinical practice, but also for our annual Orthopaedic In-Training Examination (~90<sup>th</sup> percentile program performance 2020!) and the orthopaedic boards. Each year, in addition to our rigorous didactic schedule, we have an excellent review of orthopaedics by our faculty in all subspecialties, including faculty responsible for the Miller Board Review Course attended nationally by thousands of residents. Our residents routinely obtain the nation's top fellowships in varied specialties and go on to excel in both academic and private practice.

UVA receives well over 700 applications each year for the Residency Training Program. From this group, applicants are selected to interview for the five 5-year positions approved by the by the ACGME based on many different factors. Residents are selected not solely on academic merit

but most importantly on personality fit with the residents and faculty.

While you are here, we hope you take the opportunity to experience Charlottesville's captivating blend of live music, vineyards, hiking, history, distinctive Jeffersonian architecture, Southern hospitality and more. Charlottesville is often rated one of the country's best places to live and visit and is a phenomenal community in which to spend five years. Most of all, we hope you experience the high level of camaraderie present amongst our residents during your time with us. Despite spending a great deal of time at work, we hang out together often outside of the hospital. Whether it is as simple as going out for burgers after work to bigger events such as road trips, concerts on the mall, sporting events or holiday parties, we truly enjoy spending time with one another.

Once again, welcome to the University of Virginia. Do not hesitate to call or page us with any questions or concerns during your time here. And take us up on this! It was not long ago that we were in your shoes and we certainly recall what it was like to go through the application process. You will be our colleagues and our legacy, just as classes behind you will be yours. We are dedicated to finding the men and women who fit best within the University of Virginia family.

Sincerely,

The Residents

## Chiefs




Ian Backlund



James Burgess



Zach Burnett



Tim Lancaster



David Noble



Cara Thorne

## PGY-4s



Alyssa Althoff



Neil Blanchard



Pearson Gean



Thomas Moran

## PGY-3



Monica Arney



Richard Campbell



Lawal Labaran



Eliza Pelrine



Jeff Ruland

## PGY-2



Pradip Ramamurti



Katie Schultz



Josh Schwartz



Vaib Tadepalli



Jesse Wang

## PGY-1



**John Burke**

Medical School: University of Virginia



**Charlie Engh**

Medical School: Rush University



**Pramod Kamalapathy**

Medical School: Boston University



**Corinne Vennitti**

Medical School: University of Virginia



**Keith Wells**

Medical School: Eastern Virginia Medical School

## General Information

### ***Rounding***

Rounding responsibilities and timing are variable and will depend highly on the service you are on. Rounding typically starts at 5:00-5:30 each morning, depending on patient load. Please check with the residents on your service prior to starting to confirm a time to round and to get an idea of their expectations (pre-rounding, note writing, dressing changes, etc).

### ***Paging***

Each resident has a pager number (PIC #). To page someone in the hospital, dial 500 and then listen to the prompts. Text paging and searching for PIC numbers is also available on almost all hospital complex computer stations and is an effective method for communication.

### ***Parking***

Unfortunately parking is typically off campus with shuttle access for medical students. There are several locations where you can park. Many students choose to park on Roosevelt Brown Boulevard next to the hospital or on Jefferson Park Avenue.

### ***Telephones***

There are three different prefixes for the telephone numbers here at UVA:

982-XXXX	(2-XXXX within hospital complex)
243-XXXX	(3-XXXX within hospital complex)
924-XXXX	(4-XXXX within hospital complex)

If you need to dial outside the hospital to a local 7-digit number, dial 9 first. Please ask your

resident for assistance.

***Housing***

Visiting medical students often secure housing thru online forums, such as [rotatingrooms.com](http://rotatingrooms.com) or current residents' homes. If you are having difficulty finding housing, let us know. We can likely help point you in the right direction!



## Academics

### Conference Schedule

Mondays	06:15-07:15	<p>Fracture Conference – 15-minute didactic case-based presentation on specific fractures [with review articles and learning objectives sent out the Friday before] followed by review of all treated fracture cases from the prior week.</p> <p><b>Location:</b> Moss Amphitheater. 1st floor of main hospital within Radiology department. In hallway located next to patient West Elevators. Arrive no later than 6:10am. Students typically sit on the back left side of the room. Residents on the right.</p>
Tuesdays	06:15-07:15	<p>Core Curriculum “Subspecialty” conference with OITE subject review.</p> <p><b>Location:</b> OR Classroom A in Peri-Operative Suite. On 2nd floor, follow directions to Main OR front desk. Hallway is on your right, room is on right side of Perioperative suite, second door on the left.</p>
Wednesdays	07:00-09:00	<p>Grand Rounds with Visiting Professor or Department Faculty or Fellow presentations. Quality Assurance (Morbidity and Mortality) first week of each month.</p> <p><b>Location:</b> Fontaine Research Park, 3rd floor conference room. 400 Ray C. Hunt Drive. 1st building on right when entering Fontaine Park. Note: it is generally best to get a ride with a resident, as you will need their ID badge to gain access to the building and conference room at that hour.</p>
Thursdays	06:30-07:30	<p>Service-Specific Conference</p> <p><b>Location:</b> Variable. Discuss with your resident prior to conference. Student may be expected to present research articles or give brief presentations at this meeting during the second week of their rotation.</p>
Fridays	06:30-07:30	<p>Basic Science/Anatomy/Radiology/Fracture Templating (didactic/dissection)</p> <p><b>Location:</b> 6 North Classroom. Door is across the hallway from the back of the 6 Central main nursing station.</p>
Journal Club	18:00-20:00	<p>One Thursday every month at the home of an attending (Time, location, directions to be sent prior to event)</p>

### Fracture Conference (Moss Amphitheater, 1<sup>st</sup> floor main hospital)

Over the course of each academic year, we attempt to cover all major topics relating to adult and pediatric fractures. Assigned residents will lead a case based didactic lecture on the scheduled topic. Following the lecture, the previous week's fractures are presented and discussed. It is expected that the junior residents will have read the assigned topic in Rockwood and Greene's (reading assignments are on the conference schedule).

### Core Curriculum Conference (OR Classroom)

The subspecialty conference provides excellent coverage of all orthopaedic subspecialties. Presentations are given by an appropriate attending or fellow, with the format of the lecture left to the discretion of the attending (case review, slide presentation, article review, etc). Assigned readings and articles are provided to the residents one week in advance to reinforce the presented materials. OITE questions are often integrated following the lecture. The subspecialty conference is divided by anatomic block, and topics are covered on a 2-year schedule to include all specialties.

### Grand Rounds (Fontaine)

Wednesday morning is an institution-wide dedicated conference time; surgical cases and clinics start at 9:30 AM Wednesdays. The Wednesday Orthopaedic conference schedule is divided into two lectures.

Grand Rounds conferences are held two times per month. Throughout the year, the department also hosts several visiting lecturers during the Grand Rounds schedule. These are invited speakers from within the University community, as well as prominent National and International speakers. Our department does an excellent job hosting speakers with an interactive visit often associated with a dinner. Many of these presenters are funded by industry, and some are invited by the senior residents and paid for with departmental funds.

### Quality Assurance Conference (M&M)

During this conference, held the first Wednesday of every month, residents present complications of educational value to the faculty and residents. Complications are documented for departmental Continuous Quality Improvement, including the nature of the complication, the root cause, contributing factors, and strategies for future prevention. Complications are supplemented with an appropriate, relevant article from the literature. Chief or Senior residents are required to submit a report for each service including the number of surgical procedures, number of admissions, and the number of complications for the previous month.

### Service-Specific Conference

Each service holds an informal rotating schedule of 10-20 topics for these meetings. 4<sup>th</sup> year and visiting students often use this time to present. Residents, fellows, and medical students assigned to each service participate. The Senior Resident or an attending on service will pick the topic for the week and will provide reading assignments if applicable. These meetings may take the format of interesting case discussions pertinent to the clinical or operative schedule of the week, review of classic articles, review of service-specific OITE questions, or interactive didactic presentations by one of the attendings on service. The result is a core of essential topics that are covered on a yearly basis in a small group, interactive format.

## Journal Club

One of the senior residents selects articles from the current edition of JBJS and other high impact orthopaedic journals for discussion each month at the home of one of the orthopaedic attendings. The Ethics features in JBJS and AMA's Virtual Mentor are discussed bi-monthly as part of the ethics curriculum. Approximately two hours per month are devoted to journal club. Generally, all rotating 4<sup>th</sup> year medical students present an article at Journal Club in conjunction with one of the junior residents. Please discuss this with the residents on your rotation. The presentations are typically concise reviews of the article as well as a discussion of the pros, cons and implications of the article.

## Basic Science, Anatomy & Templating Conference

A weekly conference offers comprehensive coverage of Orthopaedic Basic Science and Applied Surgical Anatomy over the course of each academic year. Attending physicians with appropriate subspecialty interest are designated to participate in each weekly conference. Templating is taught for trauma applications, with active demonstrations using PACS software and TraumaCad. Basic science topics are covered twice monthly, one session is devoted to didactic anatomy presentations or radiology correlates presented by the musculoskeletal radiologists. The final session monthly is devoted to a cadaveric prosection to review the important anatomical material for the particular body region. Attending physicians are assigned to the sessions with which they have the most expertise.

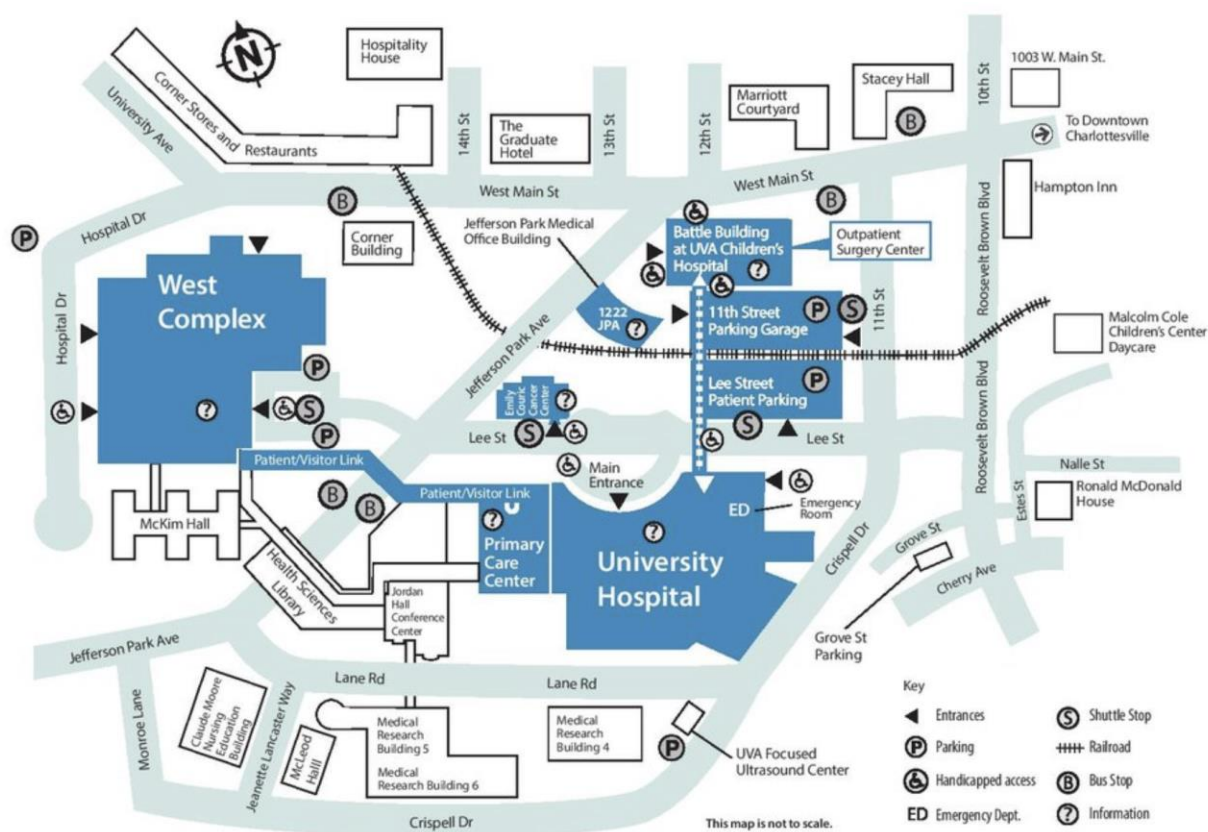
## OITE Review Sessions

Prior to the OITE, two of the month's conferences are devoted to musculoskeletal oncology review, with several other review sessions performed and given by faculty and chiefs, many of whom also train residents throughout the country in the Miller Board Review Course and AAOS review courses.

## Visiting Professorship

A formal visiting professorship is sponsored each year in conjunction with the graduation banquet for the senior residents. Other visiting professors as mentioned above come throughout the year. The Chief Residents choose a speaker for a one-day lectureship, culminating in the Resident and Fellow graduation ceremonies in early June. The visiting professor generally gives two to three hours of didactic lectures, interspersed by two to three hours of case and research presentations by the chief residents. Each Chief is required to make a 15-20 minute presentation of research they have performed during residency, suitable for publication but not necessarily submitted. The end of year banquet and awards ceremony is traditionally held at the Rotunda, a central campus structure designed by Thomas Jefferson, where all doctorates have been granted since the University's founding in 1825.

## UVA Health System Map



## **PART 2: WORK ENVIRONMENTS**

### **The Operating Room**

One of the keys to a successful day in the OR as a student is in your preparation the night before. When possible, try to find out ahead of time what procedures will be performed, where, and when. You may look this up on Epic the day before, searching by the attending name on the OR status board. If you are unable to log-on, two resources are invaluable for this: your resident and the OR front desk. If the resident is unable to forward you a copy of the following day's surgical schedule, the OR front desk will generally have it posted on the wall by the end of the day. You may find it helpful to write down the MRN of the patient and look up their chart before leaving the hospital (or at home if you have remote EPIC access). The chart may be useful to understand their specific indications for surgery, what other conservative modalities may have been attempted so far, and, depending on the level of detail in the note, why one operative approach is advantageous over another. This is an excellent opportunity to get into the mindset of a surgeon to categorize which patients need what operation and why.

### **Scrubs and the Locker Room**

Your surgical day starts by donning the appropriate attire. The grey surgical scrubs are available in a room outside the locker room. If you follow signs to the Emergency Department, you will find a set of elevators on your left prior to entering the double doors to the ED. Take the elevator up to 2M, turn left, and thru the double doors you will find the locker rooms and OR lounge. Use your ID badge to gain access into the locker room itself. Immediately through that door you will find a row of shelves with Personal Protective Equipment (PPE – surgical hats, shoe covers, etc). It may be helpful to grab a few pairs of shoe covers to keep in the OR room, should you be doing multiple cases in the same room that day. Change shoe covers between cases. Never wear any PPE, including surgical caps, in public areas such as the cafeteria.

Important: Grey scrubs are NOT, under ANY circumstances, to be worn outside. Dr. Chhabra strictly enforces this policy, so do not take any shortcuts! After changing into your scrubs, you can either try to find a spare locker, or store your non-valuable belongings elsewhere for the day (locker room bench, 6 East workroom).

In the Outpatient Surgery Center, the locker rooms are located on the left through the double doors directly across from the staff dining lounge. The scrub machine is in a small room in the same hallway two doors down from the entrance to the men's locker room. Again, locker space is at a premium, so be careful about bringing laptops or other expensive items in with you.

## **Surgical Admissions Suite (SAS)**

Located in the main hospital, adjacent to the Post-Anesthesia Care Unit (PACU), this is the area where you can find your patients while they are waiting to go back to the OR. On the right hand side of the front desk is the most updated OR scheduling sheet. The wall directly in front has a white board with names of all of the patients who are currently in PACU and their room locations. Find your patient, introduce yourself as a member of the team, and see what questions they may have about their procedure. Do NOT answer any questions to which you are unsure of the answer. You should always defer complex technical questions or sensitive issues for the resident or attending to answer, as miscommunication and confusion can lead to patient dissatisfaction and surgical delays.

## **Operating Room**

Always wear PPE (including a mask) into the OR when a case is about to get underway. Before the patient comes back and the scrub techs are setting up is a great time to introduce yourself to the people in the room. Find the small white board with team member names and write your name legibly at the bottom next to (MS3/4). At this time, it is good form to ask if you can pull your gloves and gown, if needed. Do not automatically expect circulating nurses to pull your gloves; this will get you into their black books.

Helping with setup can be difficult when first coming on service. Each attending may do it a little differently than the next, and different procedures require different types of sterile setups. When in doubt, steer clear and observe how things are done, so that you can be of assistance for the next case. Pay close attention, because patient positioning and setup are essential to completing a procedure efficiently.

As a student, it is often difficult to achieve a meaningful level of involvement during a surgical case, or accomplish technically challenging tasks, that are “impressive” to anyone. The simple tasks that you have to do, however, you must do your best. That will be more appreciated by your attendings and residents than your ability to drill in a perfectly directed cortical screw. Your responsibilities generally include: retracting, suctioning, cutting suture and closing. Whenever a surgeon takes a rongeur in hand, request a lap from the scrub nurse so that you can collect the debris. Anytime a Bovie electrocautery is on, suck the smoke (which is potentially carcinogenic) from the wound. Whenever sutures are flying, always have scissors ready in hand.

Your job as a student is to make sure the surgeons can do their job by maintaining a perfect operating field. Adjust the lighting if it needs it, if you see a “bleeder” during an approach, point it out to the surgeons and hand them the Bovie cautery. If suture needles enter the field, it should become automatic to ask the scrub tech for the suture scissors. Even if the surgeon doesn’t need a cut, it will look good that you are paying attention and are anticipating moves. Always stay clear of sharp instruments in order to avoid needle sticks or lacerations. Do not reach on the scrub tech’s mayo stand without asking. You are a guest in the OR, so if you’re unsure, just ask.

Aim to know the appropriate suturing techniques, and practice these at home on banana peels, chicken skin, or pig feet. Wounds may be closed using staples, horizontal mattress sutures, vertical mattress sutures, figure of eight sutures, simple interrupted ties, or a combination of these. These can be buried or unburied; know the difference. Place the correct sutures when you are given the needle to work, and clarify with the resident if you are unsure. The classic orthopaedic deep and subcutaneous suture is a vertical buried stitch (deep to superficial on the side away from you, superficial to deep on the side closest to you). This is often your only chance to show that your hands are good for more than just retracting. There are multiple good YouTube videos available that demonstrate these techniques. Again, if you are not sure, ask your resident when you are closing to make sure the wound is closed correctly. Soft tissue closure and care is important in all orthopaedic cases. Make an effort to avoid grabbing the skin with your pick-ups, as these superficial perforations can lead to wound healing difficulties long-term.

After the case is closed, help with transferring the patient over to PACU. Again, less is more, so unless you are confident you know what you are doing when transferring the patient from the operative table, the best bet initially is to observe and ask before doing. Avoid pulling out IV or arterial lines, causing skin abrasions, or, worst of all, pulling out surgical drains. Before leaving the OR, it may be helpful to ask the resident if they would like you to write the Brief Operative Note. Every patient has to have this note in the Epic chart prior to leaving the OR. Even if you do not write it yourself, you can help by asking Anesthesia what the patient got for fluids and the reported EBL and tourniquet time. These values always go into the brief op note, and you will look like a rockstar if you already know those numbers if/when your resident asks you to find them out. Always volunteer to drive the patient bed out of the OR to the PACU. When entering PACU, a large TV screen will be ahead on your left indicating which OR is going to which PACU area (eg "15-->7").

Remember to do a Post-Op Check on all patients on which you have operated. Follow up on post-operative radiographs and review them with your resident. Ask your resident if you can write the post-op note in the Epic chart.

## **Suturing**

*You must be proficient in suturing.* While hand tying is paramount to general surgery, orthopaedic suturing focuses primarily on instrument tying. For closing skin, you will use less material and close faster using instruments for your simple and mattress type sutures. As a student, your primary role will be closing skin with nylon sutures. Like any skill, you must practice, practice, practice!

### Tips for practicing

Supplies are widely available in any OR or clinic. Sutures and blue towels will be easy to find in the OR while disposable pickups and needle drivers will be found easiest in clinic or the hospital floor supply room. Do not ever take instruments from OR surgical pans, as exact instrument counts are always done pre- and post-procedure in the sterile supply rooms. Suturing two folds of a blue

towel is a good way to work on closing with nylons. If you want to practice with actual tissue, you can usually pick up a pig's foot at a local grocery store on the cheap. Practice until the motions are automatic! Of course, practice hand ties as well just in case you get thrown a curveball. If you want to learn a varsity skill, practice suturing around a rubber tube to simulate securing a surgical drain. \*Video for surgical drain --There are endless variations on this, but the air knot and loops around the drain are important.

-Granny slip knots are ideal for starting a knot on the drain each loop around.

### Tips for suturing skin

Hold needle  $\frac{1}{2}$  -  $\frac{2}{3}$  down needle, not at the end.

Carefully manipulate skin with pickups and avoid damaging skin with instruments.

Minimize the number of times you have to touch the skin with pickups and the needle.

Pierce skin with needle tip perpendicular to skin.

Maintain consistent intervals between sutures, depth, and distance to wound edge.

Do not strangle tissue with overly tight knots: approximate!

With nylon sutures, 4 throws is usually adequate but it doesn't hurt to add more if there is time.

Hand back a needle with the point clamped and protected within the needle driver or positioned backward along the driver.

Recommended articles on sutures and suturing technique (available through UVA):

Hochberg J. *et al.* 2009. Suture Choice and Other Methods of Skin Closure. *Surg Clin N Amer.* 89(3), 627-641. PMID: 19465201

Kudur MH. *et al.* 2009. Sutures and Suturing Techniques in Skin Closure. *Indian J Dermatol Venereol Leprol.* 75(4), 425-434. PMID: 19584482

### **Other General Tips**

- As soon as you go into the OR room, introduce yourself as a student and write your name on the whiteboard so they can enter you into the note.
- Be kind and respectful to ALL OR STAFF. The orthopaedic faculty members have good relationships with the staff and take their opinions seriously (they will ask). Some students have fallen on their own sword this way, but many students have also made a good impression!
- If the patient's latest imaging is not already up on PACS when you enter the OR, do so and scroll to the area of pathology. Read up on the patient's pertinent medical history well before the case and know every patient in detail. This shows preparedness in the OR and will often get you a chance to do some operative steps if a resident feels you are ready.
- When prepping the patient, if the operating field is hairy, it is always a safe bet to track down the electric shaver, blades, and 2" tape for collecting loose hairs.
- If the procedure requires a fluoroscopic "C-arm" for X-rays, make sure an appropriate amount of protective lead is in the room. The central supply area is a good place to look if you need more. Try to grab the generic "OR" lead pieces when possible. Avoid grabbing lead that is personally embroidered, so someone does not barge in trying to look for it later.



- Get your “first scrub” finished at the sink before your first patient gets to the OR if possible. After this, you are clear to use Avagard for the remainder of the day’s cases. Whenever you eat or drink something between cases, you have to re-scrub at the sink.
- Be as observant as possible as to how the patient is prepped and draped. Once you get a sense for the routine (if there is one), jump in and help in any way possible. It is better to be told to stay back than to be reproached for standing around, so try to be involved. One trick is to always have something in your hand that you think they will need at some point.

## **The Floor**

The Orthopaedic floor responsibilities vary greatly from service to service. You will find the specifics for each service in the following chapters. Beyond that, common sense is the name of the game. Email your residents before your first day regarding basic information like rounding times, and what things you can do or gather before rounding begins. Arrive 15 minutes before you’re told to be there, gather the supplies that will be needed, and use any spare time to read up on some of the patients. Some services are somewhat cookie-cutter while others have a broad spectrum of patients. If you were present during a patient’s procedure, follow the patient each morning and try to stop by their room before leaving each day. You’ll learn more, be more satisfied with each day’s work, and help foster a better patient care atmosphere. Being a patient in a hospital is very boring and you can really make a difference! If you do your part, patients will advocate for you and tell your attending and residents all about you - perhaps the best evaluation a student can get. Finally, if a resident tells you to go home at the end of the day, this is not a trick. Ask what time to meet them in the morning, and then feel free to leave the hospital.

## **The Emergency Department**

The ED serves as a major source of patients with orthopaedic trauma, various musculoskeletal complaints, and emergencies. You will spend a lot of time in the ED while on call. Although the emergency room environment can be chaotic and frustrating, you will see a wide variety of conditions and have several opportunities to help out. Orthopaedic consults are particularly satisfying because you and your team will be able to provide definitive treatment for many patients. From reducing and splinting a fractured limb to aspirating a septic joint, there is a great deal of direct intervention that will leave the patient better off than when he or she arrived. In addition, every patient is an excellent source for practicing a physical exam and interpreting X-rays. Surgical emergencies nearly always come through the ED first. You will witness and assist in the decision-making of whether or not to send patients to the OR. There are few services in a hospital that rival the amount of “doing” that is in an orthopaedic ED consult service.

How do I even get to the UVA ED?

If you are asked to see the patient first, take the East Staff elevators down to the 1st floor. There are multiple ways to get to the ED, but if you are in the call suite, you can use the 6 east elevators. When exiting the elevator take a right and then an immediate left. You will see a sign to the “old ED”, take a right thru the wooden door which will lead you thru radiology. Once you get to the end of that hallway, you will start to see signs to the “new ED”. Finding the patient may be confusing if you are not accustomed to the room numbering system. Do not hesitate to ask a nurse for directions to the appropriate room. When you enter the ED, you will see 4 trauma bays in front of you. Down the long hallway to the left, room numbers are listed by pod. 500’s will be first, then 400’s, 300’s, etc. 600’s on your left is the pediatric ED and 100’s is the rapid medial evaluation pod that typically serves as an “urgent care” for individual who do not require resuscitation but would like to be seen.

How can you help as a student?

When a patient with a fracture or musculoskeletal issue comes through the ED, the on-call resident will be notified via text page. Usually by then, radiographs of the affected extremity have been obtained. When reviewing the films, it is a good practice to try to visualize the mechanism of injury, understand the forces that may have contributed to that fracture pattern, and attempt to classify the fracture if possible. These exercises help solidify important terminology and concepts in Orthopaedics. For a quick reference, the trauma section in [Orthobullets.com](http://Orthobullets.com) or the [Handbook of Fractures](#) can be very helpful.

When approaching a patient with a fracture, it is important to:

- Get a concise history, especially relating to the mechanism of injury.
- Assess level of pain, and evaluate other areas of injury.
- Ascertain what time the patient last ate or drank, past medical and social history, allergies, medications, and social history (occupation, tobacco and alcohol use).
- Carefully examine whether the fracture is open or closed, evaluate associated abrasions, ecchymoses, lacerations, etc.
- Assess sensation in relevant nerve distributions and vascular status. If these systems are fully functioning, the patient is deemed to be “NVI” or “NeuroVascularly Intact”).
- Assess motor function can be difficult, as the patient is often limited due to pain.
- Assess for signs of limb compartment syndrome.
- Do a secondary limb survey after the patient has been resuscitated and stabilized, to rule out other limb injuries.

If possible, begin to assemble any equipment that may be necessary before the resident joins you in the patient’s room. Commonly, orange “ortho carts” will be placed at the door of the patient’s room (passcode is 2231), so start gathering splint material in a yellow bucket from this cart. Examples of materials that may be needed include splinting materials, laceration tray and irrigation supplies,

joint aspiration materials, mini c arm, and IV poles and weights are frequently needed, depending on the injury. You can also offer to begin the consult note in Epic while the resident is interviewing the patient, or get consent forms with patient labels attached (surgical and blood consent) if surgery is indicated.

Often, the single most important factor that differentiates an exceptional medical student from an average student is the **ability to anticipate** what the orthopaedic resident will need. Obviously this comes with cumulative experience and exposure to consultations with the residents in the ED, but a sharp medical student should always try to predict the next step in the treatment plan. This anticipation, combined with a positive “will-do” attitude and congenial personality, will help a student serve well as a member of the orthopaedic team.

## **Closed Reduction and Immobilization**

### **Splint or Cast?**

- Splints are good acute immobilization tools as they are non-circumferential and allow for swelling in the immediate phase after a fracture or sprain. Casts are circumferential and are typically not appropriate in the early stage (high risk of compartment syndrome). They may be used later on after swelling has subsided, as a more stable construct for definitive management of certain fracture types. Occasionally casts are used in acute fractures in pediatric patients; however, these will be bi-valved with a cast saw to allow for soft tissue swelling.

Fractures are commonly reduced by applying axial traction and reversal of the mechanism of injury. It is important to have appropriate analgesia and muscle relaxation prior to attempting this maneuver. Keep in mind, however, that in-line traction is not always the best maneuver and can sometimes actually make a reduction more difficult. Try to pay attention to special techniques from the senior or chief residents when alternative reduction methods are utilized.

For upper extremity fractures, using finger traps attached with countertraction arm weights can be useful to allow for muscle relaxation and ligamentotaxis. For maximal efficiency, the finger traps can be applied while the team is setting up other components in preparation for splinting, as a few minutes of traction are necessary for the desired effect. Adequate soft tissue protection is essential, and all bony prominences must be well padded with webril. This also allows for post-injury swelling. After the reduction maneuver and application of the plaster, 3 points of contact are necessary to stabilize the reduction, with immobilization above and below the fracture site.

## **Materials for Fracture Splinting**

The UVA ED supply room is accessible only with an ID badge belonging to the ED staff or orthopaedic residents. When the resident is not with you, you can ask an ED nurse or staff member to let you into the orthopaedic supply room. The supply room is at the beginning of the ED hallway on your right by the service elevators. It is an unnamed door, so don't be afraid to ask. In the supply

room, you will need to collect the following:

- 1 or 2 square yellow buckets.
- 3", 4", or 5" rolls of plaster. These come in white or silver cylindrical packages. In general, forearm fractures will require smaller rolls, and upper arm and leg splints will require larger rolls. It is recommended that you grab 4 to 6 rolls, depending on the fracture type and splint to be applied.
- 3"-5" Webril. Again, use your judgment, but you can never have enough Webril. 8 to 10 rolls is not a bad place to start. Always remember to return unused supplies.
- 3", 4", or 5" ACE bandages, as needed depending on splint type and size.

Take your materials to the patient's room, use one of the yellow bucks to fill one-fourth full with room temperature (not hot) water and set aside. Setting plaster releases enough heat to add 20-30 degrees to the original temperature and can blister the patient's skin if the temperature is not monitored appropriately. Water temperature is a balance between too hot (sets plaster quickly but burns patient) and too cold (sets plaster slowly but is safer for the skin). Generally, cool water is better than warm water, but ask your resident if you are unsure.

- Finger traps and weights: If the patient's fracture involves an area distal to the elbow, you may need to use finger traps. This device is critical in allowing the muscles of the forearm to relax with applied traction and aid in reduction. If needed, these are located behind a door in the ED "express care" area. Again, from the double door entry into the ED, continue straight past the workstations on your right, walk down the hall and enter the first door on your right. Behind that door is a "fracture cart" with additional supplies. Grab the pole with the finger traps, as well as a 10lb weight and 5 feet worth of wide stockinette. Also make sure that there is medical tape or Kerlix available in the room. This is used to pad the fingers before the finger traps are applied.

## Open Fractures

Open fractures are orthopaedic emergencies. The most important treatment is timely administration of antibiotics (see below). Once antibiotics, Tetanus immunization, and pain medicines are given, fracture management can continue. In the ED, you will often need to gently irrigate, remove gross contamination, and cover the wound with a sterile dressing (saline soaked gauze), as well as splint the fracture to stabilize the extremity until surgery. Irrigation is performed preferably with normal saline, but sometimes a dilute solution of betadine is appropriate. Operative debridement is indicated at least once for most open fractures and should be performed as soon as the patient is stabilized and an operating room with appropriate staff is available. Although the sooner a wound is washed out the better, it is not absolutely necessary to operate within the traditional 6 hour threshold.

Patients should be started immediately on antibiotics according to energy of fracture and degree of contamination. Tetanus prophylaxis is also required.

- Gustilo Grade I (lower energy): 1st gen cephalosporin IV (ex. Ancef).

- Gustilo Grade II / III (higher energy): 1st gen cephalosporin + aminoglycoside (ex. Gentamicin).
- Penicillin is added if there is concern for anaerobic infection (ex. farm injury).
- Clindamycin can substitute for cephalosporins in Penicillin-allergic patients.

Recommended Material from ED supply room (in addition to splinting materials):

- Yellow bucket
- 2 bottles of 1L normal saline
- Bottle of betadine
- 2 large chucks
- 3 or 4 4x4 gauze packets
- Xeroform gauze packet
- Laceration / procedure tray if suturing procedure required
- Sterile blue towel 4-pack if suturing procedure is to be done

To prepare, lay down the chucks in an appropriate area to catch as much of the runoff fluid as possible. It is poor form to make a big mess in an ED room after a washout, so be sure to help the resident keep things as clean as possible. If betadine is to be used, open the lid of one of the bottles of normal saline and pour enough in the bottle to make it look like the color of iced tea. With a pointed sharp object (large bore needle, scissors, etc) carefully poke a few holes in the top of the saline bottles. This will be used to wash the wound out under pressure from squeezing the bottle.

## Multitrauma Patients

The majority of multitrauma patients have musculoskeletal injuries requiring orthopaedic consultation upon presentation to the ED. The General Surgery Trauma team is responsible for the overall management of the patient in the acute setting, so coordinate your efforts under their direction. Splenic ruptures, liver lacerations, perforated bowels, pneumothoraces, rib fractures, and closed head injuries are common. Orthopaedic trauma is often prioritized after general trauma can resuscitate and hemodynamically stabilize the patient. However, in cases of “Orthopaedic Emergencies” such as open fractures, compartment syndrome, and significant neurovascular injuries or dislocations, rapid action is necessary. At the very least, unstable fractures and joint dislocations should be reduced and splinted, and open fractures be irrigated and covered before they go to the OR with General Surgery.

The Secondary Limb Survey:

It is easy to miss less obvious limb injuries when everyone is focused on the most prominent injury, and this is where the orthopaedic consultant plays an important role for more thorough examination.

1. A member of your team must perform a rectal exam!
2. Check **every** joint for tenderness, deformity, and laxity. As high as 20% of multitrauma patients have injuries that are missed after the initial evaluation because of altered mental status or other conditions that preclude a thorough exam.
3. Check **every** long bone for crepitus, deformity, ecchymosis, and other signs of fracture.

4. Inspect and palpate the cervical, thoracic, and lumbar spines (conscious or not) during logroll while maintaining strict spine precautions and C-collar immobilization.
5. Check proximal and distal pulses and check all major sensory and motor nerves.

\* After your initial evaluation, make an effort to reduce and splint all known fractures before the patient is sent to Radiology for further imaging or the General Surgery OR. It could be hours before you get another chance. An ankle fracture will not be #1 priority if the patient has a ruptured spleen, so it is important to stabilize extremity injuries before they get draped and forgotten.

### Useful Resources

<http://www.med.uottawa.ca/procedures/cast/> - link to University of Ottawa website demonstrating videos for multiple types of splint applications.

<http://www.aafp.org/afp/2009/0901/p491.html> - link to the AAFP website. Useful for an overview of splint types and indications.

<http://www.orthobullets.com> - great for use as a quick reference that highlights the main points you will need to know when dealing with common orthopaedic injuries.

<http://www.wheelessonline.com> - another popular quick reference website.

<https://www2.aofoundation.org/wps/portal/surgery> - an excellent source for orthopaedic trauma. You can download an app for your mobile device as well!

Video Link: [Fracture Management - Dr. Syed Junaid](#)

### Excellent Review Articles on Orthopaedic Emergencies:

- 1) Timing of fracture fixation in multitrauma patients: the role of early total care and damage control surgery. Pape et al. JAAOS 2009; 17: 541-549.
- 2) Open tibial shaft fractures: Evaluation and initial wound management. Melvin et al. JAAOS 2010; 18: 10-19.
- 3) The urgency of surgical debridement in the management of open fractures. Werner et al. JAAOS 2008; 16: 369-375.
- 4) Hip dislocation: evaluation and management. Foulk & Mullis. JAAOS 2010; 18; 199-209.
- 5) External fixation: how to make it work. Ziran et al. JBJS. 2007; 89-A, 1620-32.
- 6) Acute compartment syndrome in lower extremity musculoskeletal trauma. Olson & Glasgow. JAAOS 2005; 13: 436-444.

7) Perioperative medical comorbidities in the orthopaedic patient. Bushnell et al. JAAOS 2008; 16: 216-227.

8) Cast and splint immobilization: complications. Halanski and Noonan. JAAOS 2008; 16: 30-40.

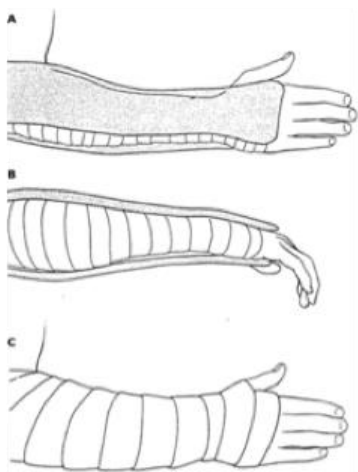
9) Adult trauma: getting through the night. Schmidt et al. JBJS 2010; 92: 490-505.

10) Pediatric trauma: getting through the night. Scherl et al. J Bone Joint Surg Am. 2010 Mar;92(3):756-64.

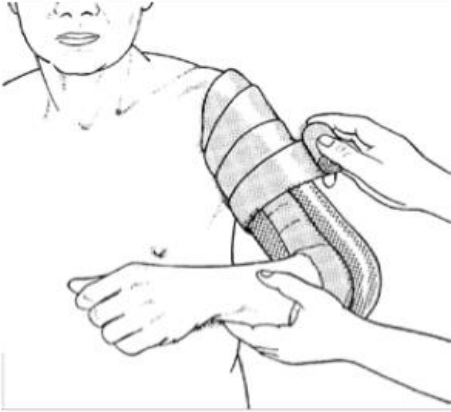11) Surgical timing in treating injured extremities. Crist BD et al. JBJS Am. 94(16):1514-1524.

### Common Upper Extremity Splints

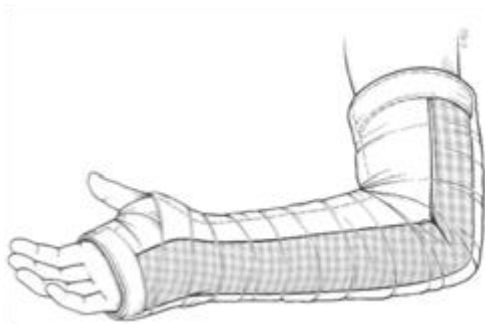
- Sugar Tong Splint - useful for distal and mid-forearm fractures. "U" shaped slab travels from proximal palmar crease, around the elbow, to the dorsal hand proximal to the MCP joints.  
<http://emedicine.medscape.com/article/80127-overview#a01>



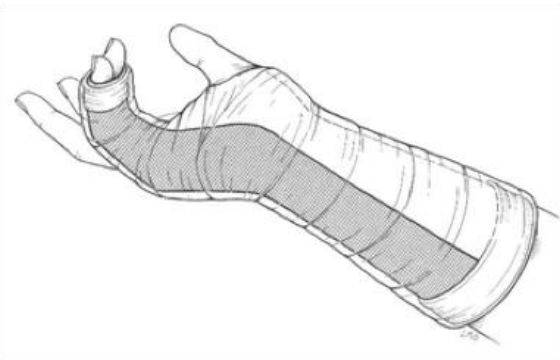
- Coaptation Splint - useful for humeral shaft fractures. "U" shaped slab travels from medial upper arm, around elbow, to lateral arm over the superior aspect of the shoulder.



- Posterior Long Arm Elbow Splint - <http://emedicine.medscape.com/article/80089-overview>

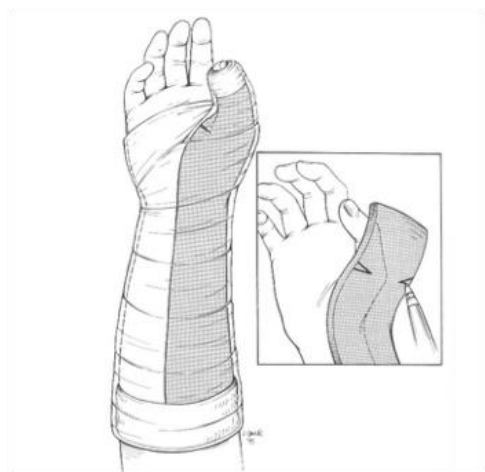

- Ulnar Gutter Splint - <http://emedicine.medscape.com/article/80165-overview>

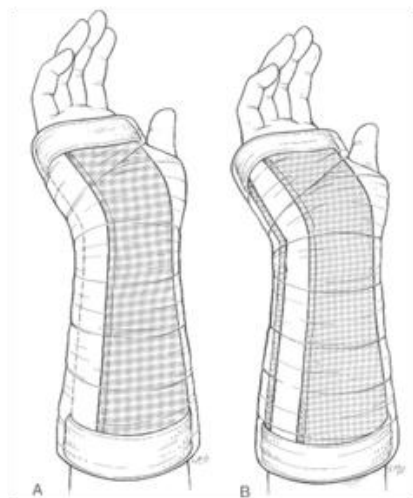

- Thumb Spica Splint - <http://emedicine.medscape.com/article/80146-overview>





- Volar or Dorsal Short Arm Splint - <http://emedicine.medscape.com/article/1997886-overview>



### Common Lower Extremity Splints

- Short Leg "Cadillac" Splint - utilizes a posterior slab running from the level of the proximal tibia down to the toebox, as well as a single "U" shaped slab applied around the medial and lateral malleoli. Care must be taken to avoid the proximal end of the posterior slab from digging into the patient's popliteal fossa. In general, this splint is good for fractures below the tibial plafond.
- Long Leg Splint - same concept as the Cadillac splint, except the posterior slab extends up to the mid-thigh. This is good for fractures above the level of the tibial plafond, where restriction of knee motion and tibial rotation is necessary for fracture stabilization. The splint is commonly applied with the knee in 15 to 30 degrees of flexion.
- "Bulky Jones" Short Leg Splint - splint utilizes a posterior slab and a "U" shaped slab applied around

the medial and lateral malleoli, but there is a large amount of cotton padding added between the splint material and the skin. This is especially useful for calcaneus fractures. A Robert Jones Cotton roll is used to provide extra padding for comfort and accommodation of tissue swelling.

- “Dr. Weiss Special” Short Leg Postop Splint - similar to the Cadillac short leg splint, but plaster application is slightly different. Posterior slab is supplemented with a separate medial and lateral slabs that have the option of being placed more anteriorly as they travel on the opposite side of their origin, ending more distally in relationship to their origin.

A quick check of neurovascular status should be performed after application of the splint. Check for sensation in the distal toes or fingers, capillary refill for vascular assessment, as well as motor function by asking if the patient can wiggle their toes or fingers.

Splinting can get messy. Always remember to be courteous to your patient and the ED staff by wiping off plaster that may have dripped onto the patient or the floor.

### **Nights On Call**

It is suggested that all students try to take at least 5 calls while they are here for their 4 week rotation; preferably one Friday/Sunday combination, one Saturday, and 2 other weeknights. Friday/Sunday call includes your regular work day Friday in addition to taking overnight call into Saturday morning at which point you will be released. You will then return to work on Sunday morning until the night float resident arrives Sunday night. Saturday call entails working a 24 hour call day Saturday.

Rotating medical students are expected to take call and arrange a call schedule amongst themselves. This is often best accomplished through the use of a googledoc or spreadsheet. Call is beneficial on multiple fronts as both a learning opportunity and to increase your exposure to the residents and faculty here at UVA. The on-call experience at UVA is quite variable, depending on what comes into the ED, but you should be prepared to be busy for a large portion of the night. Weekends are generally busier than weekdays, and some weeks the orthopaedic faculty and staff are on for Hand call, Spine call, or both. Being on call is a great opportunity to get one-on-one interactions with the night float team and weekend call team, and to take on an additional level of responsibility in patient care. As a student, this translates to an increased opportunity to show your knowledge base and skill set, as well as the ability to anticipate what residents need. When you are on call, you are expected to be timely, professional, and respectful to all hospital staff and patients.

2 weekday nights:	18:00 start until rounds or conference next morning.
Saturday:	07:00 start, until 07:00 Sunday (24 hours)
Friday + Sunday:	Friday call begins at 16:00 and typically ends when rounding on Saturday morning is complete. Sunday call begins 07:00, until Monday morning.

## **Initiating Contact**

Weekday call: When your daily responsibilities on your service are complete, page 1206 to get the orthopaedic junior resident on-call. To do this, find a computer with an available phone. Open up the paging shortcut on the desktop (or, alternatively, open up Internet Explorer and click the link "Text Paging"). In the field titled pager number, type in 1206, select the Orthopaedic On Call resident and type your name, the 5 digit number of the phone you're sitting next to, and a brief message. Your text page will show up as something like "John Smith, 12345, Hello, I am the medical student on-call tonight. Where would you like me to meet you?" The night-float Junior (PGY-2) and night-float Chief (PGY-4) residents takes over the pager at 6pm. If there is not a lot of activity, the day-call resident may tell you to just report to the night team at 6pm. If you are able to help the daytime call 1206 junior resident before 6pm, that will be looked upon favorably as well.

Weekend call: Unless told otherwise, you are expected show up at approximately 06:00 to 6 East and assist in any rounding responsibilities for your service team, or for any other team in need of an extra hand (for dressing changes, etc). Make sure you identify yourself as the on-call student to the residents, so that they can direct you to who is on the call team that day. The call team rounds on all of the orthopaedic patients in the hospital, divided up on the Friday before. The call team typically consists of an intern (PGY-1) who takes care of all of the floor patients/discharges during the day, a Junior resident (PGY-2) who fields floor consults (PIC 1206), a senior resident (PGY 3 or 4, PIC 1251) sees emergency room consults, and a chief (PGY 5) who staffs all consults and oversees the entire team. Weekend OR cases will likely start at 0700 in the trauma room, and you should prepare to attend cases with the chief. If cases are finished for the day or your help is not needed, ask to assist the consult residents with ED and floor consults. Weekends are typically short-staffed, so finds ways that you can help move the day forward.

## **Resident Call Rooms**

As students, your ID badges may not be given access to this area. Regardless, it is still important to know where they are located, should you have to meet your resident there. The easiest way to find the resident call suite is to take the East "staff" elevators down to the ground "G" floor. Upon exiting the elevator, there will be a wooden door straight ahead labeled "Resident on call rooms." There are usually open "Float" beds available should you have the opportunity to get some rest during your call night. There is also a small gym if you don't have a gym membership for the month or you want to work-out at the hospital. The orthopaedic call rooms are in the back left corner of the call suite. On consult days, you can usually find the call resident fielding consults from the junior orthopaedic call room.

## Tips for Managing Call

As a fourth year student doing an ACE or as a visiting medical student, you will find yourself working long shifts when it is your turn on call. This can be physically and mentally exhausting, so prepare well with adequate rest prior to a call shift.

- Eat when you can. The cafeteria grill closes at 3am!
- Stay hydrated.
- Sleep when you can.
- Empty your bladder when you can.
- Again, sleep when you can. The residents here are real people too, many of whom rotated as a student at some point. They understand how punishing these long shifts can be. If things are slow and the night resident offers you a chance to get some shuteye until something new comes in, take it. Even an hour or two can make a huge difference.

## Suggested Reading:

Egol, Kenneth, MD. Handbook of Fractures. Lippincot (Wolters Kluwer Health).

Focus on Chapter 1: "General Conditions." If you already own this book, this might be the best reference to have with you. The book is great for a quick resource for most fractures and dislocations.

Benson, Leon S, MD. Orthopaedic Pearls. 1999.

This handy little book is available for \$4 on Amazon and is great for the ED setting. Particularly useful for getting a grasp of orthopaedic note-writing.

## **Student Talks and Journal Article Presentations**

### **Student Talks**

Your ability to prepare and deliver a strong student presentation is important. While residents will have lengthy exposure to you on the service, attending surgeons often have less substance to directly evaluate you. A well-prepared, concise, and clearly delivered talk will pay large dividends for your impression on the team. As a fourth year on an ACE or a visiting student, you will give a presentation on each of the two services you work with - typically during Thursday service specific conference on your second week of the rotation. Third year students are occasionally asked to give a talk, but this is resident-dependent. Of course, if you wish to do a talk, you are welcome to request the opportunity. Here are some good tips to get you on the right path to a great presentation:

- Preparation
  - Decide on a topic within the first few days. The earlier you start researching your topic, the better. If you need some direction, ask your resident or attending. They can often steer you towards interesting topics, or steer you away from topics that other students have already covered in recent talks.
  - Pick a very specific topic. If you see an interesting case or condition on the service, try to use that to guide your topic, but don't be afraid to pick something you haven't seen before. Lastly, remember your audience! The attendings and residents in the room will quickly become bored if you present medical school-level knowledge to them. Believe it or not, you can really teach them something new! Some examples include, comparing the efficacy of established surgical procedures, or discuss evidence for a new treatment
  - Consider starting with a short "Case Presentation." This could either be from the medical records of a real patient or based off a case report you read about somewhere else. Either way, it helps bring the audience in and bring your presentation some life.
  - Focus on the relevant anatomy. This can be a short slide as you introduce your topic but it is a great chance to show off your detailed understanding of the anatomy.
  - Focus on primary literature. Your presentation should include direct references to the literature. You may even find one paper that answers your very question, in which case you can use it to guide your talk's content.
  - Learn as much as you can about your topic. This may sound obvious, but try to become an expert about what you're talking about. Your presentation should be only the tip of the iceberg of your knowledge. When you take questions at the end, you'll know your stuff!
  - When your talk is complete, practice! The time constraint is often between 5 and 10 minutes, which can be very difficult to do. Work on your timing and delivery, so you won't be stuck only having time to present part of your hard work.
- Presentation
  - Remember that slides are meant to augment and guide your talk, no more. Keep the

wording at a minimum with an emphasis on images and figures. You will show that you know your stuff by speaking without reading.

- Along the same lines, do not read off of your slides! If someone read your powerpoint by itself, he or she should not be able to get as much as if you were presenting it.
- Speak clearly and speak to the audience. Don't hide behind the podium if there is one. Stand next to the podium and be visible. You prepared well and know your stuff, so make that confidence apparent.

### Journal Articles

During your rotation, it is possible that you will be called upon to present an article from the Orthopaedic literature. This may be in the context of your service-specific morning conference, or during an evening meeting of the journal club. This is a great opportunity to show off both your Orthopaedic knowledge and your ability to process and interpret primary literature. For some students, this can be an incredibly stressful ordeal. It is crucial that you develop a standardized approach to analyzing journal articles, so that you don't waste time spinning your wheels reading information that goes in one ear and out the other. Ultimately, a haphazard approach to a paper will result in an unorganized, subpar presentation. We suggest a basic format here that will serve as a helpful starting point when reading a paper.

1. State the article title, publishing journal, and date published.
2. State the primary research question. This hypothesis is usually explicitly stated in the abstract or at the end of the "background" section.
3. The "PICO" Model is a way to answer four clinical questions.
  - P = Population. How would you describe the group of patients in this particular study? What are some of the characteristics of the patient population(s) that are most important/relevant to this study?
  - I = Intervention. What is the primary intervention being analyzed?
  - C = Control. What is the alternative to the primary intervention(s)? Is this control appropriate?
  - O = Outcome. What are the results and conclusions drawn from them? What does the author measure, accomplish or affect?
4. What is the study design? Familiarize yourself with the various levels of evidence, and the scale of study designs (ranging from case reports to randomized control studies and meta-analyses)
5. Briefly summarize important points in the methods.
6. Briefly summarize the results.
7. Interpret the author's conclusions, and your own. Summarize by answering the questions, "Is it new? Is it true? Does it change what you do?":
  - Is it new- Are the findings of the study novel, or are they supportive/disagreeing with previously published literature? Is this something that was previously unknown to the orthopaedic community?

- Is it true- Do I believe the data that the author is presenting? This is where it will be important to familiarize yourself with the existing literature on your topic. If your study, X, states that 100% of their patients had a successful outcome, and studies Y and Z report 10% success using a similar study design/intervention, would you believe the legitimacy of this data?
- Will it change what you do- Will the results and conclusions from this study change my practice? Data presented in the literature may be statistically significant, but that does not always guarantee clinical significance.

## PART 3: ORTHOPAEDIC DIVISIONS

### ADULT RECONSTRUCTION

#### Overview

The adult reconstruction division deals with the treatment and/or replacement of knee and hip joints. Reconstructive surgery serves to restore function and provide pain relief for patients with a variety of joint disorders. Degenerative joint disease (DJD) is the most common indication for both primary and revision reconstructive surgery. Other conditions include rheumatoid arthritis, lupus and gouty arthritis, post-traumatic arthritis, avascular necrosis, and congenital birth defects of the hip and knee. Once a patient has exhausted conservative measures through medications and injections, total joint arthroplasty provides long-term relief at rates exceeding 90%. Total joint arthroplasty is a surgery with emphasis on precise preoperative planning and proper installation of prosthetic devices. The difference between a good joint replacement and an excellent one could mean the difference in years of prosthetic survival time, infection, and significant functional outcome. Knee and hip joints bear significant weight-bearing stresses, and a small defect or misalignment will quickly balloon to total failure. That being said, current technology and surgical technique have allowed for highly reproducible success that provides patients with a reliably definitive treatment for their joint disease.

As a student on this service, you will have unparalleled exposure to knee and hip anatomy, including the manipulation of opened, exposed joints. You will also see and use powerful tools required to shape bone surfaces and allow for stable implantation. Proper retraction is a necessity. Because the incisions are large, students will also have ample opportunity to suture. In clinic, students will see a variety of important physical exam skills and learn to stratify various stages of joint disease through history, physical exam, and radiographic evidence. Joint surgeries carry significant risk and thus typically require at least 2-3 days in the hospital. Efficient rounding is paramount to the service and there is plenty that a student can do to help out.

#### Suggested Reading

\*Current Diagnosis and Treatment in Orthopedics Adult Reconstruction Chapter. Available as ebook on HSL website.

\*Campbell's Operative Orthopaedics Volume 1, Part II and III

Available as ebook on HSL website.

\*Pagnano, M. *et al.* (1998). Role of posterior cruciate ligament in total knee arthroplasty. *Journal of American Academy of Orthopaedic Surgeons*. Vol. 6, no. 3, 176-187.

\*Rockwood and Green's Fractures in Adults Section 1, Chapter 21 "Periprosthetic Fractures." Use this to help you understand one of the graver complications of arthroplasty.

Available as ebook on HSL website and in reserve shelf of library.

\*Search "osteoarthritis" in Essential Evidence Plus database.



### Division Structure:

		
<b>Thomas E. Brown, MD</b>	<b>Quanjun Cui, MD</b>	<b>James A. Browne, MD</b>
Associate Professor of Orthopaedic Surgery	Professor of Orthopaedic Surgery Vice Chair for Orthopaedic Research	Associate Professor of Orthopaedic Surgery Vice Chair of Clinic Operations Division Head

Nicholas Calabrese, Physician Assistant

Traci Mahoney, Physician Assistant

Chad Wilson, MPAS, PA-C, Physician Assistant

Reconstruction Fellow (2)

PGY-5 Chief Resident

PGY-2 Junior Resident

PGY-1 Intern

### Conditions Frequently Seen

1. Degenerative joint disease
2. Arthroplasty complications / failed joint prosthesis
3. Avascular necrosis
4. Total hip arthroplasty and hemiarthroplasty for hip fractures

### Degenerative Joint Disease

- Anatomy/Pathogenesis
  - Primary vs. secondary (history of trauma, infection or congenital malformations)
  - Knee is most commonly affected joint
  - Cartilage destruction with eburnation of subchondral bone, subchondral

microfractures and cyst formation in late disease

- Fissuring and breakdown of cartilage tidemark are characteristic histologic changes
- Important History Points
  - **Pain**, level of function (strength/stability/ROM), previous interventions, duration of relief provided by steroid injections
- Symptoms/Physical Exam (Hip) - verify reported pain and determine severity
  - Appearance and tenderness to palpation
  - Active/passive straight leg raise
  - Log roll (IR/ER of extended leg)
  - Abduction of hip
  - Document ROM and leg length discrepancy
- Symptoms/Physical Exam (knee) - localize pain to compartments (medial / lateral / patellofemoral)
  - Appearance and tenderness to palpation
  - Hip ROM to rule out referred pain!
  - Mediolateral/AP/varus-valgus stability and alignment
  - Look for flexion contracture (common in advanced DJD) and extensor lag (active<passive ROM)
- Radiographic Findings of DJD (aka Fairbank criteria)
  - Joint space narrowing
  - Subchondral sclerosis
  - Subchondral cysts
  - Marginal osteophytes
- Treatment - Conservative Management is first line
  - Tylenol is initial drug of choice (good efficacy and safety profile)
  - NSAIDs also effective but long term use poses hazards
  - Exercise, weight loss, steroid injections, ice, and taping
    - Steroid or viscosupplementation injections can be repeated as needed. Less concern for articular degeneration as arthroplasty is considered in most cases.
    - Knee injections are routine office procedures. For hip arthritis, fluoro-assisted injections are recommended (IR appointment).
  - Joint replacement indicated for advanced disease in select patients

### Arthroplasty

- Common contraindications
  - Neuropathic or infected joint, medically unstable patient, young patients at high risk of wearing out the prosthesis.
- Complications/Failure
  - Like any device, hardware will inevitably wear and fail if stressed enough over time.

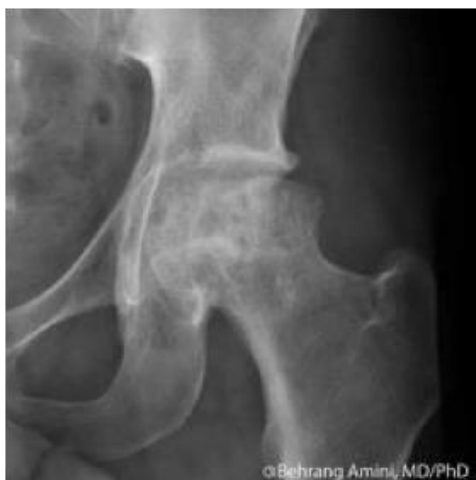It is recommended that you read “complications of total hip arthroplasty” and “complications of total knee arthroplasty” on UpToDate.

It will be important for you to be familiar with these frequently encountered terms while on service:

Osteolysis, aseptic loosening, infection, patellar clunk, polyethylene wear, implant fracture, leg length discrepancy, periprosthetic fracture, heterotrophic ossification, and periprosthetic dislocation.

#### Avascular Necrosis (Osteonecrosis) of Femoral Head

- Anatomy/Pathophysiology
  - Impaired blood supply causes osteocyte and other cell death.
  - Anteromedial femoral head is a particularly vulnerable location and is particularly problematic because it is a weight-bearing joint.
  - Trauma is the #1 cause, with alcohol and steroid use being the most common non-traumatic causes. Many diseases that compromise blood flow are also implicated (Sickle Cell Anemia, Factor V Leiden, etc).
- Symptoms/Physical Exam
  - Patients often present with gradually increasing pain worsened by activity.
- Diagnosis
  - MRI is 95% sensitive and specific - signal changes within days of onset.
  - X-ray cannot pick up early disease but will show subtle osteopenia, subchondral collapse (crescent sign), and eventually joint flattening with narrowed articular surface.
  - Although many classifications exist, the Ficat classification is most often referenced.
- Prognosis
  - 80% of cases progress to significant arthropathy.
- Treatment
  - Symptomatic relief - limiting weight bearing not shown to alter course.
  - Core decompression +/- grafting
  - Arthroplasty



### THA for Hip Fractures

#### Femoral neck fracture (Garden classification)

- Indicated for highly functional patients (cognition, medical comorbidity)
- Patients >60 with good bone density
- Faster full weight bearing, eliminates nonunion, and fixation failure
- Unipolar hemiarthroplasty is more appropriate if level of function is more limited

#### Femoral head fracture (Pipkin classification)

- THA indicated for elderly patients with Pipkin type III, with displaced femoral neck fracture
- Certain instances of Pipkin type IV, involving acetabular fracture

### Anatomy

Joint replacement surgery is unique in its focus on proper alignment and range of motion. Know the anatomy of the knee and hip cold, then study it some more. In the knee, focus especially on tendinous insertions and be sure to know the popliteal neurovasculature. Take time to learn how a primary TKA works and how it compares to a normal knee. The midline anterior approach is nearly exclusive at UVA so study the layers and structures at risk (infrapatellar branch of saphenous nerve). In the hip, focus on the hip abductors and their proximity to the sciatic nerve (particularly the piriformis muscle). The arterial supply to the femoral head is provided mainly by the medial femoral circumflex artery (from deep femoral artery) with a smaller contribution by the foveal artery (from obturator artery). The obturator artery is also encountered.

One huge advantage of the Joints service is that the operations are frequently similar and involve the same specific parts of the body. You should be able to prepare at home and not have to worry about looking up information on the fly.

### Rounding Tips

Typical start time: 05:30-06:00 (depends a lot on list size, which can be considerable at times)

Recommended student arrival: 05:00

The Joints service is rounding-heavy so it is important to be efficient. As a student, you can help out greatly by arriving 30 min early and printing the list and adding the following information by hand and then making copies for the residents:

Which surgery, POD #, drain output, anticoagulation (Warfarin, Lovenox, Aspirin, etc.)  
Accuracy of information is extremely important.

Students can also help with dressing changes. You will need trauma shears. For total knee arthroplasty dressing changes (day two), cut through the top of the ace wrap before the team comes by. Have a good supply of covaderm in various sizes each morning as well as some spare 4x4 gauze and steri-strips (all found in clean supply room).

Total knee patients are typically discharged on POD #3 and total hip patients on POD #2 or #3.

#### Immediate Postoperative Complications and Care

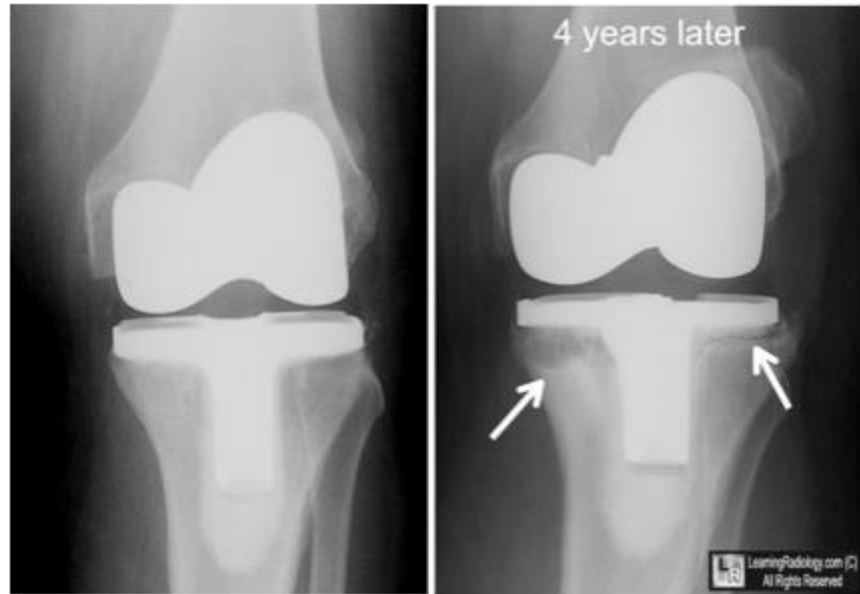- Your primary concerns will be infection, DVT, and sciatic nerve injury. It is essential to check plantarflexion and dorsiflexion postoperatively. Sciatic nerve damage is often neurapraxic and caused by intraop ROM testing and retraction, but with significant leg length correction there is concern for sustained nerve hyperextension.
- After discharge, intensive rehabilitation to prevent joint scarring and to ensure optimal function is tailored to specific needs of patient.

#### Clinic

The Adult Reconstruction clinic is in the 545 Ray C. Hunt Drive Fontaine Orthopaedic clinic (same as Trauma, Foot/Ankle). You can expect to spend one day per week in clinic. Don't be shy about being there just one day a week - the attendings like for you to see as many operations as possible while on this service! That being said, it's very important for you to have a firm grasp of how patients come to need joint replacement. Patient diversity is somewhat less than other services, so this is a great time to really know your stuff! Your role in clinic will vary, so establish expectations each time you work with a different attending. This is one instance where you need to ask before you start seeing patients by yourself. It might be wise to shadow a few patient encounters on your first day. Many patients present with a similar picture, so watching a few will pay dividends, should you see patients on your own or write notes.

Arthroplasties are major operations and not everyone is a good candidate. Patients will invariably present with pain. As the degeneration progresses, function declines. Be sure to get a good grasp of the patient's disability (work, leisure, mobility). Remember to check the contralateral side! DJD is often bilateral but not always symmetric, so don't be distracted by the patient's focus on one side.

Postop office visits focus on patient's function (including physical therapy progress), pain, and radiographic status of component/bone interface. Staying active and pursuing good physical therapy is paramount to the operation's long-term outcome.



Take note of the peri-prosthetic lucency in this image of a loose tibial component.

## FOOT AND ANKLE




### **Overview**

Understanding pathologies of the foot and ankle is incredibly challenging without first having a detailed understanding of normal foot biomechanics and anatomical relationships. On the Foot and Ankle service, you will see a wide range of abnormalities ranging from lesser toe deformities to severe structural deficiencies causing multiple pathologies and symptoms within the foot and ankle. A large portion of the most technically challenging and exciting cases are revisions of failed prior procedures and are unique in that creative solutions are required to work around already distorted anatomy. This service is not resident/fellow heavy and, with an expanding faculty, you will have the opportunity to get great exposure to the many operative techniques performed here.

### **Suggested Reading**

Thompson. Netter's Concise Orthopaedic Anatomy, 2nd ed. Chapter 10: Foot/Ankle.  
Hart, Jennifer, Miller, Mark D., Thompson, Stephen R. Review of Orthopaedics, 6th Edition. Elsevier Saunders. 2012.

### **Division Structure**

		
<b>Joseph S. Park, MD</b>	<b>Venkat Perumal, MD</b>	<b>Truitt Cooper, MD</b>
Associate Professor of Orthopaedic Surgery Division Head	Assistant Professor of Orthopaedic Surgery	Associate Professor of Orthopaedic Surgery Medical Director of Ambulatory Clinics

James Shorten, M.S., P.A., Physician Assistant  
PGY-3 or PGY-4 Senior Resident  
No Fellows

## Conditions Frequently Seen

### Hallux Valgus

- Anatomy/Pathogenesis
  - Lateral deviation of great toe with medial deviation of 1st metatarsal. Pathoanatomy includes:
    - Medial capsular attenuation, secondary contracture of lateral capsule and adductor hallucis.
    - Lateral movement of proximal phalanx -> plantar-lateral migration of abductor hallucis -> pronated, plantarflexed phalanx.
    - Medial deviation of 1st metatarsal -> increased intermetatarsal angle.
- Radiographic Evaluation often determines type of treatment required. Important angles to know are:
  - Hallux Valgus angle (HVA): long axis of 1st MT and proximal phalanx (normal <15)
  - Intermetatarsal angle (IMA): long axis of 1st and 2nd MT (normal <9)
  - Distal Metatarsal Articular angle (DMAA): 1st MT long axis and line through base of distal articular cap (normal <15)
  - Hallux valgus interphalangeus (HVI): long axis of distal phalanx and proximal phalanx (normal <10)

	HVA	IMA	Modifier	Procedure
Mild	<25	<12	Distal Osteotomy	Chevron. Biplanar if DMAA >15
Moderate	26-40	13-15	Proximal osteotomy +/- distal osteotomy	Chevron + Akin
Severe	41-50	16-20	Double Osteotomy	Proximal MT osteotomy
			1st TMT instability	Lapidus
			Elderly patient, low function	Keller procedure
			Juvenile pt with DMAA >20	Double osteotomy of 1st ray



### Hallux Rigidus

- Know surgical options: cheilectomy (early arthritis/maintained joint space with large osteophyte dorsally) versus arthrodesis (fuse in slight dorsiflexion to allow shoe wear/clear the floor).

### Ankle Arthritis

- Options:
  - Fusion: coronal plane malalignment, poor pre-op ROM, age <60, medical issues.
  - Total Ankle Replacement: older, good pre-op ROM/alignment, BMI <30. Life span of prosthesis 10-15 years.

Lesser Toe Deformities: mallet toe, hammer toe, clawtoe and hard/soft corns. Multiple etiologies and treatment modalities possible. Often related to long 2/3 metatarsals or from shortening of hallux MT from previous surgery. Clawing implies that it affects all toes.

	Claw Toe	Hammer Toe	Mallet Toe
DIP	flexion	extension	flexion
PIP	flexion	flexion	normal
MTP	hyperextension	normal	normal

### Flatfoot Deformity

- Anatomy/Pathogenesis
  - Acquired etiologies
    - Posterior tibial tendon dysfunction = most common cause
    - TMT joint arthrosis
    - Severe midfoot arthritis or Charcot changes
    - Talonavicular collapse - commonly due to incompetent spring ligament
  - Congenital
    - Conditions characterized by generalized ligamentous laxity (Marfan syndrome, Ehlers-Danlos syndrome)
    - Tarsal coalitions
- Symptoms/Physical Exam
  - Medial foot pain with loss of arch
  - Other findings = “too many toes sign” when viewed from behind patient, inability to perform single heel rise, +/- ability to be passively correct hindfoot valgus
- Treatment
  - Directed by stage of disease and patient characteristics.

- Triple Arthrodesis: rigid deformity, increased BMI, pre-existing arthritis.
- Flatfoot Reconstruction: normally involves calcaneal osteotomies and flexor digitorum longus transfer to the navicular. The posterior tibial tendon cannot be repaired.

### Ankle Instability

- Injury to the Anterior Talofibular Ligament causes *internal rotation* instability, more than *anterior drawer* instability
- Can be accompanied by *peroneal tendon* subluxation due to *superior peroneal retinacular* tear/attenuation and/or a shallow peroneal groove.
- Surgery: ankle scope/Brostrom Procedure

### Achilles Tendinopathy

- Distinguish between *insertional* and *non-insertional*
- Reconstruction often requires flexor hallucis longus transfer to augment reconstruction
- <3 cm: V-Y lengthening, >3-10 cm: Central 1/3 Turndown, >10 cm: Potential gracilis allograft.

## Anatomy

The anatomical relationships of the bones, ligaments and tendons of the foot and ankle are exquisitely tied to their functions at various points in the gait cycle. The most common questions asked in the OR relate to structures at risk during various approaches. A working knowledge of ankle biomechanics and movement is critical in understanding the clinical consequences when parts go awry. Know the movements of each part of the foot/ankle.

	Ankle Joint	Subtalar Joint	Transverse Tarsal Joint
Pronation	Dorsiflexion	Eversion	Abduction
Supination	Plantarflexion	Inversion	Adduction

In addition to the skeletal anatomy, learn the tendinous insertions and how each muscle contributes to movement about a joint. This can be greatly simplified by understanding the anatomic relationships of the muscles relative to the axes of the ankle (anterior - dorsiflexion or posterior - plantarflexion), subtalar (medial - inversion or lateral - eversion), and transverse tarsal joint. Learn the motor innervations to each muscle compartment. Understand the sensory areas provided by terminal branches of the saphenous, deep peroneal, sural, superficial peroneal, and tibial nerves.

## General

Remember to introduce yourself to patients/OR staff/clinic staff as a \_\_ year medical student,

working with Dr. Park/Perumal, etc. Also, remember to always refer to the resident and attending as Dr. in professional settings, regardless of how well you know someone outside of the hospital. Understanding how the hierarchy works is a very important part of being a student. Dress in shirt/tie/white coat (skirt or pants/shirt for women) for clinic, and make sure your grooming/appearance is compatible with a professional orthopaedic practice. Always ask the OR staff if you can help them (pulling your own gown/gloves is a good example) and try to be available and helpful in every situation. If you think of yourself as the lowest man/woman on the totem pole, it helps you to learn how to treat everyone around you. This respect/consideration will serve you throughout your career, even as an attending. Every task, no matter how small, is a learning opportunity. For example, the PCT's can teach you a lot about how the room is set up, how a particular attending likes his dressing/splints, and how to stay out of trouble during complex procedures.

## **Rounding**

While the inpatient volume is usually very manageable, helping the resident with dressing supplies, looking up culture results/lab results, reviewing notes from other services, can all be very helpful. Remember that to be a great medical student, your job is to help the resident/PA at all times, and make their job easier. Always ask if there is something else you can do to help. No one ever forgets a lazy medical student, no matter how well they do on the rest of the rotation.

## **Clinic**

The clinic schedule is subject to change, as the department is currently expanding. Expect to spend at least two days in this setting. We take care of a broad spectrum of patients, from UVA/JMU Varsity athletes, to 80 year olds with severe foot deformities/arthritis.

Pay attention to the numbering system above the patient rooms, as that indicates who is next in line to be seen. If the patient's folder is placed vertically in the holder outside their room, they have not yet been seen. After you see the patient, place the folder horizontally to indicate that you've done so.

You can be helpful in clinic by seeing the **initial visits** and recording a thorough H&P, which you can later dictate to the scribe and/or write on the back of the patient's chart. Dates of previous surgeries, date of injury, mechanism of injury, modalities tried are all helpful for documentation. Smoking status, narcotic use, medical history, bleeding or clotting disorders, and employment/disability status are also very helpful for assessment. Surgical follow ups are typically quick visits that can be managed by the attending or resident. Confirm with the scribe/resident/PA that all information has been properly transferred into EPIC.

Patients will often get X-rays prior to coming back into the exam rooms, which the nursing staff generally pull up on PACS. Just double check this is done before calling an attending into the room. If you're unsure about a patient's post-op recovery course, a good place to look is the full operative

report, which Dr. Park usually does himself. He often will include a section in the bottom that details weight bearing status, when the patient should follow-up, restrictions, bracing required, etc.

#### Approach to the Foot exam:

1. Inspection: do this with patient sitting/supine if possible and standing. View the foot from all angles, from posterior note the heel alignment (VARUS/VALGUS) and if “too many toes” are present. Inspection of the arches of the foot, prominent deformities, callosities or ulceration and swelling can all clue the clinician in on the underlying pathology.
2. Measure ankle motion in multiple planes: the zero position is with the foot perpendicular to the tibia. Don’t forget to compare findings in the contralateral foot. Know the “normal” range of motion for each joint, but recognize that each individual is different, and often the most striking values are those that are relative to the unaffected foot. Document ankle dorsiflexion/plantarflexion, as it may reveal achilles contracture.
3. Exam: document areas of tenderness/swelling. Dr. Park will perform a focused exam and point out findings during his exam.
4. Posting Cases: Students can be helpful by providing the patient with the Anesthesia Questionnaire, and informing the resident that a surgery is being posted. All colored flags can be displayed to let the nursing staff know.
5. Suture Removal: can be performed by the student if comfortable doing so. Discuss with Cheryl, our cast-tech.

#### Operating Room

1. Know your anatomy. Get a list of the surgeries for the next day, and discuss with the resident on service. Know the bony anatomy, planned approaches, what vessels/nerves may be seen/protected, and what tendons/muscles are near the surgical approach. Know the names of the bones of the foot/ankle, especially in the area of interest. It is ok to get a question wrong, but make sure you look it up, and don’t get the same question wrong the next day.
2. Know when to ask questions. Typically, the best times to ask questions are: during scrubbing, closing, or splinting. Asking questions during the surgical approach or stressful moments of a surgery can be very counter-productive.
3. Maintain sterile technique: If a breach of sterile technique takes place, inform the OR team immediately. Err on the side of safety at all times.
4. Bovie: Use the bovie to touch the Debakey forceps used to coagulate vessels. Always check to make sure the instruments are not touching skin, as it will cause a burn. Return bovie to holster after using it.
5. Suction: Make sure to keep the surgical field clear of blood/irrigation so that the resident/PA/Attending can see the necessary anatomy.

6. Suturing: The resident/PA will show you how Dr. Park/Perumal like wounds to be closed. Typically, the student will help on the subcuticular layer (#3-0 monocryl, interrupted) and skin (#3-0 Nylon or novafil in modified horizontal mattress) layers, if they have sutured before. Do not be offended if the resident/attending closes if cases are running behind, or if the case is taking place after business hours. Be prepared to cut sutures in that case.
7. Cutting sutures: Typically, sutures for deeper layers are cut with a minimal tail, just off the knot. Tails for skin sutures should be left ~1.5 cm long to facilitate easy suture removal.
8. Splinting: Help the resident/PA splint by holding the leg. Typically, the ankle is held in neutral position, but this depends on the specific procedure being performed.
9. Help take the patient to recovery, and help the resident/PA in any way necessary. Do not sit down and let other people (nurses/PCT's/anesthesia) do work that a student can do.
10. Ask for feedback from the attending/resident if you are unsure about anything.

## HAND / UPPER EXTREMITY

### **Overview**

The Hand and Upper Extremity division deals with all orthopaedic ailments and injuries of the hand, wrist, and arm. The focus lies as much on the soft tissue structures as it does on bones and joints, with emphasis on the restoration of a person's fine motor dexterity. It is important to understand the implications of an injury or degenerative disease of the hand. A seemingly benign injury to a patient's finger could ultimately lead to a significant impairment that prevents him or her from staying in a particular profession or enjoying a hobby. Just about every patient places immense value on the hand and uses the hand to perform countless daily tasks. For example, even a sensory deficit limited to the tip of the small finger can make an activity like typing very difficult. It is important to remain cognizant of these details when interacting with patients.

As a student on this service, you will see a heavy clinic load and participate in a higher number of cases that are generally shorter than your average orthopaedic or general case. Cases are often performed seated at a hand table with the patient under conscious sedation. There will not typically be a large role for a student to retract or close large incisions, but there will certainly be many opportunities to help out and keep things moving smoothly. While a hand table may seem full with 2 surgeons, do not be shy. Scrub in and be part of the team. You will have the opportunity to see amazing anatomy, and your interest will usually be rewarded by attendings and residents interacting with you more. You will quickly appreciate how complex the hand is and what a miracle it is that your fingers and wrist can do what they do! In addition, good case turnover can make or break a day at the outpatient surgery center, so do everything you can to help the staff get the next patient underway.

### **Suggested Reading**

Green's Operative Hand Surgery  
Campbell's Operative Orthopaedics (available on UVA HSL)  
Carpal Ligament Surgery (available on UVA HSL)

### **Division Structure**

	
<p><b>A. Bobby Chhabra, MD</b></p>	<p><b>A. Rashard Dacus, MD</b></p>
<p>Lillian T. Pratt Distinguished Professor of Orthopaedic Surgery Chairman of UVA Orthopaedic Surgery Division Head</p>	<p>Associate Professor of Orthopaedic Surgery Vice Chair for Diversity and Clinician Wellness</p>
	
<p><b>Nicole Deal, MD</b></p>	<p><b>Aaron M. Freilich, MD</b></p>
<p>Associate Professor of Orthopaedic Surgery Co-Director Hand Center Fellowship Director</p>	<p>Assistant Professor of Orthopaedic Surgery Co-Director, Fellowship Program</p>



**Brent DeGeorge, MD, PhD**

Assistant Professor  
Department of Plastic and  
Reconstructive Surgery

Kelsey Parente, M.S., P.A., Physician Assistant

Amy Radigan, MPAS, PA-C

Hand Fellow (2)

PGY-5 Chief Resident

PGY-3 Mid-level Resident

### Conditions Frequently Seen

Nerve Compression Syndromes - Carpal Tunnel, Cubital Tunnel, Guyon's Canal (distal ulnar nerve)

- Carpal Tunnel - most common compressive neuropathy
  - Anatomy/Pathogenesis
    - Know borders of carpal tunnel: floor = proximal carpal row, roof = transverse carpal ligament, ulnar = hook of hamate and pisiform, radial = scaphoid tubercle and trapezium
    - Components of tunnel - nine flexor tendons (flexor pollicis longus (most radial), flexor digitorum superficialis x 4, flexor digitorum profundus x 4) and median nerve
  - Symptoms - numbness/paresthesias in radial three and a half digits (may even wake patient at night), clumsiness
  - Physical Exam
    - Thenar atrophy - very important as this is least likely sign to resolve with surgery
    - Positive Durkan compression test is most sensitive. Other tests include the Phalen test, Tinel's sign
  - Diagnosis is clinical! EMG and nerve conduction velocities can support diagnosis.



- Treatment
  - Conservative care = NSAIDs, activity modification, night splints or steroid injections
  - Carpal Tunnel release - reserved for patients who fail conservative modalities, or with acute symptoms s/p ORIF of nearby structures.
- Open vs. endoscopic release: main benefit of endoscopic is earlier return to work but there is a higher risk of incomplete release

### Trigger Finger (Stenosing Tenosynovitis)

- Anatomy/Pathogenesis
  - Common in: women, >50 years old, diabetic patients or those with an inflammatory arthropathy, occupational/recreational repetitive finger activities.
  - Represents entrapment of the A1 pulley due to fibrocartilaginous changes.
    - A1 pulley overlies the MCP joint
    - Most commonly involves ring finger
- Symptoms and Physical Exam
  - Affected finger eventually becomes locked in flexed position and patient must force extension using other hand; tenderness over A1 pulley with palpable nodule
- Treatment
  - May respond to corticosteroid injection
  - Surgical release of A1 pulley if failed conservative therapy and + locking

### Dupuytren's Contracture

- Anatomy/Pathogenesis
  - Benign fibroproliferative disorder. Myofibroblast proliferation implicated.
  - Nodule in palmar aponeurosis progresses to form cords and flexion contractures at MCP joint.
    - Different cords involved: spiral cord, central cord, retrovascular cord.
- Of note, Cleland's ligament is the only dermal ligament not involved in Dupuytren's disease.
  - Autosomal dominant with variable penetrance. Also associated with TOB/ETOH use, diabetes, TB, COPD, and HIV/AIDS
  - Extrapalmar locations indicates more aggressive disease (look up Garrod knuckle pads, Ledderhose disease, Peyronie disease)
- Symptoms/Physical Exam
  - Nodules may be painful
  - Decreased range of motion of affected digits, most commonly small and ring finger
  - Palpable nodule(s) in palmar fascia
  - Hueston's tabletop test - look for MCP or PIP contracture when palm is placed flat on a table. An MCP flexion contracture >30 degrees or any PIP contracture is an operative indication.
- Treatment
  - Non-operative modalities (injections - eg. Xiaflex = collagenase, exercise) can be attempted first, but are often unsuccessful long term

- Surgical options = open limited fasciectomy (1st choice), open-palm McCash technique, or percutaneous aponeurotomy
- Most common complication is recurrence. Rates can exceed 50%, especially in setting of more aggressive disease (diathesis).

### Arthritic Conditions

- Osteoarthritis is most common
  - Symptoms/Physical Exam
    - Pain, swelling, decreased motion
  - Treatment
    - Conservative = activity modification, NSAIDs, intra-articular corticosteroid injections
- Most common = distal interphalangeal (DIP) joint
  - Anatomy/Pathogenesis
    - Look for Heberden nodes formed from osteophytes
    - Symptomatic mucous cysts can be removed for quick relief
  - Symptoms/Physical Exam
    - Can be asymptomatic despite striking radiographic changes
  - Treatment
    - Arthrodesis for pain and deformity refractory to conservative care
- Second most common = carpometacarpal (CMC) joint
  - Anatomy/Pathogenesis
    - Attenuation of the volar oblique (beak) ligament leads to joint instability and pathologic subluxation
    - Trapezium shape creates a saddle joint with 1st metacarpal
  - Symptoms/Physical Exam
    - Difficulty with pinching activities
    - Pain with CMC grind test
    - Very commonly concomitant with carpal tunnel syndrome
    - Staged based off of Eaton and Littler Classification
  - Treatment
    - Many surgical options available ranging from ligament reconstruction to joint arthrodesis, depending on patient characteristics and stage of disease
- Ligament Reconstruction and Tendon Interposition (LRTI)
  - removal of trapezium, replaced with FCR tendon

### Triangular Fibrocartilage Complex (TFCC) Tears

- Anatomy/Pathogenesis
  - The TFCC stabilizes the distal radioulnar joint (DRUJ) and transmits a portion of the axial load at the wrist
  - Components = radioulnar ligaments (dorsal and volar), central articular disc, ECU subsheath, a meniscus homologue, and the origins of the ulnolunate and ulnotriquetral ligaments

- Ligamentum subcruentum - refers to the deep radioulnar ligaments
- Tears: classes are broken down into subtypes based on anatomic location of tear - extremely important when discussing management and prognosis
  - Traumatic (class I)
    - Fall on extended wrist in pronation with traction injury to ulnar side of the wrist
  - Degenerative (class II)
    - Associated with positive ulnar variance and ulnocarpal impaction syndrome (impaction of the distal ulna on the ulnar-sided carpal bones like the lunate)
- Symptoms/Physical Exam
  - Wrist pain, especially with pronation-supination activities
  - Pain with radial or ulnar wrist deviation
- Diagnosis
  - Radiographs usually benign, may show ulnar variance
  - MRI has high sensitivity
  - Arthroscopy is gold standard
- Treatment
  - First with nonoperative care (NSAIDs, immobilization/activity modification)
  - Arthroscopy vs. open repair indicated when conservative management fails. Many procedures are available depending on classification of TFCC tear.

## **Anatomy**

8 Carpal Bones (trapezium, trapezoid, capitate, hamate, triquetrum, pisiform, lunate, scaphoid)

\* Learn to recognize carpal bones from multiple angles on x-rays of the hand

Brachial Plexus and peripheral nerves

Intrinsic vs. extrinsic hand muscles

Flexor tendon pulley system and insertion sites

6 dorsal compartments of the wrist

Quadrage effect and flexor tendon biomechanics

Carpal tunnel contents and boundaries

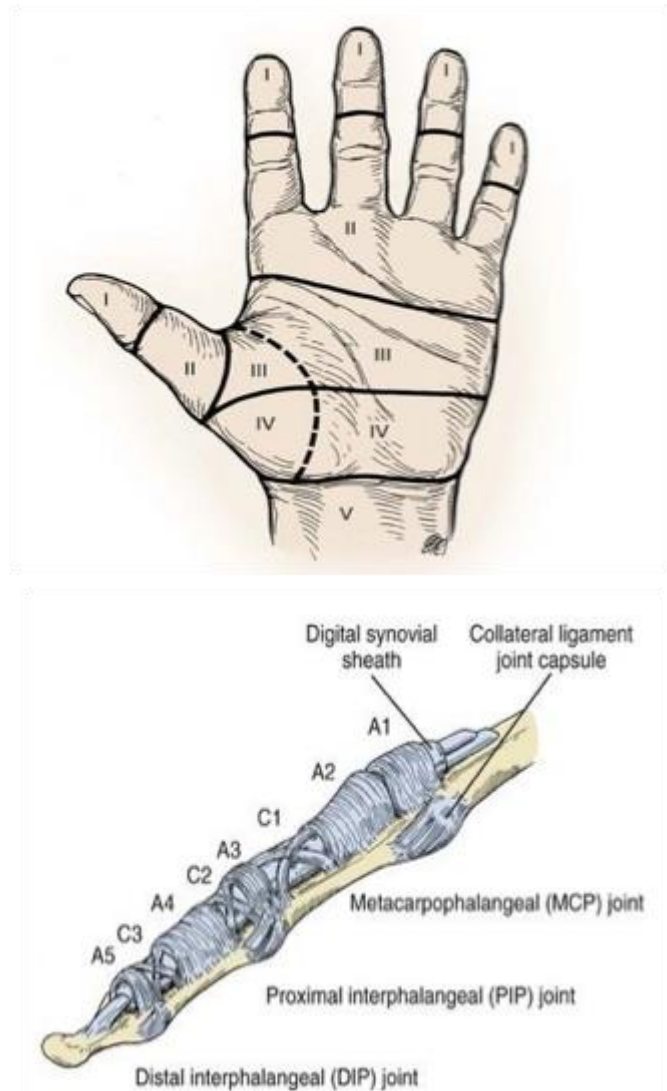
## **Other things to know:**

Common fractures to recognize and know, anatomy, surgical indications, and approaches:

- Scaphoid fracture - most common carpal fracture, most difficult to heal
- Distal radius fracture
- 5th metacarpal fractures
- Crush fractures of the distal phalanges

Hand lacerations are very common, as people are always using their hands and putting them in risky places. Of particular concern is a laceration of a flexor tendon, especially in Verdan zone 2. All

hand injuries require detailed knowledge of anatomy to properly assess for neurovascular injury.



Know the flexor tendon pulley system and Verdan zones of the tendon sheath. A2 and A4 are the most important pulleys and prevent bowstringing of the skin during digit flexion. A1 is the pulley that is released during surgery for trigger finger.

### **Rounding Tips**

Typical start time: 06:00

Recommended Student arrival: depends on number of patients: ask resident day to day.

Hand patients on the floor are usually admitted because of a traumatic injury. The focus is often traumatic reconstruction and infection, but monitoring a digit's viability, for example in ischemic vascular disease in the digits, is also a frequent indication. Inpatient consults could include any

hand condition, but the emphasis is usually on trauma, infection, and soft tissue viability as well, perhaps in the context of a multitrauma or a vascular patient. For hand infections, stay up to date on antibiotic regimens, culture results, and ESR/CRP/WBC numbers. Analyze preoperative and postoperative radiographs on all of your patients and try to understand the rationale for why the surgeons are operating on each pathology.

Be very careful with dressing changes! Hand wounds are heavily innervated and can be very painful to manipulate as well as vulnerable to harm. You will often do the dressings with your team, so make it priority #1 to have the necessary supplies: xeroform, 4x4 bandages, 1 L saline (if you need to soak a dressing to ease removal), steri-strips, ace wraps (2in, 4in), coban wrap, trauma shears, and a set of sterile scissors / pickups. And of course, have printed lists ready each day with any added information you think is pertinent to each patient.

## **Clinic**

Clinic location: UVA Hand Center - 3<sup>rd</sup> Floor Building 415 in Fontaine Research Campus  
Expect to spend two days in clinic every week.

Hand clinic will be busy. Before you see a patient, check to see you are in the correct area for the attending you plan on working with. The plastic surgery hand faculty also hold clinic in the hand center, so be sure you're seeing orthopaedic patients. Different doctors often have color-coded patient folders and will have patients in a specific set of rooms in the hall. Hand clinic visits can have an enormous diversity, which is what makes hand surgery such a unique field within orthopaedics. Although you will see some conditions more frequently than others, don't forget to be thorough and take that extra minute to ensure you've got what you need. For example, even if a patient says he or she is there to go over EMG/NCS studies for carpal tunnel syndrome, do the complete physical exam anyway. There are many special exam maneuvers for the hand, but it is a good idea to start with the basic hand exam:

Appearance: look for any abnormality and compare to contralateral hand. Atrophy is a good clue for long-standing nerve compromise.

Range of Motion: measure the angles! This is one index that requires precise measurement.

Sensation: don't ask if a patient can feel a sensation, ask if it's a normal sensation compared to the contralateral limb. If you find an abnormality, determine its exact boundaries and use two-point discrimination to try to measure its severity (there should be a tool available in clinic). If it fits a nerve distribution, be sure to include that in your presentation.

Motor: the quickest way is to test the terminal innervations of AIN, PIN, and the deep branch of the ulnar nerve: the OK sign, a six-shooter, and crossing the index and long finger, respectively.

Localize tenderness: before you do anything, ask the patient to point with one finger where it hurts the most. If he or she has trouble, try to get him or her to narrow it down to ulnar/radial/midline and volar/dorsal/midline. From there you can palpate and accurately find the point of maximal tenderness. Once you find the location, perform any special exams to hone in on a more specific pathology.

Helpful websites:

[http://www.orthoteers.org/content/documents/Exam\\_hand.pdf](http://www.orthoteers.org/content/documents/Exam_hand.pdf)

[Powerpoint of Hand/Wrist Exam](#)

## PEDIATRIC ORTHOPAEDICS

### Overview

Goals for medical students on the Pediatric Orthopaedic service include learning physical examination techniques for orthopaedic conditions in children, understanding the unique characteristics of fracture treatment and treatment of musculoskeletal disease in the growing child, with emphasis on congenital and developmental conditions, and interacting with patients of various ages and their parents. Students on this service also gain experience in the management of pediatric spinal deformities.

### Suggested Reading

Hart, Jennifer, Miller, Mark D., Thompson, Stephen R. Review of Orthopaedics, 6th Edition. Elsevier Inc. 2012.

- Chapter 3: Pediatric Orthopaedics

### Division Structure

		
<b>Mark F. Abel, MD</b>	<b>Mark J. Romness, MD</b>	<b>Keith R. Bachmann, MD</b>
Lillian T. Pratt Professor of Orthopaedic Surgery Division Head	Associate Professor of Orthopaedic Surgery	Associate Professor of Orthopaedic Surgery Assistant Residency Program Director

\*Dr. Abel has since retired, however, may be around for conferences/lectures!

Lee Ann Lather, M.D., - Non-operative Pediatric Orthopaedics

Emily Feiner, Physician Assistant  
 PGY-5 Chief Resident  
 PGY-2 Junior Resident

## Conditions Frequently Seen

### Scoliosis and Pediatric Spinal Deformity

- Anatomy/Pathogenesis
  - Lateral and rotational deformity of the spine with multiple etiologies
  - Idiopathic
    - Infantile < 3yrs
- Usually left thoracic, more common in males
  - Juvenile 3-10 years
    - Associated with syringomyelia, Arnold-Chiari syndrome, tethered cord, dysraphism, spinal cord tumor
    - High risk of progression
    - Operative treatment: VEPTR indicated if curve >50 degrees in child with significant growing potential. Rods grow with child until definitive fusion procedure when skeletally mature. VEPTR allows for correction of the spine deformity and separates the ribs so that the lungs can mature appropriately.
      - VEPTR = Vertical Expandable Prosthetic Titanium Rib.
      - View the Synthes website below for more information, and an instructional video for how this construct is used.
        - [http://www.synthes.com/sites/NA/Products/Spine/Screw\\_Hook\\_Rod\\_and\\_Clamp\\_System/Pages/VEPTR\\_and\\_VEPTR\\_II.aspx](http://www.synthes.com/sites/NA/Products/Spine/Screw_Hook_Rod_and_Clamp_System/Pages/VEPTR_and_VEPTR_II.aspx)
  - Adolescent >10 years
    - Neuromuscular– usually more rapidly progressive, associated with pelvic obliquity, encompass more vertebrae, higher rate of pulmonary complications
      - Associated conditions: cerebral palsy, Spinal muscular atrophy, muscular dystrophy, spina bifida and other spinal cord injuries
    - Congenital
      - \* Multiple congenital spinal anomalies possible, including failure of formation, failure of segmentation, hemivertebrae, etc.
- Adolescent Idiopathic Scoliosis – most common type of scoliosis. Typically right thoracic curve.
  - Risk factors for curve progression
    - Age < 12, skeletal immaturity (Risser <2)
    - Curve magnitude before peak height velocity (best predictor). Occurs during Risser stage 0, digital skeletal age of 4-6, or before menarche
      - Curve >30 degrees before peak height velocity is a strong risk factor



for future need for surgical intervention

- Curve >20 degrees in young patient, >45 degrees at skeletal maturity
- Symptoms/Physical Exam
  - Waistline asymmetry, rib rotational deformity, prominent scapula with shoulder elevation
    - Be on the lookout for other findings: e.g. Café-au-lait spots (neurofibromatosis-1), midline skin defects (spinal dysraphism), asymmetric reflexes (syringomyelia), etc.
- Diagnosis
  - Rotational deformity noted on Adams forward bend test. This is often done as routine screening in school or by pediatrician. >7 degrees deviation with use of a scoliometer is a commonly accepted cutoff for referral
  - Standing AP/Lateral radiographs
    - Cobb angle (scoliosis = >10 degree curve)
    - Assess Risser stage
  - MRI indicated for: painful scoliosis, left thoracic curves, juvenile onset, rapid progression of curve, presence of neurological symptoms
- Treatment – varies depending on the likelihood of curve progression
  - Non-op
    - Observation indicated in lower risk patients (immature curves < 25 degrees, mature curves (Risser >2) less than 45 degrees
    - Bracing to stop progression of deformity if 25-45 degrees, flexible in skeletally immature patient
  - Operative
    - Posterior and/or anterior spinal fusion. Posterior is gold standard for most thoracic and double major curves

## Hip Conditions

- Developmental Dysplasia of the Hip (DDH) - most common orthopaedic disorder in newborns
  - Anatomy/Pathogenesis
    - Shallow and underdeveloped acetabulum and capsulo-ligamentous laxity leading to possible subluxation or dislocation of the hip
    - Risk factors = first born, breech birth, family history, female, Native American, improper swaddling
  - Symptoms/Physical Exam
    - If child is < 3 months
      - Barlow test: identifies a dislocatable hip by adduction and depression of flexed hip
      - Ortolani test: reduces a dislocated hip by elevation and abduction
    - If child is >3 months - limitation in hip abduction is more sensitive because hip soft tissue contractures limit aforementioned maneuvers
  - Diagnosis: Ultrasound used before femoral head ossification at 4-6 months.

Radiographs can be utilized thereafter.

- Treatment
  - Pavlik harness has high success rate in DDH identified before 6 months.
  - Closed reduction and spica casting is used if dysplasia is identified after 6 months or failure of Pavlik harness.
- Legg-Calve-Perthes Disease
  - Anatomy/Pathogenesis
    - Common presentation at 4-8 years of age, M > F
    - Avascular necrosis of femoral epiphysis
    - Increased risk in low birth weight children, second hand smoke exposure, Asian/Eskimo descent, family history
    - 4 pathologic stages: 1. initial infarction; 2. fragmentation of femoral head; 3. reossification with resorption of necrotic bone; 4. healing/remodeling of femoral head
  - Symptoms/Physical Exam
    - Intermittent knee, hip or thigh pain
    - Trendelenburg gait/antalgic limp
    - Loss of internal rotation and abduction
  - Diagnosis
    - AP and frog leg radiographic views of pelvis show medial joint space widening +/- a crescent sign indicative of a subchondral fracture
  - Treatment
    - Most can be managed with conservative care. The goal is to keep the femoral head contained while maintaining good range of motion
    - Femoral or pelvic osteotomies may be indicated in some patients
- Slipped Capital Femoral Epiphysis (SCFE)
  - Anatomy/Pathogenesis
    - Unfavorable mechanical forces (obese, male, during rapid growth age 10-16) on perichondral ring cause slippage of proximal femoral epiphysis through the hypertrophic zone of the growth plate
    - Femoral neck rotates externally, displaces anteriorly while head remains in acetabulum. Looks like scoop of ice cream falling off the cone.
    - Classified as stable (able to bear weight +/- crutches), or unstable (unable to ambulate even with the use of crutches)
  - Symptoms/Physical Exam
    - Groin or knee pain predominate, preference to sit cross-legged
    - Loss of hip internal reduction, abduction and flexion
    - Externally rotated gait
  - Diagnosis
    - AP and frog-leg radiographic views of both hips
    - Klein's line: normally a line drawn along the superior border of the femoral neck will intersect with the femoral head.
  - Treatment

- Percutaneous in situ fixation (bilateral as prophylactic measure if contributing endocrine abnormality is identified)

Cerebral Palsy - These patients represent a population that requires very focused and specific attention to have positive outcomes in their quality of life.

- Anatomy/Pathogenesis
  - Nonprogressive CNS upper motor neuron disease due to injury to the immature brain. Prematurity is the most common cause, but other identified factors include anoxic injury, perinatal TORCH infections, meningitis, trauma
  - The resulting abnormal tone and muscular imbalance leads to impaired motor control and balance, muscular contractures, and a wide variety of bone and joint deformities.
  - Classified according to physiologic and anatomic features as well as stratified based on Gross Motor Function
    - Physiologic (spastic is most common, athetoid, ataxic, mixed)
    - Anatomic (quadriplegic, diplegic, hemiplegic)
- Orthopaedic Involvement
  - General: Spasticity control, physical therapy, bracing and orthotics
    - Continuously active muscles may be subject to surgical intervention with tenotomies or tendon lengthening procedures. Tendon transfers may be indicated to assist muscles firing out of phase.
  - Hip Conditions: hip subluxation due to continuously active adductors/flexors and a resulting scissoring position
  - Upper Extremity: deformities include shoulder internal rotation contracture, forearm pronation, elbow flexion, thumb-in-palm, clenched fist, and wrist flexion
  - Gait Disorders: - recommend you-tube videos to differentiate these gait abnormalities
    - Toe Walking - common in hemiplegics
      - Treatment (flexible) = Ankle-Foot Orthoses (AFO's). Treatment (fixed) = tendo-achilles lengthening (TAL)
      - <http://www.youtube.com/watch?v=YCk6MhJ95Aw>
    - Crouched Gait - common in diplegics due to hamstring contracture
      - Treatment = soft tissue releases about multiple joints
      - Scan through to 48 seconds:  
<http://www.youtube.com/watch?v=XefBS8bXp2Y>
    - Stiff-knee gait - common in spastic diplegics, out of phase rectus femoris
      - Treatment = tendon transfer of rectus femoris
      - <http://www.youtube.com/watch?v=hY36AQYGawE>

## Anatomy

Pediatric Orthopaedics is an incredibly broad subspecialty, dealing with the anatomy of the entire musculoskeletal system and a plethora of variant conditions secondary to congenital abnormalities.

It will be important to have a good working knowledge of pediatric bone growth and its unique qualities compared to the adult musculoskeletal system. Aside from those pediatric-specific characteristics, adequate preparation for cases the night before will be your saving grace in this rotation so that you have an opportunity to hone in on specific structures.

### Other things to know:

Classic Pediatric Fractures, Dislocations, and Conditions to know:

Supracondylar fractures

Nursemaid's elbow

Transient Synovitis vs Septic Arthritis

Obstetric Brachial Plexopathy (Erb's vs Kulmpke's palsy)

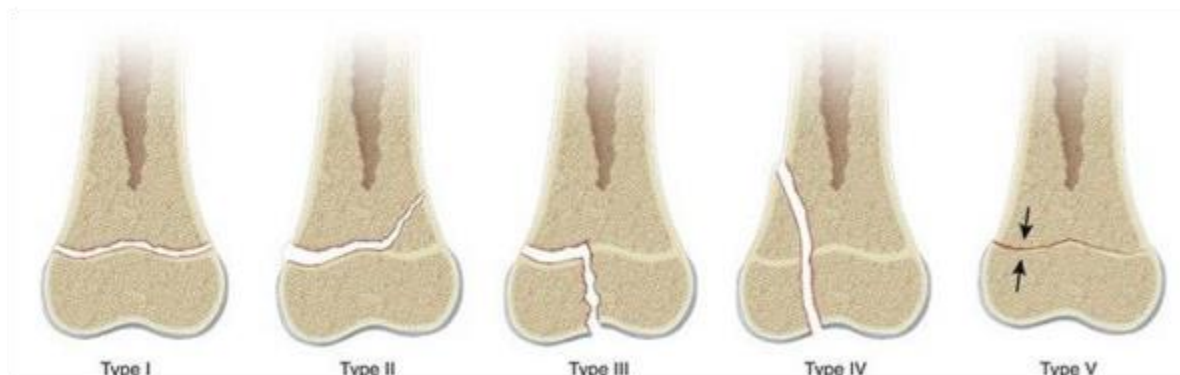Talipes Equinovarus (Clubfoot)

Orthopaedic considerations in systemic diseases: Down's, Turners, Ehlers-Danlos, Marfan's,

Lower Extremity deformities

- Bowleggedness (genu varum) - children often exhibit this from birth to 1-2 years of age before straightening to a neutral position.
- Knock-knees (genu valgum) - common condition peaking at 3-4 years old. Continued growth leads to normal adult alignment of slight valgus. Achieved at 7-8 years of age.
- In-toeing: most common etiologies = 1. femoral anteversion (medial femoral torsion) is the most common cause 2. internal (medial tibial torsion) 3. metatarsus adductus. Remember, vast majority spontaneously resolve! Parental reassurance is often the most important treatment!

Salter-Harris Classification - implications for treatment and prognosis in various fractures



### Rounding Tips

There are usually few inpatients to round on during your pediatrics rotation. That being said, Dr. Abel will want to know everything about his patients during AM rounds, especially scoliosis patients. He will want to know all vital signs, labs, and I's & O's, so be organized and be prepared to give a fairly formal presentation to him.

**Clinic**

Pediatrics clinic takes place in the Battle Building across the street from the main hospital. This is a good opportunity to channel your inner-pediatrician while also practicing your physical exam skills. The majority of these patients will have life-long debilitating diseases, but remember that they are still kids who likely just want to play outside.

## SPINE

### **Overview**

On the Spine service here at UVA, you will have a chance to develop an increased understanding of the unique biomechanics, structural abnormalities, and pathologies of the spine. The team of specialists here performs a wide range of procedures, ranging from minimally invasive same-day surgeries to complex spinal reconstructions. There is also a wide variety of patient presentations, from chronic lower back pain and arthritic changes in clinic to acute stabilization after a cervical fracture. The Orthopaedic Spine team alternates months of being on-call with the Neurosurgery team. Therefore, the service volume and necessity for acute surgeries varies drastically, depending on the timeframe of your rotation.

Spine surgeries are performed in “high-value real estate” and all are given careful attention, as mistakes during critical steps could yield devastating results for the patient. For obvious reasons, as a medical student on this service your tasks in the OR will generally not be as involved as on other services. It is nevertheless important to stay engaged, interested, and attentive to the procedure being performed. Often the best opportunities to ask questions are during pre-operative planning and in the PACU post-operatively. Be thoughtful about when you ask the attending questions during surgery; for example, you should wait until a non-critical step in the procedure rather than ask something while the attending is putting in an important pedicle screw. This highlights the importance of making the most of your clinic and hospital floor responsibilities.

Recommended, high yield knowledge is spinal anatomy (spinal segment vs spinal level, facet joint orientation, pars interarticularis, what nerve root exits out of each foramen such as C7 exits the C6-7 foramen whereas the L4 roots exits out of the L4-5 foramen), and strong understanding of spine exam (myotomes, dermatomes, upper vs lower motor neuron findings, reflexes). If you know your anatomy and exam you should be set for most questions that come your way.

### **Suggested Reading**

Thompson: Netter’s Concise Orthopaedic Anatomy. Chapter 2 - Spine.  
Available through library as ebook.

Greene: Netter’s Orthopaedics, 1st ed. Chapter 13 - Spine.  
Available through library as ebook.

## Division Structure

		
<b>Francis Shen, MD</b>	<b>Adam Shimer, MD</b>	<b>Hamid Hassanzadeh, MD</b>
Warren G. Stamp Professor of Orthopaedic Surgery Division Head	Associate Professor of Orthopaedic Surgery Medical Director	Associate Professor of Orthopaedic Surgery Spine Fellowship Co-Director

	
<b>Anuj Singla, MD</b>	<b>Xudong Joshua Li, MD</b>
Assistant Professor of Orthopaedic Surgery	Associate Professor of Orthopaedic Surgery

Nikki Ralston, P.A., Physician Assistant

Rose Tyger, P.A., Physician Assistant

Spine Fellow

PGY-3 or PGY-4 Resident ("Spine Chief")

PGY-2 Junior Resident

PGY-1 Intern

### Conditions Frequently Seen:

#### Lumbar Disc Herniation

- Anatomy/Pathogenesis
  - Most involve L4/L5 followed by L5/S1 and are posterolateral, affecting the descending nerve root at that level. Ex: L5/S1 posterolateral disk herniation affects S1 nerve root.
- Symptoms/Physical Exam
  - Back torsional strain in adult followed by acute low back and shooting pain down back of leg or buttocks. Symptoms often worsen with coughing, sneezing and sitting.
  - Include a thorough evaluation of lower extremity reflexes, sensation, as well as motor strength testing for a range of nerve root innervations
  - Include straight leg raise - supine patient will have reproduction of dermatomal leg pain at 30 degrees of hip flexion. **Eliciting low back pain with this maneuver is a negative test.** Test works based of tethering and tension of the affected nerve root.

Nerve Root Affected	Reflex Lost	Sensory Loss	Motor Loss
L4	Knee Jerk (Patellar)	Medial calf	Quadriceps , Anterior Tibialis
L5	None	Lateral calf, 1st dorsal interspace	Extensor hallucis longus
S1	Ankle Jerk (Achilles)	Posterior calf, plantar foot	Gastrocnemius, soleus



- Diagnosis
  - MRI is best study for disk pathology. Indications are:
    - Pain > 1 month unresponsive to conservative modalities.
    - Presence of any red flag signs/symptoms (infection [IV drug user, chills/fever], tumor [cancer history], significant trauma [MVC], cauda equina syndrome [bowel/bladder dysfunction, saddle anesthesia]).
- Treatment
  - First line = conservative therapy (physical therapy, NSAIDs, epidural steroid injections) before operative therapy (microdiscectomy) is discussed.
  - Exceptions = emergent/urgent surgery indicated for acute cauda equina syndrome. Earlier surgery considered for severe or progressive motor weakness.

### Lumbar Spinal Stenosis

- Anatomy/Pathogenesis
  - Decreased area in central spinal canal or foramina most commonly due to degenerative changes (facet or laminar osteophytes), spondylotic changes, or disc protrusion.
- Symptoms/Physical Exam
  - History of proximal to distal radicular symptoms. Weakness in thighs or calves with walking. Decrease in symptoms when walking with lumbar flexion (such as pushing a shopping cart; opens spinal canal) or relief of pain when walking up a hill or stairs.
  - Distinguish neurogenic claudication (spinal stenosis) from vascular claudication (arterial insufficiency).
    - Neurogenic – pain starts in buttock and progress distally, pain with standing or walking, pain improved with sitting down, walking up hill or up stairs easier than walking down, normal pulses, can cycle for long distances (remember lumbar flexion).
    - Vascular – pain starts in feet/calves and progressed proximally, pain with walking relieved by standing still, walking down hill or downstairs easier than walking up, absent or diminished pulses. Always check pedal pulses with spine exam.
- Treatment
  - First line = conservative therapy (PT, NSAIDs, weight loss, bracing, epidural steroid injections) before operative therapy (laminectomy/decompression)
  - Fusion (instrumented/noninstrumented) is generally reserved for stabilization of unstable spinal segments, as seen in anterolisthesis, lateral listhesis, or scoliosis.

### Chronic Low Back Pain

- Anatomy/Pathogenesis
  - > 8 weeks. Common in older adults with risk factors (occupation requiring frequent

- bending or heavy lifting, obesity and poor physical fitness, workers compensation)
  - Abnormal loading of facet joints and surrounding musculo-ligamentous structures due to degenerated discs and distorted spinal biomechanics that come with aging
- Symptoms/Physical Exam
  - Findings are often unrevealing or exaggerated by patients
- Radiographic imaging is often hard to differentiate from normal age-related changes.

### Cervical Radiculopathy

- Radiculopathy = pain defined to a nerve root, often due to a herniated cervical disc (young patients) or entrapment due to arthritic changes in the facet and uncinat process causing foraminal narrowing (older patients).
- Symptoms/Physical Exam
  - Neck pain that radiates in a dermatomal distribution down the arm (know your dermatome maps!). You may walk into the exam room to find a patient placing the ipsilateral forearm on top of the head. This helps decrease the tension on the affected nerve root and is a fairly classic sign (called the Shoulder Abduction sign). The patient may also endorse weakness or paresthesias in the affected hand in a specific distribution.
  - Exam should include the Spurling test, testing reflexes, sensation and strength in the upper extremities. Always perform myelopathy/upper motor neuron tests as well – tandem (heel-toe) gait, Hoffman's, lower extremity reflexes, ankle clonus.
- Treatment
  - If patient fails conservative management, operative considerations may include Anterior Cervical Discectomy and Fusion (ACDF) or posterior surgical decompression and fusion.

### Anatomy

33 vertebrae comprise the human spine: 7 cervical, 12 thoracic, 5 lumbar, 5 fused sacral and 4 fused coccygeal. Be aware of the normal curvature of the spine and their descriptors (cervical lordosis, thoracic kyphosis, lumbar lordosis). Know the individual parts of a vertebra including, but not limited to, the body, transverse and spinous processes, lamina, pedicle, pars interarticularis, foramina, and articular and costal facets. Know the various approaches to the vertebral column at different levels and their hazards.

Special vertebrae:

- C1 = Atlas. No vertebral body. Two superior facets articulate with occipital condyles. Anatomic relationship is important for neck flexion/extension.
- C2 = Axis. Dens process involved in the atlantoaxial articulation responsible for a majority of neck rotation. This joint is stabilized by the transverse atlantal ligament.
- Transverse processes in cervical vertebrae contain vertebral foramina, through which the vertebral artery travels (most commonly entering at C6 vertebral foramen).

### Spinal ligaments:

- Anterior longitudinal ligament - resists hyperextension
- Posterior longitudinal ligament - thinner sections located over discs (remember, disc herniations tend to be posterolateral)
- Ligamentum flavum - connects the lamina at each level
- Interspinous, Supraspinous

### Other things to know:

- The Denis “three column” theory of spine stability
- Composition and anatomy of intervertebral discs
- Dermatomal map and nerve roots contributing to muscle function
- Differentiation of cervical radiculopathy from myelopathy
- Presentation of cauda equina syndrome, a surgical emergency
- Radiographic and lab abnormalities seen in spine infections, e.g. osteomyelitis, discitis, epidural abscess
- Spinal cord injury

### Rounding Tips

The Spine service is usually rounding-heavy. You can be of help to the team by coming in early to print out the service list, recording what POD# the patient is, the procedure that was done, recording any abnormal vital signs (especially temperature >38.5) or lab values, as well as any drain output (record as amount in last 24hr / last 8 hr). Make a copy of this list for all members of your team prior to their arrival to rounds. You should always round with the following: trauma shears, 4x4 gauze, medium and large covaderm strips.

### Clinic

Spine clinic is on the 3rd floor of the 415 building at Fontaine Research Park. Clinic is usually fairly busy and can get a little hectic if the team falls behind schedule. As a student, it's important to remain aware of these circumstances and avoid negatively impacting the efficient operation of the team. Generally, a nurse will bring a patient's folder into the central conference room. At that time, it's appropriate to find out who the patient is, what they're in clinic for (initial visit, post-surgical follow-up, etc.) and ask your resident or attending if they would be good for you to see. In Spine clinic, there is a healthy mixture of interesting pathologies and exam findings with not-so-interesting ones (chronic lower back pain, workers compensation, and DDD). As a student, try to maximize your time with the interesting patients. Not only is it good for learning purposes, but your attending will generally pay more attention to your presentation you are interested in the patient.

For the purposes of your H&P for initial visits, the following points are important to collect:

- Acuity/duration of symptoms, quality of pain, radiation, palliative factors attempted, prior imaging or surgeries performed.

- You should (with few exceptions) ask your patients about “red flag” symptoms. There’s nothing worse than a patient having recent onset bowel/bladder dysfunction that you missed. This is especially important for initial visits, as your thorough history can help the attending decide what imaging modalities may be appropriate to pursue. Commit these “red flags” to memory: infection [new onset of LBP with fever, chills, night sweats, history of intravenous drug use, recent infection], cancer [new onset pain with history of cancer, multiple risk factors for cancer, age >50, unexplained weight loss], significant trauma [MVC], cauda equina syndrome [new urinary retention, fecal incontinence, saddle anesthesia], and severe or progressive neurologic symptoms [progressive motor weakness or motor deficits at multiple neurologic levels].
- Your physical exam should include thorough neurologic (reflexes, sensation) and motor (ROM, strength) exams, as well as any special maneuvers that are appropriate (Spurling test, Hoffman’s sign, Kemp sign, Lhermitte Sign, etc. YouTube these if they’re unclear!) and gait analysis.

Always have the most recent images available on PACS up and ready to be viewed when the attending comes into the room. HINT: If time allows, try to review these images yourself prior to hearing the attending’s interpretation or reading the radiology report. This practice will really help your ability to interpret and understand your anatomy! Try to correlate your physical exam findings with the patient’s imaging. When presenting an initial visit, focus on a few of the most pertinent positives and negatives in their history. Try to consolidate your physical exam into as few descriptive words as possible. For instance, instead of saying “the patient had 5/5 strength in hip flexion and adduction, 5/5 strength with hip abduction and extension, 4/5 strength in knee extension, 5/5 ankle dorsiflexion and plantar flexion, 5/5 ankle inversion, with diminished sensation to light touch in the lateral thigh, anterior knee and medial lower leg,” you can carefully summarize by saying “5/5 strength throughout the lower extremity with the exception of 4/5 strength with knee extension, sensation diminished to light touch in L4 distribution.” The latter is much more concise but equally as descriptive, and the team will appreciate your brevity. For post-surgical follow-ups, start your presentation by saying “Mr/Ms. \_\_, is a \_\_ year old (M/F) who is \_\_ weeks/months s/p \_(procedure)\_\_\_.” Then proceed to describe any changes in symptoms, physical exam findings, or imaging, as appropriate.

## SPORTS MEDICINE

### **Overview**

Originally developed to provide specialized care to highly competitive athletes, Sports Medicine has now evolved into a field that encompasses a broad range of pathologies primarily involving the knee and shoulder, but also the hip, ankle, and elbow. At UVA, we are fortunate to have nationally and internationally recognized faculty who provide specialized care ranging from simple to highly complex cases referred from all regions.

As a student on this service, you will have ample opportunity to scrub in on cases with each attending. A vast majority of the surgical cases are done in the Outpatient Surgery Center (OPSC, pronounced “OP” “see”) at 500 Monroe Lane, the building behind the South Parking Garage. However, this location will be changed upon completion of the Battle Building.

In general, you will be expected to help out in clinic 1-2 days per week, as designated by your residents. Clinic is located at the 515 Ray C. Hunt Drive Building in Fontaine Research Park. It may be easiest to try to get a ride from your resident, as some students in the past have gotten ticketed for parking in the visitor spaces. Another option is the Fontaine Shuttle, which reliably runs from 08:00-17:40.

### **Suggested Reading**

Current Diagnosis and Treatment in Orthopedics. Chapter 4: Sports Medicine. Available as ebook on HSL website.

Hart, Jennifer, Miller, Mark D., Thompson, Stephen R. Review of Orthopaedics, 6th Edition. Elsevier Inc. 2012.

- with special focus on “Anatomy” chapter: Section II. Shoulder and Section IV Knee and Leg

Campbell’s Operative Orthopaedics Volume III, Part XIV Chapter 51: Arthroscopy of the Lower Extremity and Chapter 52: Arthroscopy of the Upper Extremity  
Available as ebook on HSL website.

### **Division Structure**

		
<b>Mark D. Miller, MD</b>	<b>David R. Diduch, MD</b>	<b>Brian C. Werner, MD</b>
S. Ward Casscells Professor of Orthopaedic Surgery Associate Team Physician, James Madison University	Professor of Orthopaedic Surgery Division Head University of Virginia Head Team Physician	Assistant Professor of Orthopaedic Surgery Team Physician, James Madison University

	
<b>Stephen F. Brockmeier, MD</b>	<b>F. Winston Gwathmey, MD</b>
Associate Professor of Orthopaedic Surgery Director, Sports Medicine Fellowship Program University of Virginia & JMU	Associate Professor of Orthopaedic Surgery Residency Director University of Virginia Associate Team Physician James Madison University

Associate Team Physician	Associate Team Physician
--------------------------	--------------------------

Jennifer A. Hart, MPAS, ATC, Physician Assistant, Administrative Chief

Shelly Post, PA-C, Physician Assistant

Claire Denny, MPAS, Physician Assistant

Sports Medicine Fellows (3)

PGY-5 Chief Resident

PGY-3 Mid-Level Resident

PGY-2 Junior Resident

## Conditions Frequently Seen

### Knee

#### Meniscal Pathology

- Anatomy/Pathogenesis
  - Medial tears more common than lateral, being more mobile, except in association with acute ACL tears where the lateral meniscus is more commonly involved
  - Blood supply = medial/lateral inferior geniculate arteries
- Symptoms/Physical Exam
  - Mechanical symptoms of catching/locking/clicking +/- joint effusion, pain. McMurray Test positive.
- Treatment - varies depending on type of tear
  - Degenerative tear: NSAIDs, conservative therapy
  - Vertical or longitudinal tears may be amenable to meniscal repair (vertical mattress inside-out technique is gold standard)
  - Other tears: partial meniscectomy (most common procedure in all of orthopaedics)

#### ACL Rupture (Primary and Re-rupture)

- Anatomy/Pathogenesis:
  - Primary function: provides 85% of the stability to prevent anterior tibial translation, secondary restraint to tibial rotation and varus/valgus rotation
  - Anteromedial bundle (tight in flexion) and posterolateral bundle (tight in extension - greater rotational stability)
  - Blood supply: middle geniculate artery
- Symptoms/Physical Exam
  - History of “pop” with immediate pain/swelling. Positive Lachman test and Pivot shift test
    - Tip: as a beginner, it can be difficult to elicit these positive signs in clinic due to patient guarding. You can get great practice with these exam maneuvers under anesthesia in the OR before the patient gets draped. Don’t be afraid to ask!

- Treatment
  - Surgical reconstruction technique most commonly done at UVA is using a bone-patellar tendon-bone autograft or hamstring autograft (composed of both Gracilis and Semitendinosus tendons). Separate femoral and tibial tunnels are drilled (in contrast to the trans-tibial approach) utilizing an accessory medial portal for the femoral tunnel in order to better recreate the anatomic footprint of the original ACL.

## Shoulder

### Rotator Cuff Tear

- Anatomy/Pathogenesis
  - Rotator cuff pathology is a continuum of disease: subacromial impingement -> tendinopathy -> partial tear -> full-thickness tear -> massive tear -> rotator cuff arthropathy
  - Mechanism: chronic degenerative (older pt) or acute (s/p fall, shoulder dislocation, throwing athletes)
  - Generally in older patients.
- Symptoms/Physical Exam
  - Pain with overhead activities, **nighttime pain**
  - Assess any differences in passive ROM. Use special exam maneuvers below

Muscle Being Tested	Special Tests	Strength Testing
Supraspinatus	Empty Can test Drop Arm test	Weakness to resisted elevation in empty can position
Infraspinatus	ER lag sign	ER weakness with arm at side
Teres Minor	Hornblowers sign	ER weakness with arm at 90 deg abduction and 90 deg ER
Subscapularis	Belly Compression test Liftoff Test IR lag sign	IR weakness with arm at side

- Diagnosis
  - MRI is diagnostic. However, must correlate with physical exam findings, as many older patients will have an asymptomatic rotator cuff tear
    - Tear is classified based on size
      - Small: <1cm
      - Medium: 1-3cm
      - Large: 3-5cm
      - Massive: >5cm
  - Ultrasound can also be (but rarely is) used with similar sensitivity/specificity to MRI



- Treatment
  - Conservative modalities (NSAIDs, physical therapy, steroid injections) can be used with some efficacy, especially with partial tears, chronic atraumatic tears, and in noncompliant patients
  - Arthroscopic rotator cuff repair - early repair indicated in acute setting
    - Read about double-row and suture-bridge fixation techniques

## Shoulder Instability

- Anatomy/Pathogenesis:
  - Know the musculoligamentous anatomy of the shoulder, with special attention to the anterior stabilizers (anterior band of the IGHL, MGHL, and SGHL).
  - Anterior shoulder dislocations are by far the most common. Mechanism is often a posteriorly directed force on an abducted and externally rotated arm.
    - TUBS = Traumatic Unilateral dislocation with a Bankart lesion requiring Surgery.
      - Bankart Lesion – avulsion of the anterior band of the IGHL.
      - Associated bone defects:
        - Hill Sachs defect – impaction of the posterosuperior humeral head on the glenoid rim after dislocation.
        - Bony Bankart lesion – fracture of anterior inferior glenoid often associated with recurrent dislocations.
    - AMBRI = Atraumatic Multidirectional Bilateral shoulder dislocation that responds to Rehab and occasionally an Inferior capsular shift.
- Symptoms/Physical Exam
  - Shoulder pain and feelings of instability.
  - Specific tests: apprehension sign, load-and-shift test, sulcus sign.
  - Be aware of the potential for axillary nerve injury with anterior dislocations.
- Diagnosis
  - Based off history and physical exam.
  - Radiographs are useful for acute evaluation of humeral head position (true AP, scapular-Y, and axillary). Stryker view is sensitive for Hill-Sachs lesions.
  - MRI is needed for visualization of labral tear and surgical planning.
- Treatment
  - Complex algorithm based off the patient's age, number of recurrences, athletic status, and associated injuries.
  - Early age of initial dislocation is a risk factor for recurrent instability.

## Glenohumeral Arthritis and Rotator Cuff Arthropathy

- Mechanical wear of bone in OA causes the glenoid to become retroverted (normal anatomic alignment is slight anteversion), resulting in posterior displacement of the humeral head
- Osteophytes around the inferior humeral head or glenoid
- Loss of glenohumeral articular cartilage can result chronic rotator cuff tears, leading to abrasion of the unprotected humeral head against the coracoacromial arch

- Rotator Cuff Arthropathy = arthritis + chronic rotator cuff dysfunction
  - Anatomy/Pathogenesis:
    - Superior translation of the humeral head
      - Proximal humeral convexity = radius of the humeral head + the thickness of the rotator cuff tendons
      - Rotator cuff deficiency decreases the proximal humeral convexity by the thickness of the tendon
      - The loss of the cuff tendon leads to superior translation via the active pull of the deltoid
      - Eventually, the coracoacromial arch becomes compromised (secondary to the chronic abrasion with the humeral head) and loses its ability to serve as a secondary restraint. The resulting anterosuperior escape of the humeral head eliminates the ability of the deltoid to act as a fulcrum to elevate the arm. This is termed pseudoparalysis.
    - Loss of glenoid concavity secondary to a compression effect
    - Instability with loss of anterior restraints
  - Symptoms/Physical Exam:
    - Elderly patient with a history of progressive increases in pain, loss of strength and inability to perform activities of daily living
    - Determine any contributing historical factors that may have led to a massive atraumatic cuff deficiency (ie systemic disease, steroid injections, antimetabolic meds, smoking)
    - Chronic cuff tear often leads to muscle atrophy of the deficient tendons
    - Subacromial crepitus +/- effusion
    - Superior instability can be elicited by having patient actively contract the deltoid while watching for superior migration of humeral head into coracoacromial arch
    - Provocative maneuvers for rotator cuff pathology noted in above section
  - Diagnosis
    - Three radiographic views of shoulder (AP, true AP [aka Grashey], and axillary)
      - “Femoralization” of the proximal humerus
        - tuberosities get rounded off and proximal humerus becomes spherical
      - “Acetabularization” of the acromion-glenoid space
        - concavity becomes sculpted to match the femoralized proximal humerus
      - Anterosuperior escape
      - “Snowcap sign” secondary to subchondral sclerosis
      - Axillary view important to determine amount of glenoid stock remaining
    - MRI is not necessary for diagnosis, but may help in determining condition of

### rotator cuff

- Treatment
  - Nonoperative management - physical therapy and activity modification
    - Useful for chronic cuff tears and/or poor surgical candidates
  - Hemiarthroplasty
    - Indicated in younger patients with an intact coracoacromial arch and anterior deltoid
  - Total Arthroplasty = glenoid resurfacing + humeral head replacement
    - Rotator cuff must be intact and functional
    - Indicated when glenoid chondral surface wear prohibits activities of daily living
    - Preferred for isolated osteoarthritis or inflammatory arthritis of the shoulder
  - Reverse Arthroplasty - The “ball and socket” of the anatomic shoulder is, well, reversed!
    - Procedure of choice in rotator cuff arthropathy
    - Eccentric loading on the superior glenoid would cause rapid failure of the implant if the glenoid is resurfaced (as in a total shoulder arthroplasty). Therefore, this type of shoulder arthroplasty is contraindicated in rotator cuff deficient patients.

## Hip

### Femoroacetabular Impingement (FAI)

- Anatomy/Pathogenesis
  - Chronic chondral damage and hip symptoms secondary to abnormal contact between the proximal femur and acetabulum.
  - Types:
    - Cam – Disorder of the femoral head and neck anatomy resulting in decreased sphericity, offset, head-to-neck ratio and increased femoral neck retroversion.
    - Pincer – Disorder of the acetabular anatomy resulting in an overhanging anterosuperior acetabular rim, decreased anteversion or acetabular protrusio.
  - Associated with labral degeneration and tears, as well as osteoarthritis.
- Symptoms/Physical Exam
  - Limited range of motion in flexion and internal rotation.
  - Persistent groin, hip, or gluteal pain.
  - Positive anterior impingement test (passive hip flexion, adduction and internal rotation results in symptoms).
- Diagnosis
  - Radiographic evaluation to include AP and true lateral of pelvis
    - False profile view can evaluate anterior coverage of the femoral head.

- Pistol grip deformity = Cam impingement.
  - Crossover sign = Pincer impingement.
- MRI is useful for evaluating associated cartilage defects, labral tears and degeneration.
- Treatment
  - Options vary according to the type of impingement present, degree of osteoarthritis, and presence of associated labral pathology. Treatment includes arthroscopic or open procedures that address the bony abnormalities (femoral or periacetabular osteotomies), and labral repair or debridement.

## **Anatomy**

A detailed knowledge of the anatomy of the knee and shoulder is a must in this rotation. Because of the large number of cases that are done either entirely or partially arthroscopically, it will be important for you to be comfortable with what you're looking at on the monitor. YouTube and VuMedi are reasonable places to start viewing these images so that you can be comfortable with your anatomy before entering the OR. View "10 Point Shoulder Arthroscopy" and "Knee Arthroscopy: Portal placement and examination course" to get a basic orientation to diagnostic arthroscopy of normal joints.

It is also important to know your surgical approaches to the knee and shoulder. Commonly asked questions include identifying structures at risk during these approaches or portal placement. Consult the "Orthopedic Surgical Approaches" textbook for a good layer-by-layer anatomical reference.

## **Other things to know:**

- Types of grafts for ligament reconstruction, and their pros/cons. Autograft (bone-patellar tendon-bone, hamstring) vs. allograft (BTB, hamstring, achilles, tibialis anterior). Gracilis tendon is superior to the semitendinosus at its pes anserine insertion on the tibia.
- Muscles of pes anserinus and their innervations
- Layers of the medial and lateral knee
- Anatomy of the posterolateral corner
- When studying what nerve structures are at risk, know what they innervate, the deficits that would result from damaging them, how the patient would present clinically
- Indications for Total Shoulder Arthroplasty (TSA) and Reverse TSA (rotator cuff arthropathy, four-part proximal humerus fractures, failed TSA with massive cuff tear)
- Hip arthroscopy, Femoro-Acetabular Impingement (FAI), other Sports Hip pathology

## **Rounding Tips**

Because most of the procedures are done on an outpatient basis, there often is little rounding to be done on this service. However, Dr. Brockmeier's and Dr. Werner's TSA patients as well as patients

undergoing more complicated procedures done in the main OR will stay overnight as inpatients. If you were involved in the case, help with the post-op check as well as any rounding requirements the next morning. When pre-rounding, you can be helpful to the team by printing out the sports patient list, recording their POD#, the procedure performed, any important vitals (especially temperature) or lab values (WBC), and noting significant pain by going to the 'doc flowsheet' under 'pain rating'. If the patient recorded 10/10 pain all night, it will probably be worth noting. Use the copy machine at the central nursing station to make copies of your completed list for the team. You will round with the junior or mid-level resident.

## Clinic

Because of the large volume of patients that are referred to UVA Sports Medicine physicians, clinic is generally very busy. As a student, it's important to be aware of this pace and focus on being helpful without slowing the flow of clinic, while still learning some great orthopedics. You'll see a mixture of both post-op follow-ups and initial visits. For post-op patients, focus your interview on eliciting: pain or swelling, functional activity, whether they're doing PT, etc. Do not do any aggressive ROM maneuvers on early post-op visits, to avoid pulling out the repairs. If uncertain, be sure to check with your resident before the patient encounter to make sure you don't do any physical exam maneuvers that will harm the patient. For example, some post-op shoulder patients will be prohibited from active ROM for 6 weeks, therefore you must guide them passively to determine ROM while supine. It is also important that you pull up any relevant images on PACS or in the "Media" file of Epic before the attending comes in. They may want to know some basic details about the procedure that was performed (if it was a small or large cuff repair, what type of graft was used, etc). You won't be expected to know the minutiae, but have some understanding of what the surgery entailed. There will be scribes who take notes while the attending is in the room, and they are integral to the flow of clinic, so help them with details on physical exam, history, etc. as much as possible.

For initial visits it will also be important to pull up any relevant imaging, in addition to a getting a concise H&P. Important points to remember for your physical exam are: observation/palpation, passive/active ROM (know the normal ranges!), strength, special exam maneuvers. It is recommended that you have a good working knowledge of the important exam maneuvers, how to perform them, and what they're testing for before clinic. YouTube is a great resource for learning these techniques (Physical Therapy Haven channel is a good place to start). When presenting to an attending, your ability to be brief/concise is key. Provide a few key history points and comment on any important findings on imaging, clinical ROM, and one or two pertinent special maneuvers that may aid in the diagnosis.

## TRAUMA

### **Overview**

Orthopaedic Trauma focuses on the definitive treatment of serious injuries. Cases range from isolated fractures to multi-trauma victims with damage to multiple bones or organ systems. Long bones, the pelvic girdle, and major joints comprise most of the surgeries, as they often receive the brunt of the trauma. The majority of patients are first seen in the setting of an emergency room, and a significant percentage of those patients require timely surgical intervention. Other times, a patient receives stabilizing measures in the emergent setting and undergoes definitive repair electively.

Trauma surgery poses unique challenges in every case and thus there is emphasis on improvisation. Although endless classification systems attempt to stratify severity and management, no two fractures are the same, and each repair demands a unique solution. X-rays and CT scans give the surgeon an excellent start, but sometimes the right method of repair is not evident until a fracture is exposed.

As a student on this service, you will see most major areas of orthopaedic anatomy. Most operations focus on fractures, however it is essential to be familiar with the soft tissues surrounding the bony structures. You will benefit greatly by having portable sources for anatomy and fracture care, as some surgeries are scheduled urgently on the day of injury.

### **Suggested Reading**

Handbook of Fractures 4th Ed. Kenneth A. Egol. - an excellent, portable source for trauma ACE. \$60 on Amazon. You will need this as a resident.



Rockwood and Green's Fractures in Adults any edition. A comprehensive source that covers even the finest details of fracture management.

Available as ebook on hsl website and on reserve shelf in library.

For a good overview of fracture descriptions:

Radiology Tutorial Website

### **Division Structure**

		
<b>David Weiss, MD</b>	<b>Michael Hadeed, MD (COMING SOON after fellowship!)</b>	<b>Seth Yarboro, MD</b>
Associate Professor of Orthopaedic Surgery Division Head		Associate Professor of Orthopaedic Surgery Director Of Orthopaedic Quality

Jacqueline (Jacqui) Sedlock, P.A., Physician Assistant  
Jodi Wells, P.A., Physician Assistant

PGY-5 Chief Resident  
PGY-4 Senior Resident  
PGY-1 Intern

### **General Knowledge**

Learning the language of orthopaedic trauma is an absolute necessity. Trauma comprises the majority of injuries an orthopaedic surgeon will treat on call, regardless of the surgeon's particular expertise. Outside hospitals often refer their more complicated trauma cases. It is essential that you learn how to communicate the defining characteristics of a fracture so that the receiving party can organize treatment based on a brief conversation.

### Stages of Fracture Healing

1. Hematoma - usually contained within periosteum. Extravasation into soft tissue indicates periosteal tear. The hematoma is clinically useful as it is a easy target for injecting numbing agents

prior to fracture reduction.

2. Subperiosteal and Endosteal Proliferation - an immature, soft phase that lays cellular groundwork

3. Callus Formation - maturation of cellular structure into woven bone. First phase of healing visible on a radiograph and on exam will be a palpable hard bump over fracture site.

4. Consolidation - osteoblasts and osteoclasts transform woven bone into lamellar bone.

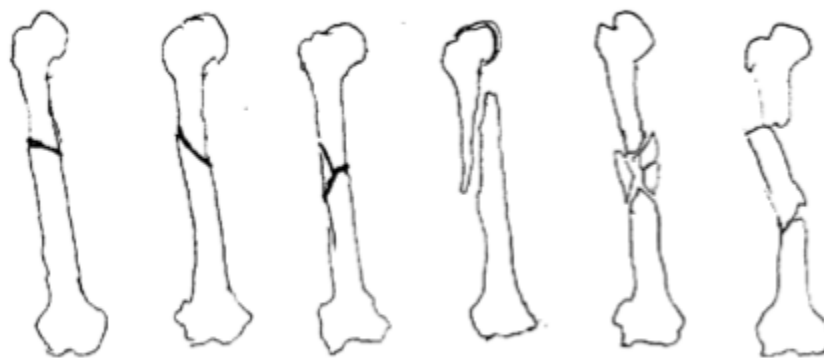5. Remodeling - longest phase; occurs under influence of stress forces. Surplus lamellar bone removed by osteoclasts. In children, remodeling is incredibly robust and often produces near perfect bone structure that is usually not apparent on radiographs later in life (adults often have residual sclerosis along fracture line).

### Fracture Patterns

The fracture pattern often predicts treatment, recovery outcome, and complications. The pattern is perhaps the most important aspect of an orthopaedic trauma once the patient is stabilized. Each pattern is the result of a particular set of forces and will shed a lot of light on the injury itself. In addition, many classification schemes apply parameters to these terms in order to guide treatment for a particular fracture (for example, surgery indicated when the fracture has  $> 1$  mm of shortening, etc). Always remember that an X-ray is only showing a snapshot of the fracture fragments. Knowledge of surrounding anatomy is essential to be able to predict the extent of soft tissue damage by looking only at the X-ray.

#### Basic Patterns

Transverse Oblique Butterfly Spiral Comminuted Segmental



Transverse = bending force, fracture angle less than 30 degrees to bone axis

Oblique = bending or shearing force, fracture angle over 30 degrees to bone axis

Butterfly = bending + rotational or compression combined force

Spiral = rotational force

Comminution = high energy force causing multiple fragments



Segmental = high energy with large distribution of force

Angulation = varus/valgus/anterior/posterior - refers to direction of **distal** fragment

- Another option is to describe the point of the angle: "apex \_\_"

Shortening = overlap of fragments that leads to loss of length

Displacement = side-to-side translational migration of a fragment

Rotation = fragments have twisted relative to each other

There is a section early in Rockwood and Green about the physics of a bone fracture. Highly recommended!

Video Link:

Classifying and Presenting Fractures - Dr. Syed Junaid

### Fracture Fixation

- Closed Reduction: manipulation followed by splints/casts, which serve to *maintain* a reduction more than creating the reduction itself.
- External Fixation: placement of pins/screws that are held in place by an external frame
- Internal Fixation: screws, plates, nails, etc. that provide stability independently
- Traction: used for temporary stabilization as bridge to definitive surgical treatment. Rarely used in US for definitive treatment due to consequences of long-term bedrest and cost of prolonged hospitalization.

"ORIF": open reduction internal fixation - comprises majority of surgeries and involves exposure of the fracture and direct visualization of the fixation.

"CRPP": closed reduction percutaneous pinning

"ORPP": open reduction and percutaneous pinning

"CRIF": closed reduction and percutaneous screw fixation

Lag screw - interfragmentary compression (neutralization plate needed for stabilization of force):

- Wider drill bit is first used through near cortex and up to fracture, followed by a narrower drill bit through the far cortex. Threads lock into far cortex only and compress fragments together.
- A neutralization plate can be placed after lag screw interfragmentary fixation.

Positioning screw - compress plate to bone

Locking screw - see locking plate

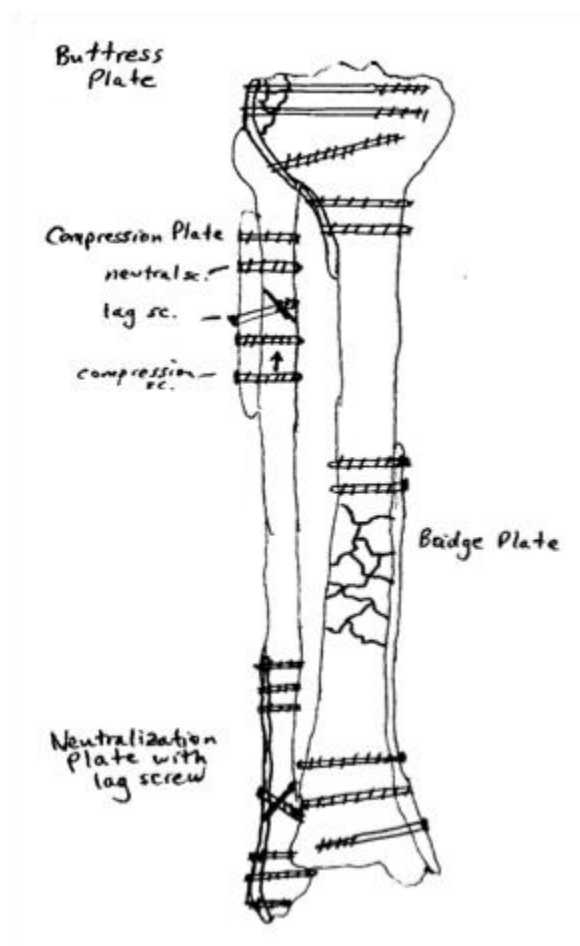
Compression plate - absolute stability; relies on friction

Bridge plate - comminuted fractures, no screws placed within comminution

Buttress plate - provides stability at 90 degrees to fracture line by preventing fracture from shearing and displacing further

Locking plate - fixes fracture in place at position of reduction; screw heads are threaded and screw

into the plate itself. Locking fixation does not compress the fracture but adds significant fixed-angle rigidity to the fracture stabilization. Commonly used for periprosthetic, proximal humerus, distal humerus, distal femur, and other peri-articular fractures.



### Intramedullary Nails

- Most common method of fixation for fractures of long bones, particularly tibial and femoral shaft
- Indicated for select humeral shaft fractures, such as pathologic fractures
- Interlocking screws provide rotational stability and maintain bone length
- Be familiar with anterograde versus retrograde approaches to nail placement
- Nailing is minimally invasive and allows early weight bearing for some fracture patterns

- Anatomic Reduction: exact restoration of fragment position to pre-fracture state. Attempted for fractures extending into the articular surface to prevent traumatic arthropathy.

- Approximate Reduction: for many fractures, anatomic reduction is not required and only certain parameters are restored (length, angulation, rotation, displacement etc.)

Nondisplaced/Minimally Displaced: do not require reduction. Cast or splint can be applied to protect fracture position and alleviate pain.

### Gustilo and Anderson Classification of Open Fractures (VERY IMPORTANT)

\*Soft tissue damage and energy of trauma are the most important features of an open fracture.

Wound size can be misleading.

Type I: low energy, wound <1cm

Type II: moderate energy, wound 1-10cm and without significant soft tissue stripping or gross contamination

Type IIIa: high energy, wound often >10cm, bone coverage is adequate

Type IIIb: extensive soft tissue stripping that requires a musculo-cutaneous tissue flap for adequate coverage

Type IIIc: major arterial injury (including any compromise proximal to wound) that will affect tissue viability

### Conditions Frequently Seen

- Fractures of long bone diaphyses and metaphyses - tibia, femur, and humerus
- Pelvic fractures
  - Be familiar with the Young-Burgess classification system for pelvic ring fractures
  - Management of acetabular fractures is complex, and the fracture type determines the approach to fixation
- Femoral neck and Intertrochanteric fractures
  - Know the Garden classification for femoral neck fractures
    - Neck fracture in a young patient (high-energy) requires emergent reduction and operative stabilization! You do not want an arthroplasty in a young patient! ORIF typically requires an open reduction followed by parallel screw fixation, but osteonecrosis can frequently occur, especially if there is a delay in fixation. In the elderly, fixation varies depending on Garden type (percutaneous screws vs. hemiarthroplasty vs. total hip arthroplasty)
  - Know the Evans classification for intertrochanteric fractures
    - Recognize unstable fracture patterns that will collapse into varus (reverse obliquity, posteromedial fragment, subtrochanteric fractures). These patterns will generally require a cephalomedullary nail rather than a sliding hip compression screw.
- Tibial Plateau fractures
  - Know the Schatzker classification system and basic operative indications
- Ankle and Pilon fractures
  - Be familiar with the Lauge-Hansen and Denis-Weber classification systems
  - Stress radiographs showing medial clear space widening >5mm implies a deltoid disruption and an unstable ankle
  - Treatment is highly dependent on injury pattern
- Fractures of Midfoot, Calcaneus, and Talus

### Preoperative Preparation (other than anatomy, anatomy, anatomy!)

As stated before, it can be difficult to prepare for many trauma surgeries. You simply won't always have the time. When in a hurry, focus on the following:

1. Pertinent patient info - including smoking status, handedness, and medical comorbidities (particularly those affecting wound healing), osteopenia/osteoporosis
2. Injury mechanism - you should be able to tell what happened to the patient in 2 sentences or less.
3. Connect the story to the imaging - when you look at a fracture, try to imagine what forces led to the mechanism of injury (ex: posterior acetabular wall blowout after a patient's knee went into dashboard, forcing the femoral head posteriorly and dislocating the hip).
4. Classify the fracture: realize that many fractures will not match the pictures in your book. Focus on the features distinguishing the classes. You should know the classification for a fracture you're about to help fix!
5. Try to predict what method of fixation the team will attempt. You'll come up with much better questions when you've gone through the thought process yourself. In every case, you should think about why the surgery is indicated.
6. If you have more time, look up what structures are at risk from both the injury and the repair. Nerves are more commonly injured, but certain cases involve vascular risks. If you know what you are looking for, you'll be ready for common pimping questions and can provide better post-operative exam findings.

### Rounding Tips

Have trauma shears with you at all times. No exceptions!

The Trauma service list varies from day to day, but it is usually a busy service. Keep good notes about your patients, as you may not see the same fracture twice. Similar to the Adult

Reconstruction service, you can help out by arriving early and printing out the list for the team. For your patients, keep up with all pertinent overnight events/labs and notes from other services.

Other services, such as Trauma Surgery, Plastic Surgery, Vascular Surgery, and Infectious Diseases will commonly be involved in the multidisciplinary care of the Trauma patient. If a patient is admitted overnight, spend a few minutes getting the story and taking a glance at the imaging. If any patient needs a dressing change, be ready with all necessary supplies or ask to do it yourself (don't do it without asking - a resident needs to inspect the wound). Your responsibility will vary from chief to chief. Establish expectations the first morning.

Immediate postoperative care and potential complications depend a lot on the fracture. Pain, compartment syndrome, infection, and DVT are your major concerns. Remember to check vitals, blood counts, and signs of active bleeding (drain output if applicable).

Special note: Be very mindful that your patients have experienced a significant injury that they did not expect. Your patients will come from all walks of life and have a range of personalities and reactions to stress. Some may be very grateful for your care, but others may be belligerent and enraged for unclear reasons. You will see that a lot of orthopaedic trauma is the result of careless

behavior. Maintain polite professionalism and focus on providing the best care possible while casting judgments aside.

## Clinic

Orthopaedic Trauma clinic is located in the 515 Ray C. Hunt Drive Fontaine building. Expect to spend one or two days per week in clinic. There will usually be just one attending for any given day or clinic, so talk to your resident about which days would be most helpful for you to be present. Trauma clinic revolves around postoperative care and monitoring of fixation. You will get a great exposure to the various stages of fracture healing and see several ways to go about treating a fracture. For every patient you see, ask yourself why that particular intervention was chosen. A cool part about trauma is that patients often have interesting, amusing stories to go along with their injury. Being able to associate a story with an injury helps cement your understanding of how particular fractures occur. Lastly, remember that the priority is preservation of function and minimization of long-term pain. Certain bones and fractures are straightforward, whereas others are exceedingly difficult and require long-term care or multiple surgeries.

When you present a patient:

- summarize the injury (date, mechanism)
- describe the original fracture (ok to use a classification if you know what the classification is, but it's perfectly fine to describe it in your own words)
- summarize the intervention(s) to date (date of surgery, if applicable)
- describe how the patient is doing now (pain is usually the primary complaint, so localize and focus on the source of the pain) and what medications they are taking (pain medications and/or antibiotics)
- interpret the most recent X-rays (include a description of the hardware too!)
- include any relevant exam findings, but keep this very short if there is nothing abnormal
- appearance of wound, signs of infection, motor/sensory deficits, etc.
- if the patient is getting therapy, describe the course (frequency, improvements in ROM and strength, etc.)

This may sound like a lot, but it will become second nature and take only a few moments. Use Trauma clinic to perfect your presentation of fractures, as this skill will help you while on call. You'll find that the focus of your presentation increasingly becomes the X-ray, coupled with a patient's pain and function.

## REFERENCES

### **Helpful Resources and Book Recommendations**

1. Review of Orthopaedics - Mark Miller, MD
2. Surgical Exposures in Orthopaedics: The Anatomic Approach - Stanley Hoppenfeld
3. Orthopaedic Surgical Exposures - Miller, Chhabra, Shen
4. Netter's Concise Orthopaedic Anatomy
5. Handbook of Fractures - Koval/Zuckerman
6. Online Resources
  - a. Wheelless Online
  - b. OrthoBullets.com
  - c. YouTube has a seemingly endless supply of good videos (you can even preview some procedures beforehand!)
  - d. PubMed - highly recommended for a more advanced understanding of any topic, and useful for literature searches for presentations
7. Journal of the American Academy of Orthopaedic Surgeons (JAAOS) – the “Yellow Journal” containing excellent detailed reviews of hundreds of topics in orthopaedics. Online: [www.jaaos.org](http://www.jaaos.org).
8. Link to GWU recommended reading list (by division)  
<http://www.gwumc.edu/smhs/orthopaedic-surgery/residency/reading-list.html>
9. *The Residents at UVA* – often your most important resource! Never hesitate to ask questions, whether it is about basic anatomy or about career-based preparations if your path is Orthopaedic Surgery!

The Claude Memorial Health Science Library is accessible to all medical students and is connected to the hospital. A wide variety of electronic resources such as electronic journals (JBJS, JAAOS), full texts (Campbell's Operative Orthopaedics, Surgical Trauma, etc) online are available through the hospital computer system.