

ORTHOPAEDIC JOURNAL



RESIDENT
RESEARCH

DIVISIONAL
REPORTS

VISITING
PROFESSORS

UPDATE: UVA
ORTHOPEDIC CENTER

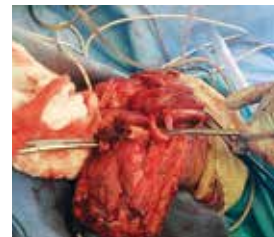DEPARTMENT
SPOTLIGHT

CONTENTS

University of Virginia Orthopaedic Journal | 2022

3

MESSAGE
FROM THE CHAIR
A. Bobby Chhabra, MD



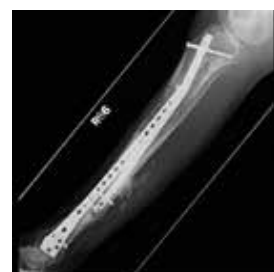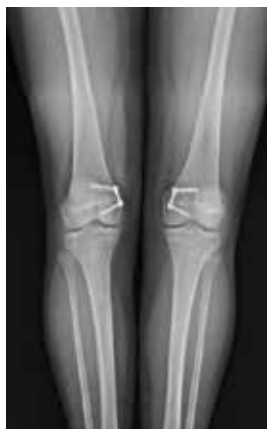4

NOW OPEN
UVA Orthopedic Center
Ivy Road Will Be a Hub
for Comprehensive
Orthopaedic Care

9

DIVISIONAL CASE
REPORTS AND
TECHNICAL TRICKS

- 10 Adult Reconstruction
 - 15 Foot & Ankle
 - 20 Hand & Upper Extremity
 - 25 Oncology
 - 26 Pediatrics
 - 30 Prosthetics & Orthotics
 - 32 Research
 - 35 Spine
 - 43 Sports Medicine
 - 47 Trauma
 - 53 Physician's Assistants
 - 54 Fellows
 - 55 Residents
-



8

OFF THE BEATEN PATH
Take Care of Yourself



56

RESIDENT RESEARCH
DAY ABSTRACTS
Groundbreaking Research
and Advancements in
Orthopaedic Surgery

62

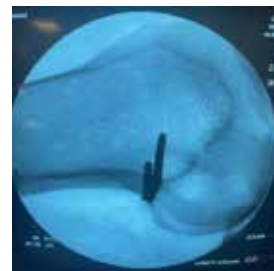
DEPARTMENT
SPOTLIGHT
Highlighting the
Accomplishments,
Recent Growth, and
Prominent Physicians in
the Department

76

2 MINUTE CONSULT
Test Your Knowledge

77

PHILANTHROPY
Help Make Great
Orthopaedic Care
at UVA Even Better



UVA Department of Orthopaedic Surgery

A. Bobby Chhabra, MD

Chair of the Department | Lillian T. Pratt Distinguished Professor | David Harrison Distinguished Educator | UVA Orthopedic Center Director

ADULT RECONSTRUCTION

Thomas E. Brown, MD

Associate Professor

James A. Browne, MD*

*Alfred R. Shands Professor and
Vice Chair for Clinical Operations*

Quanjun Cui, MD

*Gwo-Jaw Wang Professor and
Vice Chair for Research*

Ian M. Duensing, MD

Assistant Professor

FOOT AND ANKLE

M. Truitt Cooper, MD

Associate Professor

Shepard Hurwitz, MD

Professor Emeritus

Joseph S. Park, MD*

Associate Professor

Venkat Perumal, MD

Assistant Professor

HAND AND UPPER EXTREMITY

A. Bobby Chhabra, MD

Lillian T. Pratt Distinguished Professor and Chair

A. Rashard Dacus, MD*

*Associate Professor and
Vice Chair for Diversity, Inclusion & Wellness*

D. Nicole Deal, MD

Professor

Aaron M. Freilich, MD

Associate Professor

ONCOLOGY

Gregory Domson, MD

Professor

PEDIATRICS

Mark F. Abel, MD

Charles J. Frankel Professor Emeritus

Keith R. Bachmann, MD

*Assistant Professor and
Associate Residency Director*

Leigh Ann Lather, MD

Associate Professor

Mark J. Romness, MD*

Associate Professor

PROSTHETICS & ORTHOTICS

Michele Bryant, CO*

Technical Director

RESEARCH

George J. Christ, PhD

Professor

Wendy Novicoff, PhD

Professor

Shawn D. Russell, PhD

Associate Professor

SPINE

Xudong (Joshua) Li, MD, PhD

Associate Professor

Francis H. Shen, MD*

*Warren G. Stamp Professor
Vice Chair for Faculty Development*

Adam L. Shimer, MD

Associate Professor

Anuj Singla, MD

Associate Professor

SPORTS MEDICINE

Stephen F. Brockmeier, MD

Professor

David R. Diduch, MD*

Allen F. Voshell Professor

F. Winston Gwathmey, MD

*Associate Professor and
Vice Chair for Education & Residency Program Director*

Mark D. Miller, MD

S. Ward Casscells Professor

Brian C. Werner, MD

Associate Professor

TRAUMA

Michael M. Hadeed, MD

Assistant Professor

David B. Weiss, MD*

Associate Professor

Seth R. Yarboro, MD

Associate Professor

* Division Head



Dear UVA Orthopaedic Alumni:

This past July, I began my 9th year as the Chair of the Department of Orthopaedic Surgery at the University of Virginia. As many of you know, I have spent my entire career here at UVA, beginning as a medical student in 1991. It is a tremendous honor to continue to build on the foundation of my predecessors who helped create one of the top Orthopaedic programs in the country. UVA Orthopaedics has changed dramatically, and we have experienced unprecedented growth. I am excited to share our progress in this third issue of a journal that will be published on a regular basis.

The biggest news I would like to share is the opening of the new UVA Orthopedic Center Ivy Road. This state of the art, comprehensive Orthopaedic facility opened in January 2022 for patient care. This 195,000 sq. foot new home for UVA Orthopaedics has been in development for 10 years and will be one of the best in the country for patient care and patient, provider, and team member experience with an innovative education center for our community, residents and fellows.

UVA Orthopaedics continues to be the busiest surgical service at the UVA Medical Center, and we have increased our clinical footprint with locations east and north of Charlottesville. We recorded 110,000 patient visits and performed 8,900 surgeries in fiscal year 2021 despite the COVID-19 pandemic, compared to 69,000 patient visits and 6,800 surgeries just nine years ago. Our faculty size has increased to 30 clinical faculty and 6 research faculty. We have 16 very talented Physician Assistants who help optimize our patient care and access. For the last four years, we have surpassed institutional quality metric and patient satisfaction goals and performed better than all other service lines at the UVA Medical Center. For seven years in a row, UVA Orthopaedics has been ranked one of the top 100 Orthopaedic programs in the country in *Becker's Hospital Review* and has consistently ranked in the top 10% of programs in the country in *U.S. News & World Report*.

We are in the midst of dramatic changes in how healthcare will be provided nationally due to the consequences of the COVID-19 pandemic. I am fortunate to have a group of faculty and team members who are resilient and determined to provide the best patient care possible despite the pressures we are experiencing. I have challenged our faculty to continue to advance orthopaedic care while responding to increasing competition, declining reimbursement, and increasing focus on the cost, value, and quality measures of patient care. We are well positioned to be one of the leading Orthopaedic programs in the country during this tumultuous and uncertain time.

In addition to the changing clinical care paradigm, our educational model has changed substantially over the last several years. With duty hour restrictions and the need to improve surgical outcomes and patient safety, we have created innovative methods to educate our residents and fellows. We have successfully implemented a surgical simulation and cadaver dissection curriculum. Our Orthopaedic residency is one of the most competitive programs in the country and was recently ranked in the top 20 by *Doximity*. This year we received over 1100 applications for our 5 intern positions. Our residency complement is 25 total residents (5 residents/year), and we now have 9 fellowship positions in 5 different specialties. Under the direction of our very talented residency and fellowships directors, we are constantly modifying and improving our teaching methods and curriculum to ensure that we continue to produce the most skilled Orthopaedic surgeons in the country. The new UVA Orthopedic Center will enhance our ability to provide a world class education. You, our loyal alumni, have allowed us to find ways to support these new educational endeavors with your generous donations.

Coupled with changes in patient care and education, the usual mechanisms of research support are becoming less reliable. Despite this, we have continued to grow in the area of musculoskeletal research. Our Orthopaedic Clinical Trials division has flourished and is one of the most productive in the UVA Health System. We are recognized internationally for our contributions to tissue engineering advances for musculoskeletal disease and have a very busy Human Performance and Motion Analysis laboratory. We have all the facilities and expertise in place to support a robust Orthopaedic translational research program, from bench to bedside.

I am thankful for the great faculty, residents, fellows, physician assistants, and staff that I work with every day. I am grateful to our loyal alumni who continue to support our department in so many ways through educational and research endowments.

I look forward to seeing many of you at our UVA Orthopaedic Alumni Reunion to celebrate the opening of the new UVA Orthopedic Center in the spring of 2022 and the UVA Orthopaedic Alumni Reception at the upcoming AAOS Annual Meeting in Chicago in March 2022.

Thank you again for your unwavering support of our department. Best wishes to you and your family and please stay safe and healthy.

Sincerely, Bobby Chhabra

Now Open

UVA ORTHOPEDIC CENTER IVY ROAD WILL BE A HUB FOR COMPREHENSIVE ORTHOPAEDIC CARE



Planning for this new orthopaedic center began in 2016. Thanks to the contributions of many, the first patients will walk through its doors by early 2022. Taking this project from ideation to groundbreaking was no easy feat. It has involved countless hours of discussion, decision-making, problem-solving, and planning by a core group of leaders. We're grateful to all the teams and donors who have made this building possible.

Story by Holly Ford; aerial photo by Whiting-Turner.





“Of course it was critical that we focus on the patient,” Chhabra says. “But unlike many care centers and facilities, we felt we also needed to create an environment that is provider-centric, where our team enjoys working. ...”

HIGHLIGHTS OF THE ORTHOPAEDIC CENTER IVY ROAD

Located on Ivy Road near the U.S. 29/U.S. 250 interchange, the 201,000-square-foot facility will feature:

- **8 outpatient clinics** – The joint replacement, sports medicine, orthopaedic trauma, orthopaedic oncology, hand, orthopaedic spine, foot and ankle, and prosthetics and orthotics clinics will be co-located into one facility for patient convenience, with associated specialties adjacent to each other to optimize clinical care, allow for provider proficiency and to encourage education.
- **On-site imaging** – X-rays will be located within the clinics; there will also be advanced imaging in the facility, including two MRIs, two fluoroscopy

More than a decade after planting the seed for the creation of a regional best-in-class orthopaedic and musculoskeletal facility, Chair of the UVA Department of Orthopaedic Surgery Bobby Chhabra, MD, is ever closer to seeing this vision become reality. The UVA Orthopaedic Center Ivy Road will open its doors in early 2022, with outpatient clinics opening first, followed by operating rooms later in the year.

“I first discussed the possibility of this center with Health System leadership in 2009. After some negotiation, we started architectural development in 2016, with BOV approval in 2017, and we broke ground in 2018,” says Chhabra. “When it opens in 2022, this facility will be one of just a handful across the country to provide the highest level of orthopaedic care across all specialties in one location. I’m really proud of this effort, the amount of time and attention to detail invested for our patients and for our team members who will provide care in this facility.”

There were approximately 50 different work groups involved in the initial planning phase of the project, from physicians and advanced practice providers to nurses, researchers, administrative staff and residents. Making the space patient-centric, with seamless access to all necessary services and amenities required for diagnosis, treatment and recovery, was a top priority. However, Chhabra says the planning team went a step further to ensure the environment also meets the needs of providers and all members of the team.

“Of course it was critical that we focus on the patient,” he says. “But unlike many care centers and facilities, we felt we also needed to create an environment that is provider-centric, where our team enjoys working. We need to recruit and retain the best — not only physicians, nurses and healthcare providers, but clinical researchers, residents, fellows and administrative staff. By creating a very clinically distinct, comprehensive facility and environment, UVA Orthopaedics will be in a position to draw the best talent locally and regionally, but also nationally.”



Photo Credit: John Sullivan, WT Superintendent at Ivy and happy Hand Center patient!!

suites, a standing CT and ultrasound.

- **6 operating rooms** – The operating rooms will have a stand-alone sterile processing department and nine high-end, post-recovery suites where families can stay after same-day or one-day joint replacement and sports surgeries. Anesthesia will be on-site, so pre-op assessment can be done in the same location as surgery.
- **A sports concussion facility** – Dedicated to ensuring accurate diagnosis and effective treatment of sports-related concussion, this is one of many services UVA Sports Medicine will offer at this new center to further its com-

mitment to provide high-level care for both high school and college athletes throughout Central Virginia.

- **Education center** – This center will house a conference room, as well as a simulation room for dry simulations and computer simulations, creating a focused educational environment for medical students, residents and fellows.
- **Therapy and wellness facility** – With one of the largest therapy gyms in the region, as well as lush outdoor spaces with miles of walking trails, the center will offer physical therapy and occupational therapy on site.
- **Integrated clinical research** – Re-

search teams are embedded within clinics to allow interested patients easy access to innovative treatment options.

- **Consumer amenities** – An on-site pharmacy and food services are added conveniences for patients and staff.

All outpatient orthopaedic care will be provided at the UVA Orthopaedic Center Ivy Road once clinics open early next year. Patients requiring an inpatient stay after surgery will be treated at UVA Medical Center. Across these two locations, UVA's fellowship-trained orthopaedic specialists will treat the full scope of orthopaedic problems, from common conditions to more complex, such as lower and upper extremity and pelvic traumas, revision joint replacement, sports and complex spine surgery.

“Orthopaedics has been one of the fastest growing specialties at UVA for the past 8 years,” says Chhabra. “This facility will allow us to expand to meet the growing demand in our community, state and region.” ■

Take Care of Yourself



By A. Rashard Dacus, MD

As providers, a lot of the last 18 months have been about taking care of the sick and those in need. We have taken extra steps to make sure our families were safe. Safe from disease, social unrest and financial distress. We have adjusted from normal routines to make things work. Providers have pivoted in an ever-changing landscape to do what we do best. Take care of patients. And while some have taken on new hobbies, started to exercise more and spent more time with family, many have basically put their heads down and worked. Hospital policy changes, OR backlogs/cancellations

and staff shortages have made the job stress level hit all-time highs.

It is no wonder people are leaving healthcare in large numbers. A recent study revealed that between 20% and 30% of front-line U.S. health-care workers are considering leaving their jobs. The number is even higher at 48% for ICU workers. And it's a global issue, with 1/3 of UK physicians stating that they plan on retiring early and 25% planning on taking a break from health-care. Extreme workloads, burnout from EMR and concern for the future are issues at the forefront.

There is no more important time than now to take care of yourself! Good emotional health is directly tied to a healthy immune system, which is pretty important

nowadays. It's a good time to reconnect with yourself. Here are a few ideas.

1. **Get some balance**
Make the enjoyment and the sacrifice equal
2. **Express your feelings and pay attention to your emotions**
Anger and resentment can eat you up
3. **Relax**
Take some alone time
4. **Get a checkup**
Your physical health should be a priority
5. **Follow through**
Make these things a part of your routine ■

Extreme workloads, burnout from EMR and concern for the future are issues at the forefront.

Linzer M, Visser MR, Oort FJ, Smets EM, McMurray JE, de Haes HC. Predicting and preventing physician burnout: Results from the United States and the Netherlands. *Am J Med.* 2021 Oct 1;111(2):170-175. doi: 10.1016/j.mayocp.2021.06.005.

Linzer M, Konrad TR, Douglas J, et al. Managed care, time pressure, and physician job satisfaction: Results from the physician worklife study. *J Gen Intern Med.* 2000 Jul;15(7):441-450. doi: 10.1046/j.1525-1497.2000.05239.x. (edited)



UVA Orthopaedics

BY DIVISION

The driving missions of our Department of Orthopaedic Surgery are to be national leaders in improving clinical care of orthopaedic conditions, in being innovators in educating residents who will become future leaders and to contribute impactful musculoskeletal research which will translate into the future treatments in our field. In pursuit of these goals, we strive always to provide state-of-the-art, comprehensive, but cost-effective care for all musculoskeletal, orthopaedic disorders. Our education curriculum is structured to evolve so as to provide updated, competency-based materials and a robust evaluation process. Researchers in Orthopaedics endeavor to make significant and sequential advancements in the science of musculoskeletal medicine using a multi-disciplinary, collaborative research approach which can inform the future practice of Orthopaedic Surgery.



*Division heads denoted with an **



Thomas E. Brown, MD

Associate Professor

Dr. Thomas Brown is an Associate Professor with tenure in the Adult Reconstruction division of Orthopaedic Surgery at the University of Virginia. He also serves as the Program Director for the Adult Reconstruction (Joint Replacement) fellowship program. Dr. Brown's training began at East Carolina University where he received both a Bachelor's and Master's degree in Exercise Physiology. He was Co-Captain of the Men's Basketball team. Medical school training was completed at the Medical University of South Carolina, where he received the Thomas M. Savage Award for academic excellence, and served as the President of the local AOA Honor Society. Residency training was completed at Geisinger Medical Center, followed by a short time in private practice, before completing a Joint Replacement fellowship at UVA. He joined the faculty in 1999.

Dr. Brown's clinical and research interests have focused on complex hip and knee replacement, and he has been awarded the UVA School of Medicine Master Clinician Award.



James A. Browne, MD*


Vice Chair for Clinical Operations
Alfred R. Shands Professor

Dr. James Browne is the Alfred R. Shands Professor in the Adult Reconstruction division of Orthopaedic Surgery at the University of Virginia. He also serves as the Vice Chair of Clinical Operations and Division Head of Adult Reconstruction.

He was born and raised in Canada and moved to Virginia to pursue his education at Washington and Lee University where he captained the Men's Swim Team before graduating Summa Cum Laude. Dr. Browne completed medical school at Johns Hopkins University, residency in Orthopaedic surgery at Duke University, and fellowship in Hip and Knee Arthroplasty at the Mayo Clinic where he was honored with the Mark B. Coventry Adult Reconstructive Surgery Fellowship Award.

Dr. Browne's clinical interests and expertise include complex primary and revision hip and knee and he has been the recipient of the UVA Dean's Clinical Excellence Award. Along with his clinical interests, he is actively involved with research encompassing all aspects of hip and knee replacement, and has published numerous peer-reviewed journal articles and book chapters. Dr. Browne has been invited to speak nationally and internationally on topics related to joint replacement. He was awarded the Knee Society John Insall Award in 2014 for his research examining obesity and outcomes following total knee arthroplasty.

Dr. Browne holds several national leadership roles including Associate Editor of the *Journal of Arthroplasty* and Member of the Steering Committee of the American Joint Replacement Registry (AJRR). He has served as the Editor of the *AJRR Annual Report* for the past two years. Dr. Browne chairs the Miller Review Course, the premier board review course in the country. He is a member of both the Knee Society and Hip Society.



Quanjun Cui, MD

Gwo-Jaw Wang Professor and
Vice Chair for Research

Dr. Quanjun Cui is the G.J. Wang Professor of Orthopaedic Surgery, and Vice Chair for Research. Dr. Cui received his medical degree from Henan Medical University with Honors in China and then completed residency and fellowship training in Adult Reconstruction at the University of Virginia. He also completed an AO fellowship at the University of Bern in Switzerland. He is a board-certified orthopaedic surgeon and specializes in total hip and knee replacement, osteonecrosis, surgical hip dislocation to treat femoro-acetabular impingement, and computer-aided and minimally invasive surgery for total hip and knee arthroplasty.

Dr Cui's research is funded by the National Institute of Health (NIH) focusing on stem cell and arthritis. He has received numerous academic and professional accolades, including the Hip Society Otto Aufranc Award. He has been recognized as "America's Top Orthopaedist" since 2009 and in the Best Doctors of America® List since 2015.

Dr. Cui has written over 150 papers and book chapters and has edited 9 textbooks. He has served as faculty member for several national and international instruction courses including AAOS Instruction Courses, Advances in Arthritis, Arthroplasty and Trauma, and Advances in Surgical Technology. Dr. Cui has also served as Program Chair and Faculty Member at state, national and international meetings. He is a board member and reviewer for several prestigious journals including the *Journal of Arthroplasty*, the *Journal of Bone and Joint Surgery*, and the *Journal of Orthopaedic Research*. Dr. Cui is a fellow of the American Academy of Orthopaedic Surgeons, a member of the Orthopaedic Research Society, and a fellow of the American Orthopaedic Association (AOA). He served as President of the Virginia Orthopaedic Society in 2017 and President of ARCO in 2020.



Ian M. Duensing, MD

Assistant Professor

Dr. Ian Duensing started his education at Texas A&M University in College Station, Texas. After graduating magna cum laude, he continued his medical education at Texas A&M University Health Science Center and Baylor Scott & White Hospital in Temple, Texas. During medical school, he was inducted into the Alpha Omega Alpha Honor Medical Society and graduated with honors. He then completed his Orthopaedic residency training at the University of Utah in Salt Lake City, Utah, followed by a fellowship in Hip and Knee Arthroplasty at Duke University. Dr. Duensing's clinical interests and expertise include complex primary and revision hip and knee replacement, partial knee replacement, anterior total hip arthroplasty, and robotic assisted surgery. Along with his clinical interests, he is actively involved with research encompassing all aspects of hip and knee replacement, and has published numerous peer-reviewed journal articles and book chapters. He is passionate about providing good clinical care, trainee education, and research. His specific research interests lie in peri-prosthetic joint infection, patient reported outcomes, and genetic and familial influences of total joint outcomes. He will be joined by his wife, Lindsay, who has been by his side since college. They have two young boys, Nate (5 years old) and Jack (3 years old) and are anticipating the arrival of their third. Recreationally, they enjoy all things outdoors including hiking, fly fishing, and cycling.

Patient Selection Criteria to Optimize Safety in Outpatient Hip and Knee Arthroplasty

*Christopher J. Whalen, MD;
Jeremy T. Hines, MD;
James A. Browne, MD; Qunjun Cui, MD;
Thomas E. Brown, MD*

*University of Virginia,
Department of Orthopaedic Surgery
Charlottesville, VA*

ABSTRACT

Hip and knee arthroplasty has seen a shift from inpatient hospital-based procedures to shorter stays and now same day discharge in ambulatory surgery centers. Outpatient joint arthroplasty has been shown to potentially increase value to patients and providers alike, particularly with new payment models. Concerns regarding patient safety have been assuaged by careful patient selection and adoption of rigorous outpatient protocols. However, appropriate criteria depend on the unique situation of each institution. As the University of Virginia Department of Orthopaedic Surgery will be transitioning to performing surgery at the UVA Orthopedic Center on Ivy Road, we have sought to create institution-specific guidelines for patient selection to optimize safety for outpatient hip and knee arthroplasty.

INTRODUCTION

Total joint arthroplasty (TJA) has seen a shift from the traditional inpatient setting with multiple day stays to shorter length of stay and even same-day discharge (SDD) in the ambulatory setting. Purported benefits include potential for cost reductions, faster rehabilitation, improved patient satisfaction/outcomes, and decreased utilization and reliance on hospital resources.¹⁻⁵ Indeed, the

American Association of Hip and Knee Surgeons with the Hip and Knee Societies and the American Academy of Orthopaedic Surgeons have all endorsed a position statement in favor of outpatient joint replacement for some patients⁶. While there are understandable initial concerns regarding safety, particularly in free standing ambulatory surgery centers (ASCs) without immediate access to hospital- and ICU-level care, numerous studies have reinforced the notion that hip and knee arthroplasty can be performed safely in an ambulatory setting on carefully selected patients.^{4,7-10} In this regard, numerous papers have discussed selection criteria^{1,7,9,11} and some have even proposed scoring systems to determine outpatient eligibility.^{12,13} However, proposed criteria are often somewhat blunt instruments, conservatively excluding many patients who would actually do well, or are unique to a certain institution and their setup. That is, criteria can differ tremendously between a hospital-based outpatient arthroplasty program with access to consulting services, ICUs, and inpatient beds as compared to a free-standing orthopaedic ASC without overnight capabilities. Similarly, different ASCs have differing levels of consultant support; while some may rely entirely on the orthopaedic provider and their anesthesia colleague, others may have dedicated in-house medical physicians or general surgery colleagues with vascular surgery experience, for example. It is also important to consider the timing of when complications generally occur. While intraoperative complications such as a vascular injury may be better dealt with in a hospital setting, many postoperative complications are now occurring after

discharge even for inpatient arthroplasty. For example, in a review of 10,244 arthroplasty patients at the Mayo Clinic, the median time to myocardial infarction was 1 day, to pulmonary embolism was 4 days, to deep vein thrombosis was 7 days, and to death was 14 days.¹⁴ A more recent registry study on 13,646 hip arthroplasty patients showed median days-to-events for same-day discharge vs. inpatients was 11 vs. 12 for ED visits and 23 vs. 20 for readmission with similar patterns for their other outcomes.¹⁰ As average lengths of stay for hip and knee arthroplasty have decreased towards 1-2 days, it is easy to see how many complications will occur outside of the healthcare setting regardless of inpatient or outpatient status.

On top of the patient safety issues, there are also concerns with regards to billing and patient satisfaction that must be considered. From a billing perspective, the removal of hip and knee arthroplasty from the Medicare Inpatient-Only (IPO) list has sped the transition to outpatient arthroplasty while simultaneously creating billing uncertainties. While arthroplasty done in a free-standing ASC will very clearly be billed as outpatient, confusion exists regarding the status of hip and knee arthroplasty performed in a hospital-based setting. The Centers for Medicare & Medicaid Services (CMS) have left it largely to institutions to determine inpatient or outpatient status with very few guidelines. As there is significantly decreased facility reimbursement for outpatient TJA, status determination will have huge ramifications for health systems' budgets, with hospital-based orthopaedic departments without lower cost ASCs potentially feeling the crunch the most. In light of these concerns, written institutional criteria for determining inpatient or outpatient status for TJA should also prove beneficial for billing and avoiding potential audits. Additionally, as bundled payment models become more prevalent, decreasing costs while maintain-

ing quality (i.e., improving value) is even more important and outpatient TJA, particularly at specialized ASCs, can likely help achieve this goal.^{1,4,5,15-18}

Finally, we are in the era of patient-centered care with increasing focus on patient-reported outcomes (PROMs) and value-based care. As such, it is important that changes to care delivery take into account the patient perspective. In regards to the shift towards outpatient TJA, it therefore seems imperative that patient selection must take into account patients' viewpoints on, or openness towards, outpatient surgery as well as their home setup and social support system in order to achieve a successful patient-centered outcome. Studies have shown that outpatient TJA can lead to equivalent or improved patient satisfaction relative to hospital-based and/or inpatient arthroplasty.^{1,19} In one analysis, researchers at Rush surveyed TJA patients and found high satisfaction in both inpatient and outpatient cohorts, though outpatients had more top responses in regards to their treatment and preparedness for discharge.¹⁹

Our institution, the University of Virginia, is currently in a transition period to outpatient TJA surgery. In our current practice, many patients may be discharged home the same day as surgery. However, all hip and knee arthroplasties are performed in the hospital setting and therefore have access to a full range of consulting services, ICU-level care, blood bank services, inpatient beds, etc. regardless of the patient's initial status as inpatient or outpatient. Therefore, we are better shielded from the safety concerns described above, though some may still raise concerns with discharging a hospital-based TJA patient home the same day despite a seemingly uncomplicated initial recovery. Similarly, as all patients currently have the option of staying overnight and receiving hospital-level care in whatever form that may be, the patient perspective is less of an

issue in determining inpatient/outpatient status. However, in the upcoming year we will begin to perform hip and knee arthroplasty outside of the hospital-based setting in the new UVA Orthopedic Center on Ivy Road. While the modern, purpose-built center does have several overnight (23-hour) stay beds, it will largely function as a free-standing ambulatory surgery center; no consulting services beyond the orthopaedic and anesthesia providers, no ICUs, relatively limited central services inventory and capabilities, and functionally no blood bank. In light of this exciting transition and the above concerns, we have sought to create UVA institution-specific guidelines for determining patient eligibility for hip and knee arthroplasty performed at the UVA Orthopedic Center on Ivy Road.

METHODS

In an effort to base our guidelines on the best available current evidence, we performed a search utilizing PubMed with the search terms for title of "outpatient" and "arthroplasty" focusing on manuscripts published in reputable peer-reviewed journals since 2015. These papers were reviewed for relevance by the two primary authors. Relevant references from the initial papers were also reviewed. Consensus criteria were then drafted based on this literature review. It became clear that, in addition to traditional medical contraindications, there are additional "failure to launch" issues that needed to be accounted for in our criteria. These are the most common reasons for failure of same-day discharge and include nausea/vomiting, hypotension, hypoxia, oversedation, pain, urinary retention, patient/relative choice, and lack of social support.^{1,6,9,16}

Additionally, we reviewed and incorporated the current University of Virginia outpatient surgery center patient selection criteria (used at the established outpatient surgery department), with the understand-

ing that these criteria would still apply to all University of Virginia outpatient surgery, including at the UVA Orthopedic Center on Ivy Road. In certain circumstances, these current criteria are more liberal than our proposed guidelines, reflecting the differences in underlying patient population and surgical procedure.

After draft criteria were agreed upon by the primary authors, a workgroup was convened with the three senior hip and knee arthroplasty surgeons at the University of Virginia. The criteria were reviewed, discussed, and modified until consensus was obtained. It should be noted that these guidelines are intended to provide a general framework for patient triage and the ultimate decisions about site of care will be determined at the individual level through shared decision making.

RESULTS

Patient selection criteria are shown in Figure 1. We have included social/support issues, surgeon/surgery factors, and psychological factors, in addition to medical comorbidities. Some criteria are clearly objective, e.g., age less than 75, while others have some subjectivity and allow for discretion on the part of the care team. Medical comorbidities have been divided into “Caution” and “Avoid” categories. Generally speaking, “Avoid” conditions are those involving end-stage organ disease or clearly likely to require care beyond that provided at an ambulatory surgery center. “Caution” conditions are those that have some potential to interrupt the expected postoperative course but in isolation or in mild cases may still be amenable to outpatient surgery.

DISCUSSION

Hip and knee arthroplasty has seen a shift to the outpatient setting including in free-standing ASCs. While this has the potential to improve value to both patients

Patient Selection

- Age < 75
- Patient has independent ambulatory status and is independent in ADLs (cane/walker ok if due to joint pain), can perform > 4 mets activity
 - No neurological or proprioceptive risks for falls
- Patient has realistic expectations on surgery and discharge in outpatient fashion
 - Expectations of pain (declining) and function (improving) over time
- Adequate home support and reasonable driving distance (< 2 hr or willing to get hotel room in town, see below)
- Primary/predictable planned procedure
 - EBL < 500, no anticipation of blood products/allograft needed
 - < 2-hour surgical time
 - Standard operative equipment/pans
- Caution of short stay/outpatient TJA in patients with the following issues (if multiple or severe, consider inpatient or outpatient at main hospital):
 - Chronic narcotic use
 - Fibromyalgia
 - Many allergies particularly relating to anesthesia or pain medications
 - Poorly controlled/significant depression/anxiety
 - Obstructive sleep apnea, compliant w/ CPAP (book earlier in day)
 - Well-managed COPD, not on O2
 - Gastric bypass if malabsorption syndromes; malnourished
 - BMI < 20 or > 35
 - Non-insulin dependent diabetes mellitus (Hb A1c < 7.5)
 - Requiring blood thinners—if bridging not required (isolated atrial fibrillation)
 - Autoimmune conditions particularly if on steroids, DMARDs
 - Poor health literacy
 - Vascular disease, lymphedema
 - Chronic kidney disease, eGFR 60-90
- Avoid short stay/outpatient TJA in patients with the following end-organ issues:
 - Contraindication to local/spinal anesthetic
 - Anemia (Hb < 12)
 - COPD, poorly controlled and/or requiring O2
 - OSA and noncompliant w/ CPAP
 - Congestive heart failure w/ impaired EF
 - Pacemaker/defibrillator
 - Chronic kidney disease (eGFR < 60)
 - Insulin-dependent diabetes mellitus
 - Liver cirrhosis
 - Requiring blood thinners—if bridging required
 - Coagulopathy/bleeding disorder
 - Any comorbidity likely to require comanagement with other specialty (e.g., hx MI, significant CAD, transplant, major urology issues)

Home Support

- Ensure patient has adequate home support system (family/friends) following discharge
 - Normal social support, able-bodied adult who can stay with them
 - Home location is reasonable (< 2 hr away)
- Ensure patient has appropriate equipment needed to perform ADLs
 - Walker/crutch/cane prescription
 - Toilet platform/riser
 - Shower handrails/safety bars
 - Stairwell railing/minimizing excessive stair climbing
- Ensure patient has appropriate transportation available to and from surgery as well as postoperative appointments and physical therapy
 - These appointments should be made prior to surgical date and communicated to patient if possible

Figure 1. UVA Orthopedic Center on Ivy Road Hip and Knee Arthroplasty Patient Selection Criteria.

and providers, careful patient selection is paramount. We have developed institution-specific guidelines for the University of Virginia Department of Orthopaedic Surgery regarding hip and knee arthroplasty in the outpatient setting at the new UVA Orthopedic Center on Ivy Road. We anticipate that the surgeons, physician extenders, and trainees who book a surgical case can reference these guidelines. The process is envisioned to be a collaborative effort, with nurse coordinators and surgery schedulers ultimately confirming patient eligibility for outpatient joint replacement surgery utilizing these guidelines. Undoubtedly, some questions may arise that may require consultation with the surgeon regarding safety of outpatient surgery, and it will remain an option to have surgery at the main hospital with planned SDD assuming no complications arise. This may be the best course of action for patients with whom there are medical concerns but they do not meet clear inclusionary criteria for outpatient surgery. We recognize that these criteria may need to be modified as our experience with outpatient TJA grows, with these initial guidelines intended to err on the side of safety. Importantly, these guidelines do not negate or supersede preexisting guidelines or the importance of shared decision making with the patient. Specifically, the general institutional guidelines on outpatient surgery candidacy already in place remain, though in general our criteria are more stringent. Similarly, general arthroplasty guidelines regarding optimization of comorbidities prior to elective surgery (such as reducing body mass index, smoking cessation, and optimization of diabetic control) remain in place.

It is important to highlight that patient selection is only one piece, albeit an important one, of a successful outpatient arthroplasty program. Other necessary components not addressed in the above guidelines that may need creating/modifying include

patient preoperative education/expectations, staff education, multidisciplinary care teams, rapid recovery protocols, anesthesia/pain management protocols, discharge planning, physical therapy, and follow-up care and provider availability.^{1,2,4,6,11,16,20,21} With these components in place, it will be important to constantly reevaluate our progress and success with outpatient arthroplasty. Jaibaji et al.⁹, with creation of their own outpatient protocols, found 93% of planned outpatient hip and knee arthroplasties did indeed achieve SSD. Even among their inpatient cohort, 16% achieved SDD. In order for our program at the UVA Orthopedic Center on Ivy Road to be successful and sustainable, we need to have near 100% 23-hour or less stays, ultimately working towards the majority of those being SDD. Similarly, we will need to closely monitor our complications and readmissions in comparison to our hospital-based patients.

With the utilization of our institution-specific patient selection guidelines for hip and knee arthroplasty, we will be prepared to safely transition to TJA in a free-standing surgery center. In doing so, we can increase the value we provide to our patients, to our institution, and to our providers while continuing our culture of safety and excellence at the University of Virginia. ■

REFERENCES

1. Scully RD, Kappa JE, Melvin JS. "Outpatient"-Same-calendar-day discharge hip and knee arthroplasty. *J Am Acad Orthop Surg*. 2020;28:e900-909.
2. Meneghini RM. Outpatient joint replacement: Practical guidelines for your program based on evidence, success, and failures, a moderator introduction. *J Arthroplasty* 2019;34:S38-39.
3. Husted H et al. Time-driven activity-based cost of outpatient total hip and knee arthroplasty in different set-ups. *Acta Orthop*. 2018;89:515-521.
4. Rozell JC et al. Outpatient total joint arthroplasty: The new reality. *J Arthroplasty*. 2021;In press.
5. Chambers M, Huddleston JI, Halawi MJ. Total knee arthroplasty in ambulatory surgery centers: The new reality. *Arthroplasty Today*. 2020;6:146-148.

6. Meneghini RM et al. The American Association of Hip and Knee Surgeons, Hip Society, Knee Society, and American Academy of Orthopaedic Surgeons Position Statement on Outpatient Joint Replacement. *J Arthroplasty*. 2018;33:3599-3601.
7. Courtney PM, Boniello AJ, Berger RA. Complications following outpatient total joint arthroplasty: An analysis of a national database. *J Arthroplasty*. 2017;32:1426-1430.
8. Bovonratwet P et al. Comparison of outpatient vs. inpatient total knee arthroplasty: An ACS-NSQIP Analysis. *J Arthroplasty*. 2017;32:1773-1778.
9. Jaibaji M et al. Is outpatient arthroplasty safe? A systematic review. *J Arthroplasty*. 2020;35:1941-1949.
10. Reddy NC et al. Frequency and timing of complications and catastrophic events following same-day discharge compared to inpatient total hip arthroplasty. *J Arthroplasty*. 2021;In press.
11. Li J, Rubin LE, Mariano ER. Essential elements of an outpatient total joint replacement programme. *Curr Opin Anesthesiol*. 2019;32:643-648.
12. Meneghini RM et al. Safe selection of outpatient joint arthroplasty patients with medical risk stratification: the "Outpatient Arthroplasty Risk Assessment Score." *J Arthroplasty*. 2017;32:2325-2331.
13. Ziemba-Davis M, Caccavallo P, Meneghini RM. Outpatient joint arthroplasty-Patient selection: Update on the Outpatient Arthroplasty Risk Assessment Score. *J Arthroplasty*. 2019;34:S40-S43.
14. Mantilla CB et al. Frequency of myocardial infarction, pulmonary embolism, deep venous thrombosis, and death following primary hip or knee arthroplasty. *Anesthesiology*. 2002;96:1140-1146.
15. Yates AJ et al. The unintended impact of removal of total knee arthroplasty from the center for medicare and medicaid services inpatient-only list. *J Arthroplasty*. 2018;33:3602-3606.
16. DeCook CA. Outpatient joint arthroplasty: Transitioning to the ambulatory surgery center. *J Arthroplasty*. 2019;34:S48-S50.
17. Iorio R et al. Total knee replacement: The inpatient-only list and the two midnight rule, patient impact, length of stay, compliance solutions, audits, and economic consequences. *J Arthroplasty*. 2020;35:S28-S32.
18. Iorio R et al. Improving arthroplasty efficiency and quality through concentrating service volume by complexity: Surviving the medicare policy changes. *J Arthroplasty*. 2021;In press.
19. Kelly MP et al. Inpatient versus outpatient hip and knee arthroplasty: Which has higher patient satisfaction? *J Arthroplasty*. 2018;33:3402-3406.
20. Sah A. Considerations for office and staff protocols for outpatient joint replacement. *J Arthroplasty*. 2019;34:S44-S45.
21. Hamilton WG. Protocol development for outpatient total joint arthroplasty. *J Arthroplasty*. 2019;34:S46-S47.



M. Truitt Cooper, MD

Associate Professor

Dr. Truitt Cooper is an Associate Professor of Orthopaedic Surgery at the University of Virginia, and Director for the Foot and Ankle Surgery Fellowship program. He also serves as the Medical Director for the ambulatory orthopaedic clinics. Dr. Cooper grew up on the east coast of Florida and attended college at Washington and Lee University. He completed his M.D. at the University of Virginia, and his Orthopaedic Surgery residency at The Ohio State University. Following residency, Dr. Cooper took subspecialty training in Foot and Ankle Surgery with Dr. Michael J. Coughlin in Boise, Idaho. After several years in Private Practice in Richmond, Virginia, Dr. Cooper made the decision to return to the University of Virginia to pursue a career in academics. He joined the faculty in 2014.

Dr. Cooper is an active member of the American Orthopaedic Foot and Ankle Society (AOFAS). He currently serves as the Chair of the On-Demand Education Committee (previously the Physician Resource Committee), and also serves on the Education Committee and the Annual Meeting Planning Committee. He serves as a section editor for *Foot and Ankle Specialist* and as a reviewer for *Foot and Ankle International*.

In addition to maintaining an active clinical practice focusing specifically on foot and ankle reconstruction, Dr. Cooper has numerous research interests. These include total ankle arthroplasty, midfoot injuries, and arthrodesis healing. He is currently involved in multi-center clinical trials involving total ankle replacement.



Shepard Hurwitz, MD

Professor Emeritus

Dr. Shepard Hurwitz grew up in New Rochelle, New York, and went to Columbia College, followed by Columbia University College of Physicians & Surgeons for his BA and MD, respectively. He was a college fencer on a team that won two NCAA championships.

Dr. Hurwitz spent two years in Charlottesville after medical school as a General Surgery Resident (1976-1978) and then completed an Orthopaedic Residency in New York City, at the New York Orthopaedic Hospital. He completed one year of adult and pediatric foot/ankle training at the Hospital for Special Surgery in New York City then another year of biomechanics and fracture surgery at New York Hospital/Hospital for Special Surgery. He joined the UVA faculty in 1994 and was the Chief of the Foot/Ankle Division of the department.

Dr. Hurwitz has been on numerous AAOS and AOA committees as well as committees for the ORS, OTA, and AOFAS. He was a member-at-large of the AOFAS Board of Directors (2005-2007), President of the Eastern Orthopaedic Association (2002-2003), and President of the Southeastern Fracture Symposium (2006-2008). He was on the ABOS Board of Directors (2005-2007) and was the Executive Director of the ABOS (2007-2016). He was on the UVA Faculty Senate (2003-2006) and several SOM committees.

Dr. Hurwitz has two daughters, Zoe and Leah, who are both competitive athletes. Dr. Hurwitz volunteers in North Carolina as a physician to the athletic teams in Carrboro and Chapel Hill, and he is the Administrator of the Surgical Skills Laboratory in the Department of Orthopaedic Surgery. His hobby is shooting clay pigeons and competing in skeet and sporting clays events. He plays tennis occasionally and enjoys fishing when he gets the chance to go out on someone else's boat.



Joseph S. Park, MD*

Associate Professor

Dr. Joseph Park is an Associate Professor of Orthopaedic Surgery at the University of Virginia, and Associate Fellowship Director. He is the Foot and Ankle Division Head within the Department of Orthopaedic Surgery at UVA, and serves as a Team Physician and Foot and Ankle Surgeon for UVA Athletics.

Dr. Park was born in Brooklyn, New York, and grew up in the suburbs of Baltimore, Maryland. He earned his undergraduate degree from the University of Pennsylvania, where he graduated Magna Cum Laude. He then graduated Alpha Omega Alpha from the UVA School of Medicine. Dr. Park continued his education by completing an Orthopaedic Surgery residency at New York University Langone Orthopaedic Hospital. He then completed his Fellowship in Orthopaedic Foot and Ankle Surgery at Union Memorial Hospital in Baltimore, Maryland. He returned to UVA in 2010 to join the Orthopaedic Surgery Faculty.

Through his research collaborations with the Biomedical and Mechanical Engineering Departments at UVA, Dr. Park has helped establish UVA and the Center for Applied Biomechanics as nationally recognized leaders in biomechanical testing of orthopaedic implants. In recognition of his contributions, he was awarded a secondary appointment in Mechanical and Aerospace Engineering in 2019. Dr. Park was promoted to Associate Professor with Tenure in 2020 and was voted by his peers as one of the Best Doctors in America for 2015-2016, 2017-2018 and 2019-2020. He also received the Dean's Award for Clinical Excellence from UVA in 2015.

Dr. Park is a reviewer for the *Journal of Bone and Joint Surgery*, *Foot and Ankle International*, as well as *Foot and Ankle Orthopaedics*. He is the Associate Foot and Ankle Fellowship Director at UVA, and has served as Chairman of the Physician Resource Center Committee for the American Orthopaedic Foot and Ankle Society (AOFAS). Dr. Park is currently the Chairman of the AOFAS Orthopodcast Committee. In 2021, he was elected to the AOFAS Foundation Board of Directors as a Member at Large. In November 2018, he traveled to Xiamen, China, where he was selected to represent the AOFAS at the 13th Annual Congress of the Chinese Orthopaedic Association.



Venkat Perumal, MD

Assistant Professor

Dr. Venkat Perumal was born and grew up in India. He attended medical school and completed Residency in Orthopaedic Surgery in India.

Dr. Perumal is an Assistant Professor in the Foot and Ankle Division and has completed multiple fellowships. He completed fellowships in Pediatric Orthopaedic Surgery at Cincinnati Children's Hospital, Orthopaedic Trauma at the University of Louisville, and both Adult Reconstruction and Foot and Ankle Surgery at UVA. Dr. Perumal joined the UVA Department of Orthopaedic Surgery's faculty in April 2013.

He is married to his wife, Vanitha, and has two children. He spends his free time with his family and enjoys playing chess, camping, biking, hiking, attending spiritual meetings, and volunteering in free medical camps and homeless shelters.

UVA Foot and Ankle Division

The faculty of the UVA Orthopaedic Foot and Ankle Division continues to build upon our reputation as a tertiary referral center for complex foot and ankle reconstruction. During the height of the COVID-19 pandemic, when most elective surgeries were halted, we were able to shift our focus to accommodate acute lower extremity fractures and tendon injuries. In conjunction with our Orthopaedic Trauma team, utilization of intraoperative CT has provided guidance for revision ankle fracture fixation, including syndesmotic reconstruction. (Figure 1)

As the Team Orthopaedic Foot and Ankle Surgeons for both the University of Virginia (Dr. Park) and James Madison University (Dr. Cooper) Athletic Departments, we have developed a unique niche throughout our region in the treatment of sports-related injuries to the foot and ankle. Innovative techniques, such as direct reconstruction of the Anterior Inferior Tib-Fib Ligament (AiTFL) (Figure 2) have enabled our elite athletes to return to play without the concerns for screw breakage/ removal or large diameter drill holes from flexible syndesmotic fixation. Incorporation of a suture anchor docking technique using smaller incisions for acute Achilles reconstruction (Figure 3A-C) has enabled earlier range of motion and faster return to play in collegiate athletes and weekend warriors alike.

Although several of our clinical trials were delayed because of COVID-19, we have resumed enrollment of patients in our Vivigen cellular allograft prospective study for ankle and hindfoot arthrodesis (Depuy-Synthes), as well as comparative motion analysis of ankle arthrodesis and arthroplasty for complex ambulatory tasks,

including climbing stairs and navigating uneven surfaces (Integra LifeSciences/ Shawn Russell, PhD: UVA Motion Analysis and Motor Performance Lab) (Figure 4A-B). Our Vivigen study (Figure 5) builds upon our recently published retrospective review of 113 foot and ankle arthrodesis procedures and 22 high risk fractures treated using this allograft bone graft

Although several of our clinical trials were delayed because of COVID-19, we have resumed enrollment of patients in our Vivigen cellular allograft prospective study for ankle and hindfoot arthrodesis (Depuy-Synthes), as well as comparative motion analysis of ankle arthrodesis and arthroplasty for complex ambulatory tasks, including climbing stairs and navigating uneven surfaces (Integra LifeSciences/ Shawn Russell PhD: UVA Motion Analysis and Motor Performance Lab) (Figure 4A-B).

that includes live osteoblasts and osteocytes (Moran et al, *Foot and Ankle Specialist*, 2020). Successful radiographic and clinical healing was demonstrated in 97 of 113 fusion cases (86%) and 19 of 22 fracture ORIF cases (86%). Arthrodesis outcomes were identical for primary or revision cases, but fusion rates were decreased in Charcot neuropathy patients (8/13:62%), and smokers (35/46:76%). Patients without a history of tobacco use had a 93% fusion rate (62/67) in our series. In our smaller subgroup of ORIF patients, no differences were seen for any of the identified risk factors or for revision procedures.

Our publication in *Foot and Ankle International* (Lee et al, 2019) demonstrated significant improvement in pain and functional scores after arthroscopic microfracture of tibial osteochondral defects. However, although all patients were able to return to sports activities after surgical treatment, they were unable to return to the same level of athletics when compared to their pre-operative level.

We also have multiple ongoing clinical studies investigating a variety of foot and ankle conditions. Collaborative studies with musculoskeletal radiology are being conducted to investigate the outcomes and utility of ultrasound guided injections for Morton's neuroma and tarsal tunnel syndrome. Other studies are currently investigating injury patterns for the Lisfranc complex, as well as return to activity after flatfoot reconstruction including lateral column lengthening. A functional gait analysis project with Jay Hertel, PhD, in Kinesiology is underway to examine the outcomes of central one-third turndown procedures with flexor hallucis longus transfer for Achilles tendon defects larger than 3 cm.

Collaborative projects with the UVA Center for Applied Biomechanics (CAB: Jason Kerrigan, PhD, and Sang Lee, PhD) and Mechanical and Aerospace Engineering (Chris Li, PhD) have yielded multiple funded projects with industry to better characterize orthopaedic implant performance and characterization. Our expertise in total ankle replacement and robotic gait simulation has resulted in partnerships with Stryker, Paragon28, and Wright Medical. In order to better understand mechanisms of failure, our group will quantify micromotion of the tibial component in order to better understand mechanisms for osteolysis and loosening. Our Foot and Ankle/CAB team has also been selected to help investigate football

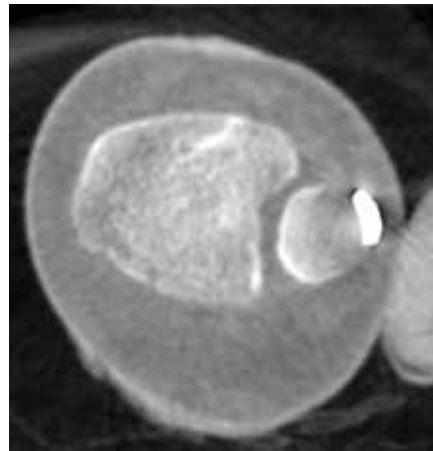


Figure 1. Intra-operative CT image demonstrating anatomic reduction of syndesmosis during revision syndesmotic reconstruction.

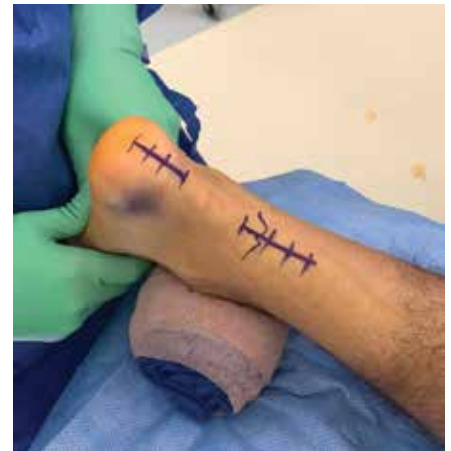

Figure 2. Figure 2B: Incisions for primary Achilles repair with docking Technique.

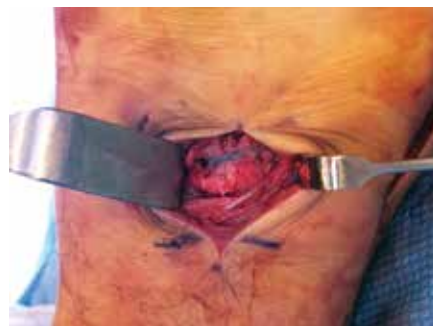

Figure 2. Direct reconstruction of anterior inferior tib-fib ligament with suture anchors in fibula (right) and docking into Chaput tubercle of tibia (left).

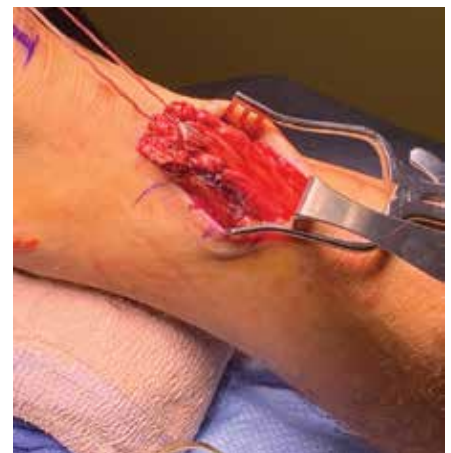
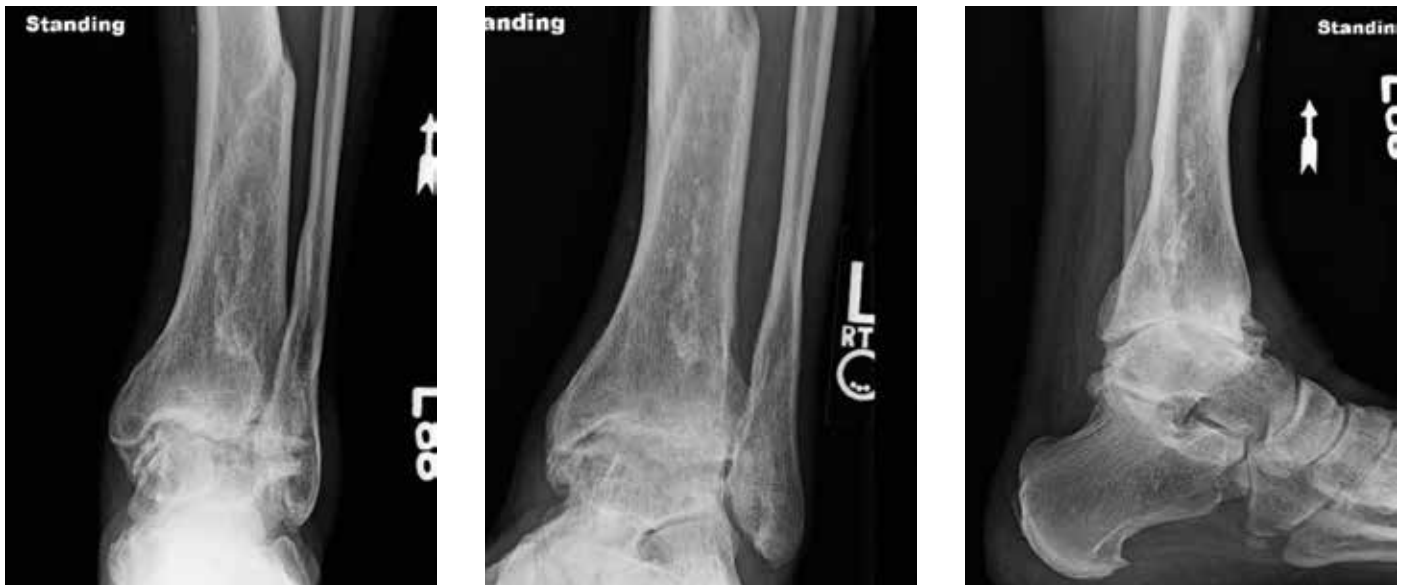
Figure 2. Figure 2C: Proximal Achilles tendon is captured with a Krackow suture, which is then passed percutaneously through the distal Achilles stump. The suture is then docked into the calcaneus using knotless interference anchors to allow for stable tendon fixation and to permit early range of motion.

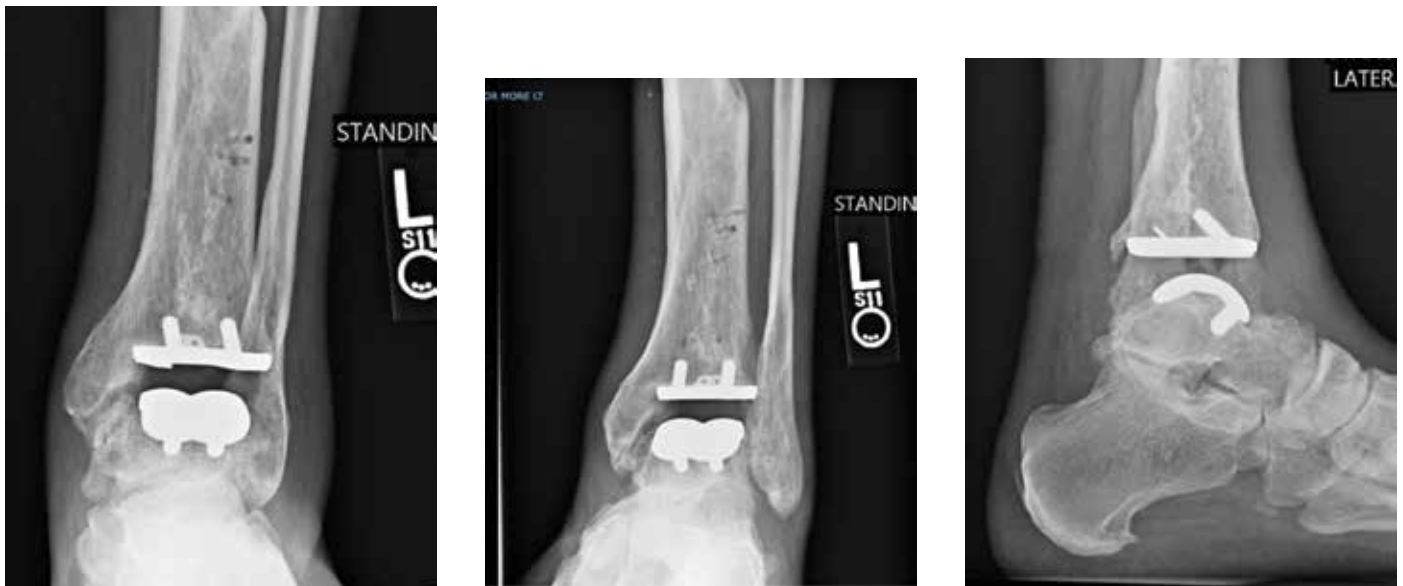cleat/artificial turf interactions in collaboration with the National Football League and Biocore LLC to help decrease lower extremity injuries in elite athletes. This project capitalizes on our team's vast experience and knowledge related to injury mechanism, characterization, and prevention for turf toe, Lisfranc, and syndesmotic injuries in previous collaborations with the NFL.

Dr. Chris Li's team has enabled us to utilize 3D image correlation techniques (Shen et al, *Clinical Biomechanics* 2020) to better understand nitinol compression staple technology for midfoot arthrodesis. Our bone substitute study showed that while a lag screw and locking plate

construct is more rigid than two nitinol staples, the plate construct cannot recover once plastic deformation and loss of compression has occurred. These findings suggest that for arthrodesis procedures, dynamic compression may help overcome bone resorption and micromotion during the post-operative healing period. Our subsequent matched pair cadaveric study looking at these arthrodesis constructs confirmed our findings, as well as the in-



Figures 4A-C. Preoperative AP, mortise, and lateral radiographs demonstrating endstage ankle arthritis with varus deformity from previous tib-fib fracture malunion.



Figures 4D-F. Post-operative AP, mortise, and lateral radiographs after Integra® Cadence® total ankle replacement with realignment/deformity correction.

creased risk of failure of fixation with early weight bearing in osteoporotic bone.

Dr. Truitt Cooper currently serves as the Medical Director for the Ambulatory Orthopaedic Clinics at the University of Virginia and is a Team Physician for James Madison University Athletics. He is also the Fellowship Director for the University of Virginia Orthopaedic Foot and Ankle Fellowship, now in its 5th year. On a na-

tional level, he is an editor for *Foot and Ankle Specialist*, a reviewer for *Foot and Ankle International*, and serves as the Vice-Chair for the Physician Resource Committee of the American Orthopaedic Foot and Ankle Society.

Dr. Joseph Park is the UVA Orthopaedic Foot and Ankle Division Head and a Team Physician for UVA Athletics. He also holds a secondary appointment in

Mechanical and Aerospace Engineering at UVA in honor of his extensive collaborative work with the Center for Applied Biomechanics and Biomedical/Mechanical Engineering.

Nationally, he is the Host and Chairman of the American Orthopaedic Foot and Ankle Society Orthoped-cast Committee. Dr. Park is a reviewer for *Journal of Bone and Joint Surgery* as well as *Foot and*

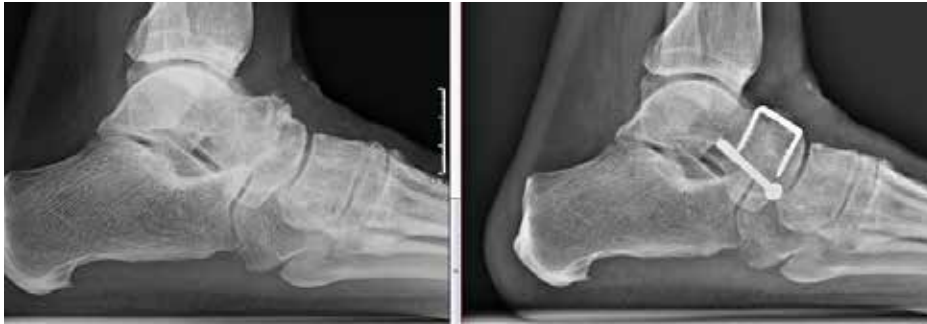

Figure 5. Talonavicular arthrodesis with ViviGen® cellular allograft.

Ankle International, and was co-editor for the 2020 Foot and Ankle edition of *Clinics in Sports Medicine*.

Dr. Venkat Perumal is the curriculum director for the residents' Foot and Ankle rotation, and has expanded our division's outreach to Culpeper Medical Center in order to increase our visibility in the Northern Virginia and Fredericksburg region.

Dr. Shep Hurwitz, UVA Professor Emeritus and former Executive Director of the ABOS (2007 to 2016), has returned

to UVA to help facilitate research and grant support for our Foot and Ankle Division and Orthopaedic Department. Dr. Hurwitz will help coordinate partnerships with other institutions to increase funding and highlight the innovative research done at the Center for Applied Biomechanics and Engineering Department. We are currently working with the University of Washington to develop a robotic gait simulator and computer model for the lower extremity.

Dr. Hurwitz will help coordinate partnerships with other institutions to increase funding and highlight the innovative research done at the Center for Applied Biomechanics and Engineering Department. We are currently working with the University of Washington to develop a robotic gait simulator and computer model for the lower extremity.

Our two Physician Assistants, Jim Shorten and Andrea White, have enabled our Foot and Ankle Division to increase access and improve patient care for our complex patient population. Jim serves as the PA Division Head for UVA Orthopaedics, and Andrea's endocrine background and expertise has been instrumental in optimizing patients during the perioperative period. ■



A. Bobby Chhabra, MD

Lillian T. Pratt Distinguished Professor and Chair

Dr. A. Bobby Chhabra is the Lillian T. Pratt Distinguished Professor and Chair of Orthopaedic Surgery, the David A. Harrison Distinguished Educator, Professor of Plastic Surgery and Professor of Pediatrics at the University of Virginia. He is also a team physician and the Hand and Upper Extremity consultant for the UVA Department of Athletics. He served as UVA Physicians Group President for 5 years and is currently the School of Medicine Faculty Representative to the UVA Health System Board and Board of Visitors.

Dr. Chhabra's areas of expertise include hand, wrist, and elbow trauma and arthritis with a particular interest in sports injuries and congenital hand surgery.

Dr. Chhabra is a nationally recognized educator. He has received the University of Virginia School of Medicine Dean's Award for Excellence in Teaching, the University of Virginia Master Educator Award and the David A. Harrison Distinguished Educator Award, the highest teaching honor at the University of Virginia School of Medicine. In 2014, Dr. Chhabra was inducted into the Raven Society, the most prestigious honorary society at the University of Virginia.

Dr. Chhabra graduated from the Johns Hopkins University with a degree in biology before completing his medical education at the University of Virginia School of Medicine. He completed his residency training in Orthopaedic Surgery at the University of Virginia Health System. He received his fellowship training in Hand and Upper Extremity, Microvascular and Congenital Hand Surgery at the Hand Center of San Antonio and the Texas Scottish Rite Hospital.

Dr. Chhabra has published over 60 peer-reviewed articles, 40 book chapters, has been the editor for 5 text books, given 160 national/international presentations and has been invited as a Visiting Professor at 25 prestigious institutions.



A. Rashard Dacus, MD*

Associate Professor and Vice Chair for Diversity, Inclusion & Wellness

Dr. Dacus joined the department in August of 2007 after completing a fellowship in hand and upper extremity at the University of California, San Diego. His practice has grown rapidly in his time here and his practice continues to encompass joint replacement in the hand and elbow and reverse total shoulder arthroplasty as well as micro vascular surgery of the hand and upper extremity. He is currently working on a research project to study the effect of EMG results on treatment plans/outcomes in patients with carpal and cubital tunnel syndrome. He served as the Residency Program Director from 2011 to 2019, after serving as the Assistant Residency Director from 2009 to 2011. He served as the co-fellowship director for the Hand and Upper Extremity Division from 2009 to 2014. In July 2019, he was appointed the Vice Chair for Diversity and Wellness in the UVA Department of Orthopaedic Surgery. Dr. Dacus has also enjoyed being an Assistant Team Physician for James Madison University Athletics since 2008 and continues in this capacity. He is dedicated to the Charlottesville community and serves on the Board of Advisors for Big Brother/Big Sisters of Central Virginia and the New Hill Board. He has participated in the Health Fair at Washington Park by providing physicals since 2009. He enjoys spending time with his wife and baby daughters and travelling to new places. He has served as a mentor and guest speaker for the AVID program at Albemarle High School.



D. Nicole Deal, MD

Professor

Dr. Nicole Deal is a Professor in the Department of Orthopaedic Surgery at the University of Virginia and holds a dual appointment with the Department of Plastic Surgery. She is the Orthopaedic Director for the Amyloid Center of Excellence at the University of Virginia. Based on excellence in patient care, she is one of six faculty selected from across the Health System as facilitators for the Patient Experience Project, teaching other health care providers the art of patient interaction. She received her undergraduate degree from the University of Virginia, completed medical school at the Medical University of South Carolina, and did Residency and Hand Fellowship at Wake Forest University. In 2009, Dr. Deal was excited to join the Orthopaedic Hand faculty at the University of Virginia.

Since joining the faculty, Dr. Deal has received many faculty achievement awards including the Dean's Award for Clinical Excellence in 2013, and the Dean's Award for Teaching Excellence in 2015, and was inducted into the Academy of Distinguished Educators in 2016. Dr. Deal served as the President of the Virginia Orthopaedic Society from 2020-2021.

Dr. Deal has authored 28 peer-reviewed journal articles and 27 book chapters. Her research interests include nerve regeneration techniques and she has received two prestigious Coulter Foundation grants for her collaboration with faculty from the Department of Biology to develop novel techniques to stimulate nerve growth.

**Aaron M. Freilich, MD**

Associate Professor

**Brittany Behar, MD**

Assistant Professor

**Brent DeGeorge Jr., MD, PhD**

Assistant Professor

Dr. Aaron M. Freilich is an Associate Professor of Orthopaedic Surgery and Plastic Surgery at the University of Virginia who specializes in Hand and Upper Extremity Surgery. He is Director of the UVA Hand Center, Director of UVA Orthopaedic Information Technology and Innovation, Orthopaedic Hand and Upper Extremity Fellowship Director and the 3rd Year Clerkship Director for UVA's School of Medicine. He began his secondary education at the University of Michigan, studying Economics and Cell and Molecular Biology, where he graduated with honors. He received his M.D. from the University of Virginia and continued on to complete his Orthopaedic Surgery residency, before training in a Hand and Upper Extremity Fellowship at Wake Forest Baptist Medical Center.

Dr. Freilich is a member of the AAOS and the ASSH, and serves on several committees both locally and nationally. He also continues to serve as a member of the UVA Medical School Curriculum Committee.

Dr. Freilich's practice focuses on treating hand, wrist and elbow problems, with a particular interest in trauma and microvascular reconstruction. He works closely with his Plastics and Orthopaedic Hand colleagues in training residents and fellows and in further developing a joint hand reconstructive service. His research interests are in education and simulation training and collaboration with the Center for Applied Biomechanics.

Brittany Behar, MD, is an Assistant Professor of Plastic Surgery and Orthopaedic Surgery. A plastic surgeon specializing in the treatment of traumatic injuries affecting the hand and wrist. She is skilled in microsurgery, general wound care and reconstruction, and congenital and pediatric hand surgery.

Dr. Behar graduated from the University of Virginia in 2007, after completing her honors thesis in Human Biology. She received her medical degree, graduating AOA, from Drexel University in Philadelphia, Pennsylvania. She completed integrated plastic surgery residency at Penn State Hershey Medical Center in Hershey, Pennsylvania, before completing her hand and microsurgery fellowship at the University of Pennsylvania in Philadelphia. She joined the UVA Hand Center in 2019.

In her free time, she enjoys reading, working out, cooking and spending time traveling with her husband and daughter.

Brent DeGeorge, MD, is an Assistant Professor of Plastic Surgery and Orthopaedic Surgery, Director for the Plastic Surgery / Hand Surgery Fellowship, and Medical Director of Wound Care at UVA Hospital. His areas of expertise include brachial plexus and peripheral nerve surgery and hand, wrist and forearm reconstruction following trauma. He also specializes in microsurgery and arthroscopy of the upper extremity.

Dr. DeGeorge graduated summa cum laude from The College of William and Mary and attended Jefferson Medical College and Thomas Jefferson University, where he completed his medical education and earned a PhD in molecular pharmacology and structural biology. He then completed his residency training in the Department of Plastic Surgery at UVA. Dr. DeGeorge went on to complete fellowship training in hand and microvascular surgery in the Department of Orthopaedic Surgery at the Mayo Clinic. He returned to UVA in 2017 to join the faculty at the UVA Hand Center.

In addition to his clinical work, Dr. DeGeorge's research interests include articular cartilage repair and regeneration techniques, patient-reported outcomes research, and medical cannabis research.

UVA Hand Highlights

The Hand Division is one of several academic medical centers contributing to a Nationwide Database on outcomes related to hand and digital replants following traumatic amputations.

The UVA hand division has 2 nationally recognized positions for hand fellows in collaboration with the Department of Plastic Surgery. We receive more than 100 applications for these 2 positions and routinely match in the top 5 people on our rank list.

Recent publications from the hand center:

Tendon and Nerve Transfers in the Setting of Tetraplegia

Brent R. DeGeorge Jr., MD, PhD

*UVA Health, Plastic Surgery
Charlottesville, VA, USA*

INTRODUCTION

Both nerve and tendon transfer techniques may be considered to restore hand and upper limb function in the setting of cervical spinal cord injury (SCI) with associated tetraplegia. Following SCI, upper limb loss of function proceeds in a predictable descending segmental fashion, and residual function is typically classified

by the presence of elbow flexion, wrist extension, pronation, wrist flexion, finger and thumb extension, finger flexion, or loss of intrinsic hand motor function. Optimizing a patient's function in terms of tendon or nerve transfers, tenodesis, or arthrodesis procedures is not only important for improving a patient's quality of life, it is also a crucial determinant of healthcare costs. Recent studies demonstrate that residual upper limb function is the single greatest determinant in hospital admission rates.

CASE PRESENTATION

H.G. is a 27-year-old female who sustained a SCI with resultant International Classification for Surgery of the Hand in

Tetraplegia Group 3 injury with recovery of function of the extensor carpi radialis brevis being the most distal motor group below the elbow. H.G. had retained shoulder and elbow function on the affected extremity. The patient desired any form of prehensile or grasp function. The patient had participated actively in therapy and retained supple hand joints. Af-

Optimizing a patient's function in terms of tendon or nerve transfers, tenodesis, or arthrodesis procedures is not only important for improving a patient's quality of life, it is also a crucial determinant of healthcare costs.

ter 9 months from the injury the patient demonstrated no further recovery of distal motor function, and pre-procedural electromyography demonstrated potential donor motor groups in the biceps without evidence of denervation and recipient motor groups in the finger and thumb flexors without evidence of denervation, however without evidence of motor units with volitional control. Contrary to the setting of brachial plexus injury in which reinnervation of motor groups must occur in a time-dependent manner, due to the intact loop between the anterior horn of the spinal cord and the recipient motor units the nerve transfers in this setting may be performed in a time-independent manner to restore the volitional connection between the brain and motor groups.

The patient underwent transfer of the brachialis branch of the musculocutaneous nerve to the anterior interosseous nerve to restore finger and thumb flexion. A longitudinal incision was placed on the medial aspect of the arm, and the

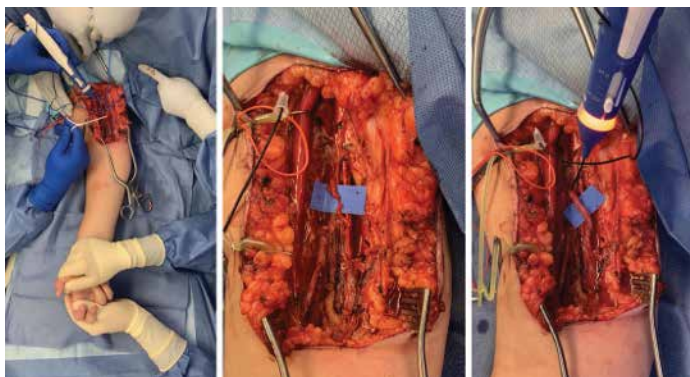


Figure 1. Brachialis motor branch to anterior interosseous nerve to restore finger flexion in setting of tetraplegia. (Left panel) Intraoperative nerve mapping of median nerve to identify finger and thumb flexion. (Middle panel) Nerve coaptation. (Right panel) Final nerve transfer.

interval between the biceps and triceps was developed to identify the musculocutaneous nerve branches to the biceps and brachialis and the terminal branches to the lateral antebrachial cutaneous nerve. Through the same incision the anterior interosseous nerve and flexor digitorum superficialis branches of the median nerve were identified using nerve stimulation for topographic nerve mapping. Neurolysis was performed to achieve adequate donor and recipient length for transfer and nerve coaptation was performed using microsurgical technique and reinforced with fibrin sealant and nerve conduits for a grouped fascicular repair.

CONCLUSION

After 6 months from the procedure the patient developed volitional control of rudimentary finger flexion and some thumb flexion, and additional procedures will be required for digital extension using further tendon transfers. In summary, there is a role for nerve transfer in the management algorithm of patients with SCI to optimize residual limb function, quality of life, and independence.

Scaphoid Nonunion in the Setting of Avascular Necrosis

Aaron M. Freilich, MD

*UVA Health, Orthopaedic Surgery
Charlottesville, VA*

As the Hand center at UVA has continued to evolve and grow, we have developed a unique and collaborative environment with our plastic surgeon colleagues. We see patients, attend conference and teach residents and fellows together. Both plastic surgeons have dual faculty appointments, as do all of the Orthopaedic hand

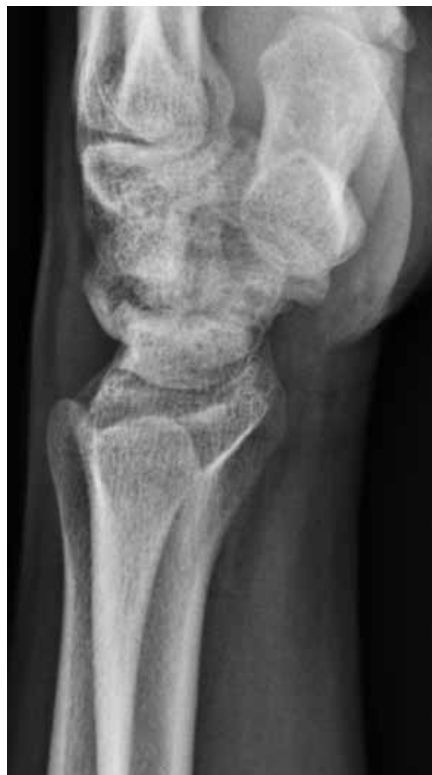
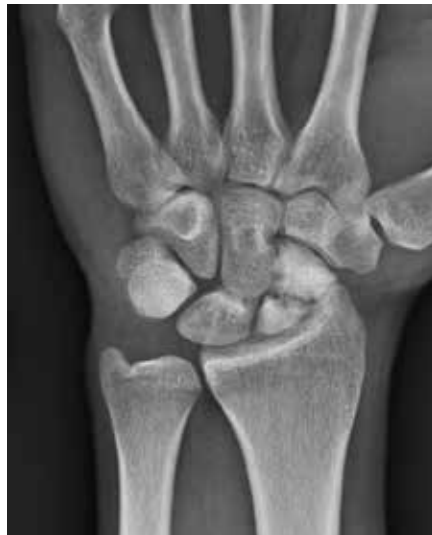
Figure 1. Preop, chronic nonunion of scaphoid with AVN.

surgeons. This cross-pollination and close working relationship allows us to attract top fellows for our two spots and to tackle complex hand surgery problems in a holistic way. The result is better care for our patients and a better educational and training environment for our fellows and residents.

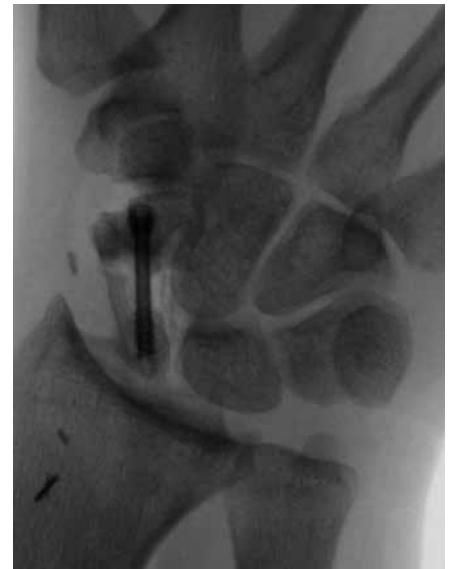

Figure 2. Intraop fluoro.

One area of hand surgery that remains unsolved and extremely difficult to treat is the scaphoid nonunion with avascular necrosis. If untreated, these patients continue to have pain and limitation in the short term and predictably develop arthritis in the intermediate to long term. Many of the classic treatment options either do not work or don't work reliably. This is especially true in multiply operated patients referred to UVA for a second opinion and our care. In conjunction with our plastic surgery partners, we utilized a technique that involves bringing vascularized bone from the knee to reconstruct the scaphoid at the wrist. This free flap, known as a medial femoral condyle flap or medial femoral trochlear flap (if cartilage is taken), can more reliably lead to healing of the disvascular bone even in cases where large cystic changes are already present. The procedure requires the use of 2 teams for efficiency and accuracy. We work in tandem at both the knee and wrist to develop the flap and reconstruct the bone. Ultimately, the bone graft's vascular supply is anastomosed under the operating microscope in the forearm. Patients end up spending one day in

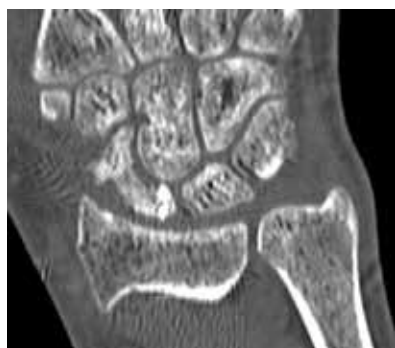
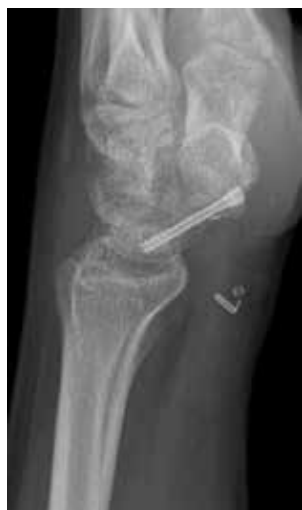
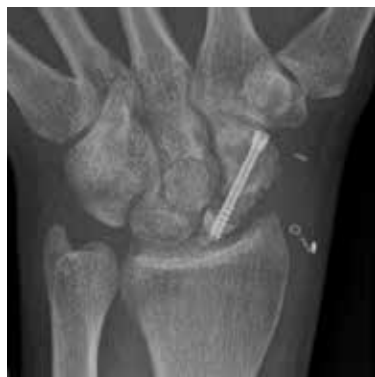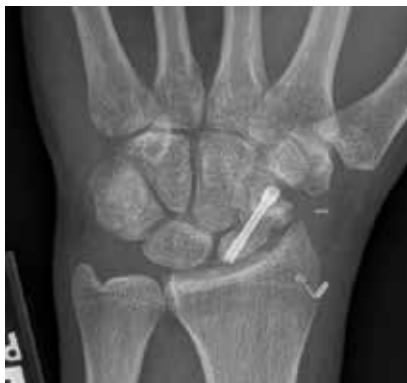Figure 3. Post op, healed with CT confirming union at 10 weeks.

the hospital, walking out the next day. This powerful technique has uses outside of the scaphoid and we have already started to expand its use for challenging nonunions of other carpal bones, as well as the foot.

Targeted Muscle Reinnervation

Brittany J. Behar, MD

*UVA Health, Plastic Surgery
Charlottesville, VA*

INTRODUCTION

Many patients who undergo upper extremity amputations suffer from unrelenting pain, from phantom limb pain to persistent nerve pain due to neuromas. Targeted muscle reinnervation (TMR), first described by Dumanian and Kuiken, involves taking amputated nerves without muscle targets and coapting them to stump muscles that do not have a residual function. This allows the amputated nerves to send signals to its new coapted recipient, limiting neuroma formation and phantom limb pain. Additionally, the distal nerve signal is amplified with an increase in independent muscle signals allowing for improved myoelectric prosthetic control.

CASE PRESENTATION

MC is an 18-year-old female who sustained a non-accidental acetaminophen overdose, and subsequent need for ECMO and pressor support. This led to ischemic changes to nose, bilateral lower extremities and bilateral forearms, wrists, and hands. She was weaned from pressors and decannulated from ECMO. Both hands subsequently showed ischemia through the

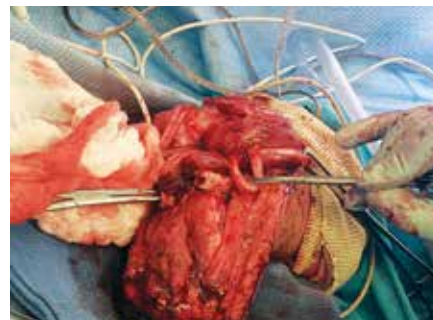


Figure. After amputation of necrotic muscle, bone and skin, the median nerve is coapted to the motor nerve to FDS using 9-0 nylon, without tension as shown by the dissection scissors. It will lie between FDS and FDP with adequate muscle coverage over the distal radius and ulna stumps.

mid forearms. Her gangrene was allowed to demarcate. She underwent a left transradial amputation with left median nerve coapted to motor branch of FDS, left ulnar nerve coapted to FCU muscle belly and left radial sensory and lateral antebrachial cutaneous nerve buried within FDP muscle belly. She underwent the same procedure on the right one month later.

CONCLUSION

Currently five months out, she has little to no pain and is not currently taking narcotics or gabapentin. She is being fitted for myoelectric prosthesis and can apply makeup without prosthesis without assistance. TMR techniques are easily implemented into amputation surgeries and help patients manage pain first and foremost, and allow better use of myoelectric prosthesis, overall improving independence and quality of life for these patients. ■

1. Souza et al. Targeted muscle reinnervation: A novel approach to postamputation neuroma pain. *Clin Orthop Relat Res.* 2014; 472(10):2984-90.
2. Kuiken et al. Targeted muscle reinnervation for the upper and lower extremity. *Tech Orthop.* 2017; 32(2):109-116.



Gregory Domson, MD

Professor

Orthopaedic Oncology

The Orthopaedic Oncology Division serves patients in the treatment of both benign and malignant tumors of the extremities and pelvis. This area includes tumors that originate in the soft tissues and bone, and tumors that have metastasized from other organs to bone. Dr. Domson has years of experience in treating these rare and complicated conditions in children and adults and divides his time between UVA and VCU in Richmond. ■

Dr. Domson specializes in orthopaedic oncology, caring for patients from all over the state of Virginia with benign and malignant, bone and soft tissue tumors of the extremities and pelvis. He treats both pediatric and adult patients. While he works one day a week at UVA and has for 10 years, he lives in Richmond and works full time at VCU as a musculoskeletal tumor specialist as well as Program Director for the Orthopedic Residency Program.

Dr. Domson was an Echols Scholar at UVA, graduating in 1996, before moving on to Eastern Virginia Medical School, where he graduated in 2000. He finished his orthopaedic residency at VCU in 2005 and completed a musculoskeletal tumor fellowship at the University of Florida in 2006. He received a master's in adult education from VCU in 2013, and most of his current research focuses on resident training and education. He is a fellow of the American Academy of Orthopaedics, a fellow of the American Orthopaedic Association, and a member of the Musculoskeletal Tumor Society.





Mark F. Abel, MD

Charles J. Frankel Professor Emeritus



Keith R. Bachmann, MD

Assistant Professor and
Associate Residency Director



Leigh Ann Lather, MD

Associate Professor

Dr. Mark Abel, Charles Frankel Emeritus Professor of Orthopaedic Surgery, retired from clinical practice on December 31st, 2020, after over 27 years of service. During his tenure, he cultivated a national reputation as a Pediatric Orthopaedic Surgeon with particular expertise in the management of children with spinal deformities and for managing motor disabilities in children with cerebral palsy. Through his research and involvement in national study groups, he was instrumental in improving the treatment of scoliosis through surgery, bracing and casting. His influential work has been published in over 105 peer-reviewed articles and 18 textbook chapters on pediatric orthopaedic topics. He was been listed among Connelly's Best Doctors in America for 15 consecutive years.

Dr. Abel attended Tulane University Medical School then completed an internship in General Surgery at Washington University, St. Louis, followed by Orthopaedic Surgical training at the University of California, San Diego, including a fellowship in Pediatric Orthopaedic Surgery at the San Diego Rady Children's Hospital.

Dr. Abel served in the Navy at the Portsmouth Naval Hospital and was deployed with the 2nd Marine Division for Operation Desert Storm in 1989. He joined the UVA Health System in 1993 and served in numerous leadership roles including chair of the department of Orthopaedic Surgery between 2002 and 2003 and from August of 2008 through August 2013. He has served on numerous hospital and School of Medicine committees overseeing promotions, hiring, quality and strategy. In retirement, he will continue to assist the department with Faculty Development, a role he has successfully overseen for the past 8 years.

Dr. Keith Bachmann was born in Newark, Ohio, but moved to Richmond, Virginia, with his family before elementary school. He then attended the University of Virginia as an undergrad where he met his wife Anne. Dr. Bachmann went back to Richmond for medical school at MCV and then moved to Cleveland for his residency at the Cleveland Clinic. He completed his fellowship in pediatric orthopaedics and scoliosis surgery at Rady Children's Hospital in San Diego. Dr. Bachmann began working at the University of Virginia upon completion of his fellowship in August 2016. His practice includes musculoskeletal surgery for children, especially those with spinal deformity.

Locally, Dr. Bachmann serves on the UVA children's surgical performance improvement committee. He is active in the Virginia Orthopaedic Society, moderating panels and serving on committees through the Pediatric Orthopaedic Society of North America (POSNA) and the Scoliosis Research Society (SRS). Dr. Bachmann is a member of the Harms Study Group working to further scoliosis care through longitudinal outcomes collection. His research focuses on patient outcomes and working to improve the metrics used to measure these outcomes. He is also interested in the long term effect and need for surgical treatment for spinal disorders.

Outside of work Dr. Bachmann and his wife like to travel, hopefully to destinations with scuba diving. They have three sons, a dog and a cat. Dr. Bachmann tries to stay involved with mountain biking, golf, and scuba diving. He is a fan of University of Virginia collegiate sports, and Cleveland-based professional sports teams.

Dr. Leigh Ann Lather was born in Minneapolis, Minnesota, and grew up in Iowa, New Jersey, and England. She majored in Psychology at Duke University and graduated with Honors from UNC Chapel Hill School of Medicine.

Dr. Lather specializes in general orthopaedic care for children ages newborn through 18 years. She originally trained as a pediatrician and completed her residency and served as Chief Resident at UVA before entering private practice pediatrics in rural North Carolina for 13 years. She returned to UVA in 2012 to complete a Fellowship in Non-Operative Pediatric Orthopaedics/Musculoskeletal Medicine and then joined the orthopaedic faculty. Dr. Lather sees patients three days per week at UVA Children's Hospital Clinics and one day each week at UVA Zion Crossroads. She teaches medical students and residents from the Departments of Orthopaedics, Pediatrics, Family Medicine, and PM&R, as well as her colleagues in practice who care for children in this region and nationwide.

Dr. Lather serves as the Medical Leader of the 4th floor Women's and Children's Hospital Clinics. She is also involved nationally with a network of other non-operative pediatric orthopedists at large pediatric teaching hospitals across the US. She is proud to be actively engaged in the evolution of this new specialty that fills a growing need in pediatric medical care.

When she is not working, she wants to be with her children, family, and friends. She loves hiking in the Blue Ridge, reading books that are entirely fictional, and practicing Nia and yoga. She also needlepoints, happily carrying on a tradition among the women of her mother's family.



Mark J. Romness, MD*

Associate Professor

Dr. Mark Romness is Associate Professor of the Department of Orthopaedic Surgery with secondary appointment in the Department of Pediatrics. The dual appointment highlights his commitment to Pediatric Orthopaedics and the unique care that children encompass compared to adults. His clinical and academic expertise includes children with special needs such as cerebral palsy and spina bifida which incorporates his other interests of extremity problems such as hip, knee and foot disorders. Rare disorders of childhood such as osteogenesis imperfecta, congenital pseudarthrosis of the tibia and genetics syndromes are additional areas of interest and expertise.

Dr. Romness has served on the Board of Directors for the American Academy for Cerebral Palsy and Developmental Medicine, been President of the Virginia Orthopaedic Society and is a long standing member of Pediatric Orthopaedic Society of North America. Within the Orthopaedic Department, Dr. Romness serves as Division Head of Pediatrics, a member of the Resident Advocacy Committee and Medical Student Clinical Supervisor. He is also Medical Director of the Motion Analysis and Motor Performance Lab which is internationally recognized for clinical evaluations of patients with cerebral palsy.

Dr. Romness grew up in Arlington, Virginia, and has been in practice for more than 25 years, joining the University of Virginia in 2004 after practicing at children's hospitals in Connecticut and Fairfax, Virginia. Education was at the College of William and Mary and then Northwestern University for medical school and orthopaedic residency. He spent one year for fellowship in pediatric orthopaedics at the Royal Children's Hospital in Melbourne, Australia. He is married to Christine Romness and they have three grown children.

Vertebral Body Tethering

Keith Bachmann, MD

*University of Virginia,
Department of Orthopaedic Surgery
Charlottesville, VA*

Growth modulation is moving into the pediatric spine care realm. Scoliosis has been known from anatomic specimens to cause lordosis, hypothesized to be from relative anterior overgrowth of the

spine. More recently this has been confirmed with three-dimensional modeling using slot-scanning imaging technology. The principles of growth modulation can now be harnessed to correct scoliosis without spinal fusion. The Tether from Zimmer (see Figures 1 and 2) gained humanitarian device exemption from the FDA and once surgeons go through appropriate training and certification they can deploy this technique. Fortunately Drs. Bachmann and Singla both participated in Tether surgery-



Figure 1. The Tether Cord being inserted into the screw heads in a model spine.

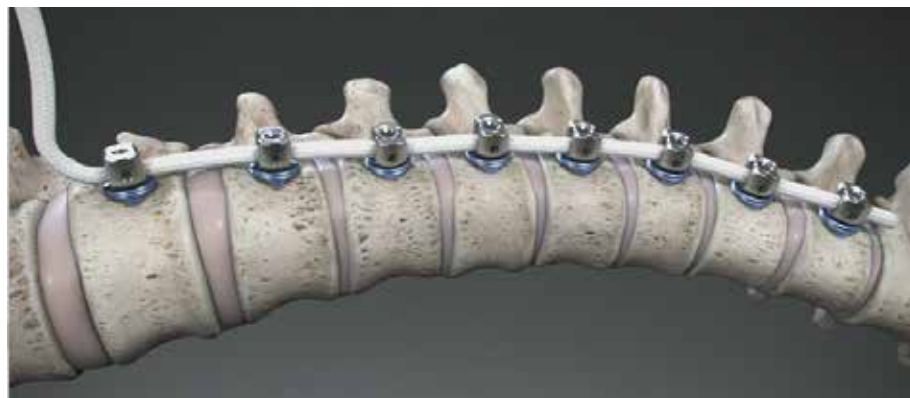

Figure 2. The Tether Cord on the convexity of a model spine. Tension is applied through the cord to create initial correction of the scoliosis and then continued growth modulation due to compression.

ies during fellowships at Rady Children’s Hospital (Bachmann) and the Shriner’s Hospital in Philadelphia (Singla). The technique is most useful for patients with a surgical magnitude curve (> 50 degrees) who have growth remaining. Early results are promising and through our participation in the Harms Study Group we remain on the forefront of scoliosis care.

Another emerging non-fusion method for scoliosis care is the ApiFix device from OrthoPediatrics. This originated in Israel and like The Tether has a humanitarian use device exemption from the FDA. This is a posterior based device with polyaxial movement of the device to the spine and then



Figure 3. The ApiFix device with ratcheting expansion and polyaxial attachment to the spine.

concave distraction (see Figures 3 and 4). Good candidates include those with operative curve magnitudes and flexible curves as measured on bending x-rays. Since there is no growth modulation, age is less of a

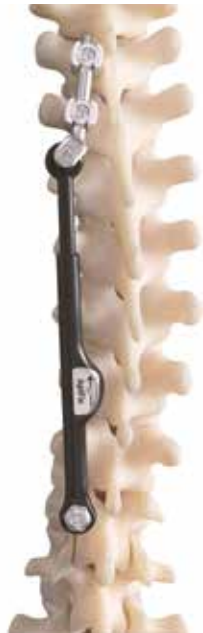

Figure 4. The ApiFix attached to a spine model demonstrating the polyaxial superior connection and elongation of the device in the concavity of the spine.

variable for ApiFix although flexibility is needed and this may be impacted by age.

Both of these devices allow for improved post-operative motion when comparing to posterior spinal fusion with potential tradeoffs for curve correction especially axial. There are unknowns for long term results in both techniques. As part of the humanitarian device exemption these patients must be followed in a registry. Our Tether registry is a component of the Harms Study Group and here at UVA we are one of the first 20 nationwide sites for the ApiFix registry through the Pediatric Spine Study Group.

In the realm of early onset scoliosis we are happy to be a participating site comparing casting vs. bracing for early onset scoliosis. Following on their success organizing the BRAIST trial in adolescent idiopathic scoliosis, a team of researchers out of the University of Iowa are hoping to compare casting to bracing for early onset scoliosis care. We are excited to be a research site for this important trial at UVA continuing to advance spine care for pediatric patients. ■

Growth Tether for Leg Deformities

Mark Romness, MD

University of Virginia,
Department of Orthopaedic Surgery
Charlottesville, VA

Similar to spine tethering, growth modulation is used for limb malalignment utilizing the untethered portion of the physis to gradually correct the deformity. Gradual correction has many benefits over a corrective osteotomy and the development of tension band plates (TBPs) as an evolution

from staples has proven to be very effective and safe. Compared to osteotomy, the surgical procedure takes less time, is less invasive, does not require immobilization nor weight bearing restrictions and gives gradual correction which is safer for the soft tissues and neurovascular structures. Growth remaining in the physis is required which can lead to unpredictable response and correction but coronal plane correction is fairly well defined with a healthy physis. Pathologic causes of deformity are less predictable but still felt to be a better initial treatment than osteotomy which can always be done later if full correc-

tion is not obtained by growth modulation. Even some correction with the tether makes the definitive osteotomy less extensive. Figure 1 shows the correction of Blount’s with a TBP preventing the need for osteotomy.

The advantages over staples includes less injury to the ring perichondrium, less breakage and easier removal. There is also felt to be a mechanical advantage of TBPs over staples for faster correction of the deformity. There has been concern for permanent arrest by TBPs leading to overcorrection, but one study with > 650 procedures found no unintended physeal arrests and case reports of arrest have not been published.

In patients close to skeletal maturity, percutaneous permanent hemiepiphyseodesis is

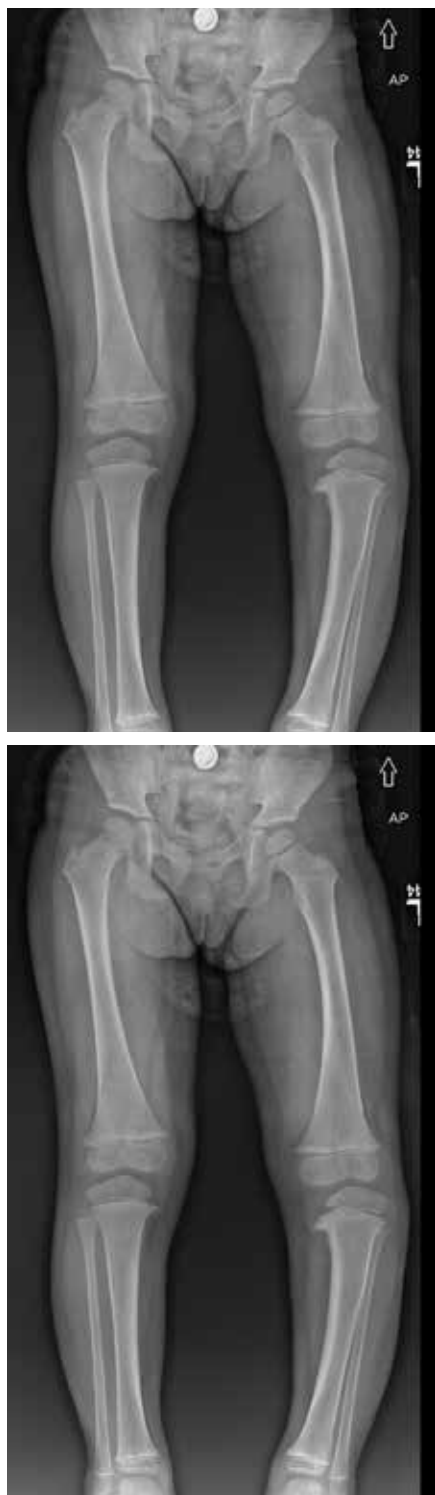

Figure 1. 3-year-old female with left tibia vara – Blount’s disease. Early changes at the left proximal tibia with significant varus of the mechanical axis. 18 months after tension band plate, there is correction of the axis and improvement of the ossification of the proximal tibia. Plate removal was done after this image and growth has remained normal over the two years since removal.

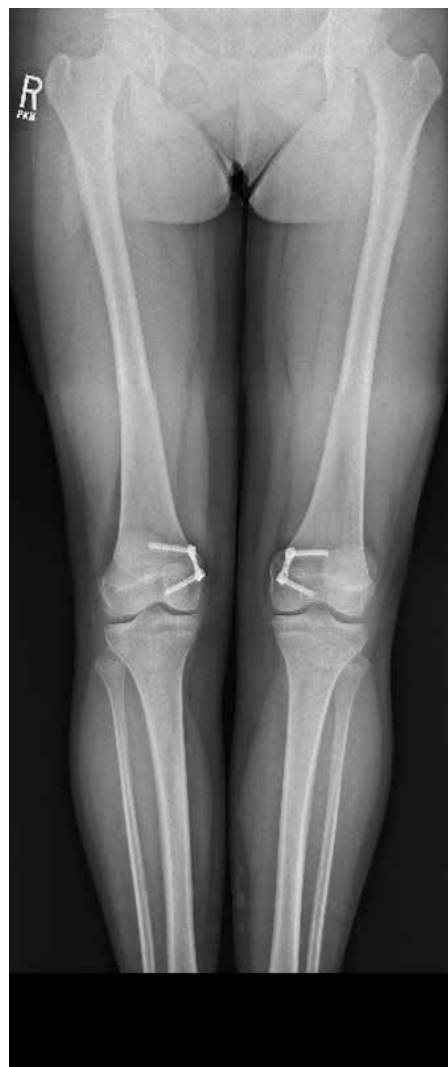
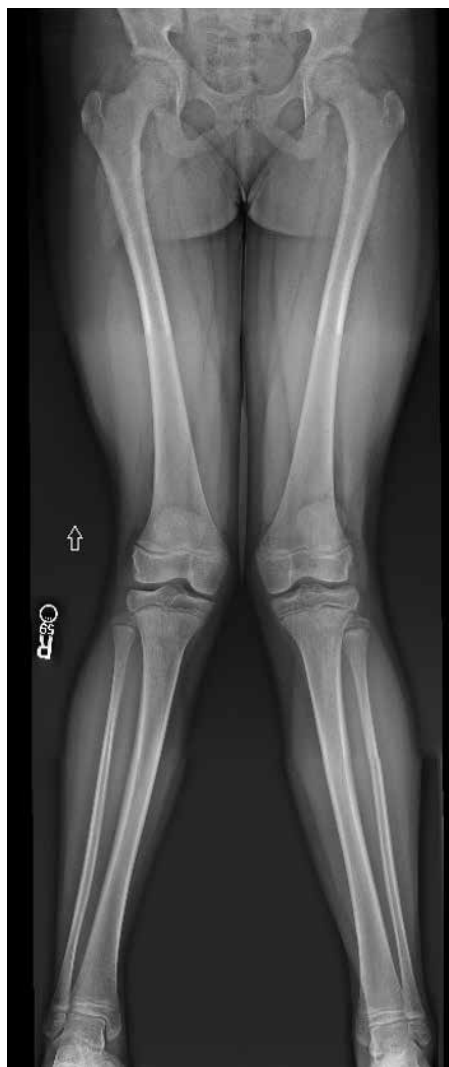
Figure 2. 9-year-old female with bilateral genu valgum and right-sided medial knee pain. 19 months after medial tension band plates, correction was obtained with varus clinically and no knee pain other than slight tenderness over the plates. Plates were removed to prevent overcorrection.

still the preferred method as no implants are needed. Unfortunately timing for the procedure is difficult to calculate despite various attempts to quantitate or formulate the growth remaining. The unpredictability of permanent arrest supports treatment at an earlier age for more extreme deformities. The safety and efficacy has also lead to more indications to correct less pathologic deformities such as genu valgum. Figure 2 shows correction of genu valgum for a patient who had mild but persistent knee pain. Not only was her pain relieved but the long term benefits should help delay her knee arthroplasty surgery.

In addition to coronal plane deformities, we have used TBPs to correct sagittal plane deformities such as knee flexion contractures and ankle equinus primarily for children with neuromuscular conditions such as cerebral palsy and myelomeningocele. As is typical with this population of patients, there is a higher complication rate and they are not as effective as in the coronal plane with a healthy physis. Despite the risks, gradual correction is very beneficial in the sagittal plane to overpower the soft tissue resistance of these contractures with a minimally invasive procedure. ■



Michele E. Bryant, MS, ATC, CO*

Technical Director

Michele grew up in Maryland and started her college career at High Point University, where she graduated with a B.S. in Sports Medicine and became a Certified Athletic Trainer. She worked for the University of Tennessee Athletic Training Department while earning her Master's Degree in Exercise Science/Biomechanics. Michele enjoyed working with the team specialists on lower extremity biomechanics and bracing, and she went on to earn a degree in Orthotics from Northwestern University. After completing her Orthotics Residency at the Cleveland Clinic, Michele went on to work at the University of North Carolina Hospital as a Certified Orthotist.

Michele joined UVA Prosthetics & Orthotics in 2014 and became the Assistant Technical Director in 2017. Michele is a resident mentor for the profession—educating students and patients. She has served on the Cranial and Gait Societies of AAOP. She is a member of the AOPA Coding and Reimbursement Committee and has been involved in AOPA Policy Legislative Forums to advocate for the needs of the profession and the patients it serves.

In her free time, Michele enjoys exercising, crafting, reading, creating Halloween costumes, spending time outside at the beach, in the mountains, and at the local parks with her husband and their dog.

Prosthetics and Orthotics

Above and Below Knee Prosthetics from Computer-aided Design (CAD)

- UVA Prosthetics and Orthotics has shifted to a digital workflow for a large majority of their lower extremity prosthetic care. We have designed digital workflow processes internally which are teachable and repeatable. CAD scans are highly accurate and modifications done in CAD software are more efficient with more powerful tools available.
- Our workflow and techniques for transfemoral amputees are unique to UVA and have helped improve fit, accuracy, and efficiency. Where most of the field uses transfemoral templates to create the shapes due to the difficulty of getting a full transfemoral scan, we have devised a way to get extremely accurate full scans and modify these for the best possible fit and outcome for the patient.

Custom Prosthetic Liners From CAD

Unique residual limb shapes with significant scarring or bony prominences often require a level of care that is not easily achieved without the use of digital technology. For these unique limb shapes we have devised CAD scanning techniques unique to UVA which allows us to design custom gel liner interfaces to protect the soft tissue for these difficult to fit patients.

Injection Molded Distal End Pads for Amputees

Some amputee patients require custom made silicone pads that they can either wear under their gel liners or that reside in the bottom of the prosthesis to protect sharp bony prominences. This had been achieved by making direct injection molds

from the patient's residual limb. Recently we have combined these techniques with our CAD scanning and modifying to create some truly unique fitting solutions for difficult to fit patients.

Having these techniques available for use on appropriate patients can save them time in travel and visits, decrease time to start prosthetic rehab in therapy, and get patients moving quicker thereby reducing deconditioning that can occur from not being able to ambulate

Direct Socket

Traditional fabrication techniques for prosthetics can take 4-6 weeks and 4-6 visits for patients to get the correct socket shape and fit for patients. Our staff has been training on direct prosthetic fabrication techniques which allow us to fabricate a prosthesis for a patient in a single visit. The unique situation and location of UVA means that many patients travel long distances to receive care. Having these techniques available for use on appropriate patients can save them time in travel and visits, decrease time to start prosthetic rehab in therapy, and get patients moving quicker thereby reducing deconditioning that can occur from not being able to ambulate.

Adjustable Sockets (BOA® and M2 Buckles)

We have begun incorporating BOA® tensioning device technology and ratchet buckles into certain prosthetic sockets to allow for adjustable sockets for patients that have issues with limb volume management.

Reaktiv AFOs

We have been using dynamically tuned bracing systems like the Fabtech Reaktiv for limb salvage patients and other patients that need significant axial unloading of the foot and ankle. Original designs for these style AFOs were restricted to certain areas of the country

meaning that patients had to travel hundreds of miles for this care. Being able to offer these options locally has made UVA P&O a hub in the mid-atlantic region for this care.

CAD Scans for Foot Orthotics and Shoes
UVA P&O has been using CAD technol-

ogy on the orthotic side of our practice to improve fit and reduce turn-around time for both foot orthotics and shoes. A patient's feet can be scanned with an iPad-mounted scanner and the scan can be directly uploaded to the manufacturers to streamline the ordering process for these devices. ■

PROSTHETICS & ORTHOTICS PROVIDERS



Michele E. Bryant
MS, ATC, CO
Technical Director
Senior Certified Orthotist



Jordyn Rine
MS, ATC, CFo, CES
Certified Orthotic Fitter



Meagan Salehin
BS, CPed, CFo
Certified Pedorthist and
Certified Orthotic Fitter



Alexander Ashoff
CP, MSPO
Certified Prosthetist



Wesley Sprouse
CPOA, CTP, CFo
Certified Prosthetic
Orthotic Assistant



Aceline Alusca
MSOP, CPO
Certified Prosthetist Orthotist




Chad Bryant
CTP
Certified Prosthetic Technician



Dwayne Strong
CPO
Certified Prosthetist Orthotist



Michael Martinez
CPOA, CTO, CFo, Cped
Certified Orthotic Technician
Assistant & Pedorthist



James Tilton
CPO
Certified Prosthetist Orthotist



David Carmines
CTO
Certified Orthotic Technician



Bryan Foster
CPed, CFo
Certified Pedorthist and
Certified Orthotic Fitter



Joe McMillian
Orthotic Technician



Gracyn Smythe
Orthotic Fitter



George J. Christ, PhD

Professor

Dr. Christ is a Professor of Biomedical Engineering and Orthopaedic Surgery. He is Co-Director of the Center for Advanced Biomanufacturing. He is the Past Chairman of the Division of Systems and Integrative Pharmacology of the American Society of Pharmacology and Experimental Therapeutics (ASPET), and Past President of the North Carolina Tissue Engineering and Regenerative Medicine (NCTERM) group. He was inducted into AIMBE in 2017. He serves on the Executive Committee of the Division for Integrative Systems, Translational and Clinical Pharmacology of ASPET. He is a member of the Regenerative Rehabilitation Consortium Leadership Council and serves on the Leadership Advisory Council for ARMI/BioFabUSA. He received the Ray Fuller Award and Lecture (ASPET, 2018). He serves on the Editorial Board of five journals and is an ad-hoc reviewer for 2 dozen others. Dr. Christ has authored more than 225 scientific publications and is co-editor of a book on integrative smooth muscle physiology and another on regenerative pharmacology.

Dr. Christ has served on both national and international committees related to his expertise in muscle physiology, and on NIH study sections in the NIDDK, NICHD, NCRR, NIAID, NIAMS, and NHLBI. He has chaired working groups for both the NIH and the WHO and is co-inventor on more than 26 patents (national and international) either issued or pending. Dr. Christ is also spearheading several MSK-applicable translational research programs to develop novel regenerative medicine treatments for orthopaedic patients, in particular, volumetric muscle loss injuries. He leads a DOD-funded multi-institutional program for the development of a tissue-engineered muscle repair (TEMR) technology platform for the treatment of Wounded Warriors and collaborates in another NIH and DOD funded translational multi-institutional effort as part of the C-DOCTOR consortium. Funding from the DOD and Keratin Biosciences also supports the evaluation of a proprietary hydrogel for the treatment of lower extremity traumatic injuries.



Wendy Novicoff, PhD

Professor

Wendy Novicoff, Ph.D. is a Professor of Orthopaedic Surgery and Public Health Sciences at the University of Virginia School of Medicine and serves as the Director of Clinical Trials for Orthopaedic Surgery. She grew up in Omaha, Nebraska, and came to the East Coast for college, receiving her undergraduate degree at Duke University and her graduate degrees from the University of Virginia. Wendy works with many groups at the University of Virginia, including serving as Faculty for the School of Data Science, as the Education Director for the Be Safe Program (UVA's patient safety program), as the lead Evaluator for UVA's Clinical and Translational Science Award program, and as Program Director for both the Master of Science in Clinical Research and the Graduate Certificate in Public Health Sciences programs.

Wendy is very involved in local theater and serves on the Boards of the Four County Players and the Virginia Theatre Association. She also performs in several shows each year. In her spare time, Wendy enjoys spending time with her husband and their very fluffy cats.



Shawn D. Russell, PhD

Associate Professor

Shawn D. Russell, PhD, was born in Omaha, Nebraska. As the son of a military family, he has lived all over: Texas, Hawaii, New York, and Virginia. After graduating from Hampton Roads Academy, he attended Virginia Tech, where he graduated with a B.S. in Mechanical Engineering, and a B.S. in Engineering Science and Mechanics. After graduation he enrolled in graduate school at the University of Virginia where he earned an M.S. in Biomedical Engineering, and a PhD in Mechanical Engineering.

He is currently the director of the Motion Analysis and Motor Performance Laboratory at the University of Virginia, oversees the day to day research operations of the laboratory and guides data collection and analysis. He has been conducting research using motion analysis for the last 18 years. This work has included the detection of motion events and the quantification of the kinetics and kinematics associated with tasks including: simple typically developed walking, pathological walking with and without assistive devices, scaling rock climbing walls, and predictive modeling of human movements. In addition, his work is developing methods for detection, measure, and recognition of human movement in out of lab environments using state of the art IMU technology. More recently he has begun developing models and methods for the analysis of gait function in Lewis rats used in preclinical trials. These methods have enabled him to begin quantifying the effects of musculoskeletal injury and applied therapeutics on the movement function quality of their gait characteristics.

In his free time he enjoys spending time with his wife, Heather, and his two boys, Dylan and Ethan. He also enjoys whitewater kayaking, mountain biking, and teaching adaptive skiing with Wintergreen Adaptive Sports.

Orthopaedics Research

George J. Christ, PhD

University of Virginia,
Department of Orthopaedic Surgery
Charlottesville, VA

UNMET MEDICAL NEED FOR SKELETAL MUSCLE REPAIR

A major focus of our Basic and Translational Research efforts in Orthopaedic Surgery is addressing the unmet medical need for tissue engineering (TE) and regenerative medicine (RM) approaches to skeletal muscle repair and replacement. Permanent loss of muscle mass, structure and function is referred to as a volumetric muscle loss (VML) injury, and there are many traumatic injuries that result in irrecoverable loss of muscle form and function in Warfighters and civilians. Such injuries exceed innate regenerative capacity, and this is reflected in the devastating impact of battlefield extremity trauma on the quality of life and retention of injured Servicemembers. In fact, there are > 53,000 Warfighters wounded in action in recent conflicts (DoD Casualty Status). With an average age of ≈26yo (Owens et al., 2008), VML injuries have a prolonged disabling impact, often requiring multiple surgical interventions with generally poor cosmetic and functional outcomes.

INNOVATIVE THERAPEUTICS FOR IMPROVED VML REPAIR Cells, Gels and Combinations for Musculoskeletal Repair

The goal of our highly collaborative research program is development of more effective TE & RM solutions for skeletal muscle repair and regeneration in both the civilian and military populations. At the center of



OPERATION IRAQI FREEDOM U.S. CASUALTY STATUS ¹					
	Total Deaths	KIA	Non-Hostile	Pending	WIA
OIF U.S. Military Casualties	4,418	3,481	937	0	31,994
OIF U.S. DOD Civilian Casualties	13	9	4	0	
Totals	4,431	3,490	941	0	31,994

¹ OPERATION IRAQI FREEDOM includes casualties that occurred between March 19, 2003, and Aug. 31, 2010, in the Arabian Sea, Bahrain, Gulf of Aden, Gulf of Oman, Iraq, Kuwait, Oman, Persian Gulf, Qatar, Red Sea, Saudi Arabia and the United Arab Emirates. Casualties in these countries before March 19, 2003, were considered Operation Enduring Freedom. Personnel injured in OIF who die after Sept. 1, 2010, will be included in OIF statistics.

OPERATION NEW DAWN U.S. CASUALTY STATUS ²					
	Total Deaths	KIA	Non-Hostile	Pending	WIA
OND U.S. Military Casualties	74	38	36	0	298
OND U.S. DOD Civilian Casualties	0	0	0	0	
Totals	74	38	36	0	298

² OPERATION NEW DAWN includes casualties that occurred between Sept. 1, 2010, and Dec. 31, 2011, in the Arabian Sea, Bahrain, Gulf of Aden, Gulf of Oman, Iraq, Kuwait, Oman, Persian Gulf, Qatar, Red Sea, Saudi Arabia and the United Arab Emirates. Personnel injured in OND who die after Dec. 31, 2011, will be included in OND statistics.

OPERATION ENDURING FREEDOM U.S. CASUALTY STATUS ^{3,4}					
	Total Deaths	KIA	Non-Hostile	Pending	WIA
OEF U.S. Military Casualties	2,218	1,833	385	1	20,093
Afghanistan Only 3					
Other Locations 4	130	12	118	0	56
OEF U.S. DOD Civilian Casualties	4	2	2	0	
Worldwide Total	2,352	1,847	505	1	20,149

OPERATION INHERENT RESOLVE U.S. CASUALTY STATUS ⁵					
	Total Deaths	KIA	Non-Hostile	Pending	WIA
OIR U.S. Military Casualties	106	20	86	0	270
OIR U.S. DOD Civilian Casualties	2	0	2	0	
Totals	108	20	88	0	270

⁵ OPERATION INHERENT RESOLVE includes casualties that occurred in Bahrain, Cyprus, Egypt, Iraq, Israel, Jordan, Kuwait, Lebanon, Qatar, Saudi Arabia, Syria, Turkey, the United Arab Emirates, the Mediterranean Sea east of 25° longitude, the Persian Gulf and the Red Sea.

OPERATION FREEDOM'S SENTINEL U.S. CASUALTY STATUS ⁶					
	Total Deaths	KIA	Non-Hostile	Pending	WIA
OFS U.S. Military Casualties	107	77	30	0	612
OFS U.S. DOD Civilian Casualties	2	2	0	0	
Totals	109	79	30	0	612

³ OPERATION ENDURING FREEDOM (Afghanistan only) includes casualties that occurred between Oct. 7, 2001, and Dec. 31, 2014, in Afghanistan only.

⁴ OPERATION ENDURING FREEDOM (other locations) includes casualties that occurred between Oct. 7, 2001, and Dec. 31, 2014, in Guantanamo Bay (Cuba), Djibouti, Eritrea, Ethiopia, Jordan, Kenya, Kyrgyzstan, Pakistan, Philippines, Seychelles, Sudan, Tajikistan, Turkey, Uzbekistan and Yemen. Wounded in action cases in this category include those without a casualty country listed.

⁶ OPERATION FREEDOM'S SENTINEL includes casualties that occurred in Afghanistan after Dec. 31, 2014.

this research program is DoD funding for the Armed Forces Institute for Regenerative Medicine (AFIRM), which I have been involved in since the initial funding of the AFIRM 1 consortium in 2008, through

re-funding of an AFIRM 2 consortium in 2013, and most recently, the funding of AFIRM 3 in late 2020. For the third renewal of AFIRM (AFIRM 3), UVA is the primary site for a synergistic, multi-institu-

tional collaboration that has partners in the DoD (USUHS/WRNMMC), Academic (UVA, UC-Berkeley, U-Michigan), Industrial (Keranetics, Integra LifeSciences), and the Not-for-Profit (ARMI/BioFabUSA) sectors. Total funding for this interdisciplinary collaborative research program is > \$2.1M (funded through 2025). The overarching goal of AFIRM 3, further leveraged by other ongoing DoD (USAMRAA) and NIH (NIDCR) funded projects, is imple-

This integrated, cost-share facility is open to users in all Schools at UVA, and again, will be a key factor in accelerating development and implementation of novel therapeutics for musculoskeletal injuries. We continue to build, expand and scale the ecosystem of collaborators and partners from the academic, government, not-for-profit and industrial sectors.

mentation of advanced hydrogel and tissue engineering technologies for scaling and improving treatment of the most devastating VML injuries to wounded warriors. In addition, we are evaluating a combination of hydrogels with other advanced TE technologies developed at UVA, Wake Forest and

U-Michigan. Most recently, we have received notice of funding approval for a grant from the Joint Warfighter Medical Research Program (JWMP), that will provide ≈\$3.6M to support late-stage GMP-like manufacturing and regulatory development of a hyaluronic acid-based hydrogel sponge form factor for treatment of extremity VML trauma. The pilot clinical studies are planned in the Orthopaedics Dept. at UVA. Moreover, the multiscale biomechanical mechanistic evaluation of the efficacy of these technologies, as well as their continued clinical translation involves key faculty in Orthopaedics (Drs. David Weiss, Wendy Novicoff, Brian Werner, Bobby Chhabra, Shawn Russell), as well as in Biomedical Engineering (Drs. Silvia Blemker (BME) and Shayn Pierce-Cottler).

ADVANCED BIOMANUFACTURING AT UVA FOR MUSCULOSKELETAL REPAIR

Finally, we are fully engaged in advanced biomanufacturing for musculoskeletal repair. The Center for Advanced Biomanufacturing (CAD-Bio) at UVA has more than 2 dozen participating faculty across nearly a dozen departments, and was created through a \$3M Strategic Investment Fund (SIF) award by UVA. I am the Co-Director (with Dr. Shayn Peirce-Cottler) of CAD-Bio, which was created to broadly support development of cells, gels

and soft materials for biological applications—which, of course, is also directly relevant to accelerating creation of novel and more effective regenerative therapeutics for musculoskeletal repair. In addition, UVA has invested in a brand new state-of-the-art facility to support Innovations in Fabrication (IFAB)—an effort spearheaded by Art Lichtenberger (ECE) and supported by numerous faculty across Grounds. IFAB is devoted to Multifunctional Microfabrication and Scalable Biomanufacturing and was funded by a total of »\$30M in UVA investments. This integrated, cost-share facility is open to users in all Schools at UVA, and again, will be a key factor in accelerating development and implementation of novel therapeutics for musculoskeletal injuries. We continue to build, expand and scale the ecosystem of collaborators and partners from the academic, government, not-for-profit and industrial sectors. All of this is occurring in parallel to the grand opening of the UVA Orthopedic Center on Ivy Road (200,000 sq.ft.; \$185M). Through all these recent initiatives, collaborations, and funding, we are building a highly collaborative and end-to-end translational research consortium that can rapidly innovate and provide novel and more efficacious regenerative therapeutics for musculoskeletal repair. ■



Xudong (Joshua) Li, MD, PhD

Associate Professor

Dr. Joshua Li was born and grew up in China. He attended Xi'an Medical University for both his MD and PhD. He came to the United States in 1999.

Dr. Li holds dual appointments as Associate Professor in the departments of Orthopaedic Surgery and Biomedical Engineering at UVA. He completed an Orthopaedic Surgery residency at UVA, and a comprehensive Spine Surgery fellowship at the world-renowned Columbia Spine Hospital with Drs. Lenke, Riew and Lehman. Dr. Li has advanced expertise in a wide range of spinal procedures from microscope-assisted cervical artificial disc replacement, to single position OLIF, to the most complex spinal reconstruction for scoliosis. His clinical interests include degenerative disorders of the cervical, thoracic, and lumbar spine (herniated disc, spinal stenosis, etc.), spinal deformities (scoliosis, kyphosis, flatback syndrome, etc.), spinal tumors, metastatic spine disease, spine trauma, minimally invasive spine surgery, robotic assisted spine surgery, and motion-sparing technology (artificial disc replacement).

Dr. Li has developed a renowned laboratory that focuses on intervertebral disc degeneration pathology and treatment with stem cells, nanotechnology, and gene therapy. He has been the recipient of over 30 grants as the Principle Investigator, including five NIH (National Institute of Health R03, R21s, and R01) grants. He serves as a committee member for the Orthopaedic Research Society (ORS), and the North American Spine Society (NASS). He has been on various grant review panels including those for the NIH, NASA, MTF, and AO-International.



Francis H. Shen, MD*

Warren G. Stamp Professor
Vice Chair for Faculty Development

Dr. Francis H. Shen is the Warren G. Stamp Endowed Professor of Orthopaedic Surgery, Professor of Pediatrics, Head of the Division of Spine, and Co-Director of the Spine Center. He earned his biomedical engineering degree from the University of Michigan and completed his orthopaedic residency training at the University of Virginia. He completed fellowship training in Spine at Rush University, Pediatric Spinal Deformity training at Shriners Hospitals for Children in Chicago and an Orthopaedic Research Fellowship at the University of Virginia. He was selected as a Scoliosis Research Society Traveling Fellow and as a North American Spine Society Traveling Fellow.

His clinical practice includes the management of degenerative conditions, spinal deformity, trauma, tumors, and spine infections. He utilizes open surgical techniques but specializes in cutting-edge minimally invasive surgery, image-guided spine surgery, and microsurgery. He performed the first robotic-assisted spine surgery and the first robotic-assisted computer image-guided surgery at UVA. He has been recognized as a Top Doctor by *US News & World Report* and *Castle Connolly Top Physicians* and has been profiled by *Becker's Spine Review*. He has developed several novel surgical techniques.

His research is focused on improving the future of patient care by applying tissue engineering principles to solve clinically relevant problems. He is the Director of the American Academy of Orthopaedic Surgeon Board Review Course, Board Examiner for the American Board of Orthopaedic Surgeons, and Editorial Board Member for the *Spine Journal*, *SPINE*, *European Spine Journal*, and *SpineLine*. He has served on the AOSpine Foundation Board and the Cervical Spine Society Executive Board and is an International Meeting on Advanced Spine Techniques Program member. He is a multiple-time award recipient for Outstanding Basic Science Paper and Outstanding Clinical Paper in the *Spine Journal*. He has received over 20 Young Investigator Awards, Career Development Grants, and Foundation Awards.



Adam L. Shimer, MD

Associate Professor

Dr. Adam L. Shimer is an Associate Professor of Orthopaedic Spine Surgery at the University of Virginia. He was also Fellowship Director for the Orthopaedic Surgery of the Spine Fellowship from 2018-2019. Additionally, Dr. Shimer is the Spine doctor for both University of Virginia and James Madison University Athletics. Dr. Shimer's training started with college at UVA, followed by medical school at UVA and Orthopaedic Surgery residency at University of Pittsburgh Medical Center. He completed an Orthopaedic Research fellowship at UPMC focused on cellular- and gene-based therapy for intervertebral disc repair and regeneration. After his Orthopaedic Spine Fellowship at the Rothman Institute at Thomas Jefferson Hospital in Philadelphia, he joined the UVA faculty in 2009.

Dr. Shimer's practice is focused on complete care of neoplastic, infectious, traumatic, degenerative, and deformity conditions of the spine. He has extensive experience and particular interest in treating complex cervical spine pathology. His research interests include value-based spine care, patient-reported outcome measurements, and complications of spinal surgery.

Dr. Shimer is the Orthopaedic In-Patient Unit Medical Director. He is a member of the Cervical Spine Research Society, American Academy of Orthopaedic Surgeons, North American Spine Society, and the Virginia Orthopaedics Society.



Anuj Singla, MD

Associate Professor

Dr. Anuj Singla was born and grew up in India. He attended medical school and completed his Residency in Orthopaedics in India. He completed fellowships in Pediatric Spine and Orthopaedics/Neurosurgical Spine at LSU, Shriners’s Hospital, and UVA.

He is a comprehensive spine surgeon with a current practice, including both pediatric and adult spine surgery. Dr. Singla joined UVA as a Fellow in 2013 and has been a part of the faculty since 2014. He is a reviewer/editorial board member for top spine journals. He is also an active member of many committees with the Scoliosis Research Society.

Dr. Singla’s clinical and research interests include early-onset scoliosis, fusion-less deformity correction, and patient outcome after spinal surgeries. He has been married to his wife, Priya, for about ten years, and they have two kids.

UVA Orthopaedic Spine

FOREWORD

The Division of Spine Surgery is excited to update our alumni and colleagues with this issue of the *University of Virginia Orthopaedic Journal*. The Spine Division continues to grow and expand, and has extended out impact in all three areas of our mission statement: patient care, spinal research, and resident and fellow education. Last year we provided an update of the wide range of surgical cases that our division provides to our patients. In this issue, we present a few interesting clinical cases, along with an update of ongoing clinical and basic science research. It is clear that our future is bright, and we continue to build on the strengths of our mentors and colleagues before us! On that note, we are proud to announce that Dr. Donald P.K. Chan, past division head and Emeritus Professor was named the award recipient for the 2021 Scoliosis Research Society Lifetime Achievement Award.

UVA Spine Legacy

Dr. Chan Recipient of the Scoliosis Research Society Lifetime Achievement Award

The SRS Lifetime Achievement Award honors an SRS member for long and distinguished service to the Scoliosis Research Society and spinal deformity care overall.

Dr. Donald P. K. Chan has been selected as one of the 2021 SRS Lifetime Achievement Award winners.

Dr. Chan joined University of Virginia where he was Professor and Chief of the Division of Spine Surgery from 1994 to 2004. He is a past President of the SRS (1997-1998). In 2000 Dr. Chan was appointed to the Warren G. Stamp



Dr. Donald P. K. Chan

Professorship in Orthopaedic Surgery at the University of Virginia. There is an endowment under Dr. Chan’s name at University of Virginia, which sponsors visiting professors.

Dr. Chan is acclaimed for his novel surgical techniques and has traveled the world to train other doctors in advanced spinal surgery. Highly regarded for his work in the treatment of patients with scoliosis and other spinal deformities, Dr. Chan has contributed significantly to the procedures of spinal instrumentation and fusion. He was involved in the development of Moiré topography, a technique for acquiring contour images of children’s torsos, to reduce radiation exposure during follow up. He was also involved in developing a machine for monitoring spinal cord function during surgery.

Tumor

Use of Carbon Fiber Implants in Lumbosacral Reconstruction after Tumor Resection: Case Report

CASE PRESENTATION

T.W. is a 25-year-old female comes who was referred to the orthopaedic spine clin-

ic for severe lumbosacral back pain and difficulty with standing and ambulation. Symptoms had been persistent for several months. Imaging demonstrated large, expansile, lytic lesion of the sacrum. Biopsy confirmed giant cell tumor. She was referred to the orthopaedic spine service for definitive management.

On exam, she ambulates with a walker, but only for short distances. Otherwise utilizes wheelchair for any distances. Motor exam is intact, but has weakness with bilateral ankle and plantarflexion. Sensation intact. No bowel or bladder dysfunction.

CT of the lumbar spine demonstrates an expansile, lytic lesion of the sacrum with loss of cortical borders. There is extension of the tumor up to, but not including, the SI joints bilaterally include the sacral ala. MRI of the lumbar spine confirms the large expansile lesion including the body of S1 and S2 with associated soft-tissue mass beyond the confines of the sacrum (Figure 1A, B).

Due to the fact that postoperative surveillance remains vital, we opted for the

use of metal-free carbon fiber implants to allow for improved imaging capabilities to follow for recurrence.

Intraoperatively, all of the sacral nerve roots were identified and isolated (Figure 2A). Immediately postop she had bilateral plantarflexion weakness, sensory dysesthesia, and bowel and bladder dysfunction due to the adjuvant dry ice therapy (Figure 2B and 2C). At 1-year follow up she has the return of her strength and sensation. She is able to ambulate without aids now, and the lumbopelvic reconstruction has improved the instability pain. The use of carbon fiber implants has allowed for serial imaging with little implant artifact.

In the last year, we have been using carbon fiber metal-free implants to help facilitate tumor recurrence and surveillance due to the superior imaging (Figure 3A and B). Limitation of carbon fiber implants remains the difficulty in achieving the appropriate contours due to the fact that current technology does not allow for rod bending and contouring, and therefore can be technically challenging. Furthermore,

long term biomechanical stability of these reconstructions remains to be seen.

Sports Spine Surgery

Minimally-invasive Direct Repair of a Symptomatic Unilateral Pars Defect Using Intraoperative Computed Tomography Scan in an Elite-level Collegiate Athlete

CASE PRESENTATION

A 20-year-old male, college football player presented after 12+ months of progressive midline low back pain, exacerbated by lumbar hyperextension and without radicular symptoms. He was initially seen in a sports medicine clinic and diagnosed with a right L4 spondylolysis without spondylolisthesis. After failing to achieve symptom relief, he was referred to the spine clinic for further evaluation and treatment.

A lumbar MRI re-demonstrated the incomplete right L4 pars interarticularis defect with mild marrow edema in the right L4 pedicle and ruled out any other soft tissue pathology. A single photon emission computed tomography (SPECT) scan was completed which showed bone regeneration activity consistent with a healing stress fracture (Figure. 4A and 4B). After extensive discussions with the patient and his family including discussion of the risks and benefits of all surgical and non-surgical treatment options, it was decided to proceed to direct surgical repair of pars defect due to delayed union and failure to respond to conservative treatment.

The patient's imaging was studied extensively. It appeared that a screw could be placed using the junction of the contralateral lamina and the spinous process as the starting point to achieve this goal. This novel trajectory would allow for a screw angle amenable to percutaneous placement. If using the traditional Buck's method starting point, it would have been

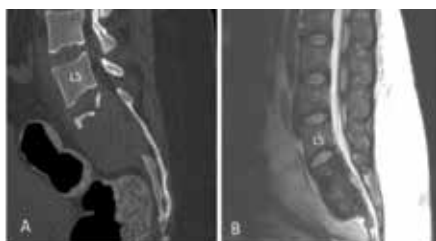

Figure 1. CT (A) and MRI (B) of an expansile and lytic lesion of the in S1 and S2 with associated soft-tissue mass beyond the sacrum.

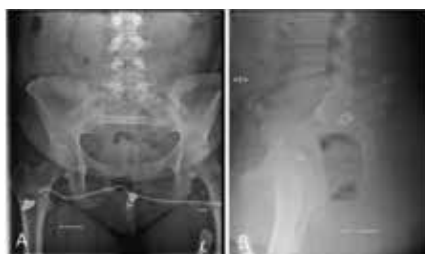

Figure 3. AP (A) and lateral (B) of carbon fiber reconstruction L3-iliac.

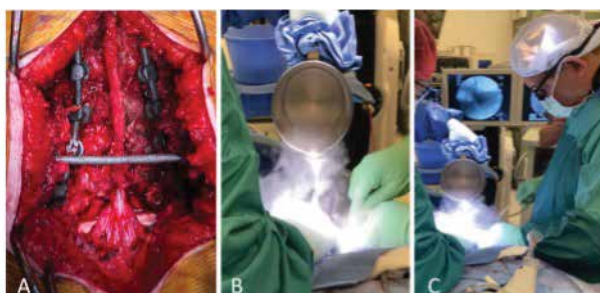


Figure 2. A: carbon fiber fixation L3-iliac with a crosslink. B and C: Adjuvant dry ice therapy.

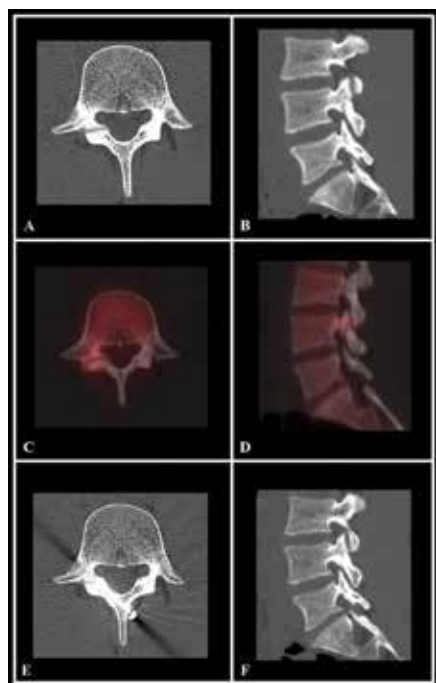


Figure 4. A: Axial CT scan image showing the pars defect. B: Sagittal CT scan image showing the pars defect with vertical orientation. C and D: Axial SPECT showing pars defect and bone regeneration activity. E and F: Three month post-operative CT scan showing fracture healing and well maintained position of the screw.

difficult to achieve the necessary trajectory while maintaining the appropriate angle to bridge the defect without violating the cortex of the bone due to the physical restraints of the spinous process.

A hybrid OR suite was chosen equipped with the Artis zeego (Siemens Healthcare) CT device for real-time guidance and confirmation of optimal hardware placement. A stab incision was made 5 cm lateral to the L4 spinous process on the contralateral side to the defect. A Jamshidi needle was advanced to the junction of the left lamina and spinous process approximating as close as possible the ideal pre-operative trajectory. Correct positioning was routinely evaluated and confirmed via the 3D imaging. A Kirschner wire was then advanced through the Jamshidi needle and across the pars defect terminating in lateral wall of the right pedicle. A 2.7 drill was then

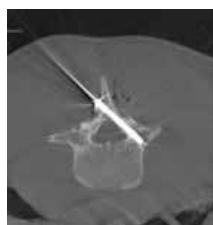

Figure 5. Intraoperative CT scan images showing the cannulated screw inserted over the K-wire.

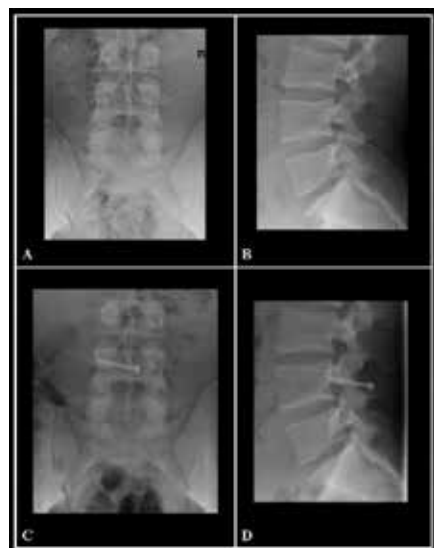

Figure 6. Preop AP (A) and lateral (B). Postop AP (C) and lateral (D) showing the screw fixation of the pars defect.

advanced over the guide wire and past the defect. A partially threaded 4.0 x 46 mm cannulated titanium screw with a washer was then advanced under real-time 3D guidance (Figure 5).

Final post-operative AP and lateral fluoroscopic imaging confirmed optimal hardware placement (Figure 6C and 6D). There was minimal blood loss and no complications were encountered throughout the procedure.

Approximately three months post-operatively a CT scan was completed which confirmed bony union, well-maintained position of the screw and no evidence of complications (Figure 4E and F). The patient had excellent range of motion with no pain, and was cleared to gradually return to full conditioning and football training.

SI joint fusion

Sacroiliac joint (SIJ) is known to be a major contributor to back pain and is reported as contributing to about 30% of back pain cases.¹ This pathology was neglected until not long ago and was noted to be one of the factors leading to chronic back pain and associated socioeconomic impact. SIJ fusion is one of the end-stage treatment options for this pathology after conservative treatment and therapeutic injections. Open SIJ fusion surgeries are rarely performed nowadays given their high complication rates and prolonged recovery. Minimally invasive SIJ fusion is now considered the current treatment of choice. It offers the advantages of significantly better pain improvement and faster healing.

Robotic assisted spine surgery technology is another new technology and helps with accurate instrumentation in complex anatomy regions. The robotic system helps to identify 3-dimensional spinal anatomy and helps with spinal instrumentation using a small incision with minimal tissue dissection and blood loss. Sacroiliac joint is one such highly complex anatomical structure and is difficult to visualize using traditional spinal imaging, and robotic assisted SIJ fusion surgery is now starting to help with instrumentation for this complex and poorly understood joint.

Surgical planning can be done on a spinal robotic system utilizing pre-operative imaging. The robotic system helps to identify the desired position and placement of SI joint fusion implants. Guidewires are placed using robotic guidance in the desired trajectory (Figure 7A). Appropriate position and depth of the guidewires (and subsequent implants) is critical to avoid potential neurovascular injuries. Verification of guidewire placement can be done using fluoroscopy imaging. The implants

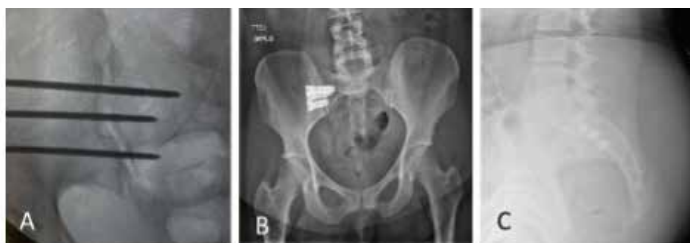

Figure 7. A: Guidewires are placed using robotic guidance. AP (B) and Lateral (C) of sacroiliac joint fusion.

are then inserted over a small incision (Figure 7B and C).

This approach helps with accurate SI joint instrumentation in a complex anatomy utilizing a small incision/ percutaneous approach. It also helps to minimize unnecessary radiation exposure to the patient and the surgical team. Smaller incision and minimal tissue dissection helps reduce postoperative and hospital stay. Most of these patients can be immediately discharged home and can resume their activities without any major recovery period.

Clinical Research

Evaluation of Gait and Functional Stability in Preoperative Cervical Spondylotic Myelopathy Patients

INTRODUCTION

Cervical myelopathy causes significant functional deficits, including gait disturbances. There have been multiple studies that have characterized these disturbances and how gait improves following decompressive surgery. However, in this population, gait and energy expenditure during normal walking is not well characterized and could influence future therapy and rehabilitation. Although gait parameters have been extensively studied, the lack of gait efficiency considerations in previous studies precludes more substantial improvements to rehabilitation protocols that could affect the speed at which patients regain gait function and the extent

to which full function is reacquired. As such the aim of this study was to 1) assess spatiotemporal gait parameters; 2) determine planar variance in postural stability; and 3) characterize the dynamic stability of Nurick grade 2 or 3 preoperative CSM patients, while comparing them to healthy control patients. We hypothesize that preoperative CSM patients will have significant alterations in spatiotemporal gait parameters and postural stability compared to controls.

METHODS

Following institutional review board (IRB) approval, CSM subjects that were considered appropriate surgical candidates were prospectively recruited from within our institution. 56 subjects: 32 preoperative Nurick grade 2 or 3 CSM patients and 24 controls were included. Standing balance trials were performed on a single force plate, while walking trials were conducted at self-selected pace over a 15 m runway and a series of five force plates (Figure 8). All trials were recorded with 3D motion analysis cameras and gait modeling software was utilized to calculate stability, spatiotemporal gait parameters, and joint kinematics.

RESULTS

Tilted ellipse area, a measure of center of pressure variance and postural stability, was significantly greater among CSM patients ($847.54 \pm 764.33 \text{ mm}^2$ vs. $258.18 \pm 103.35 \text{ mm}^2$, $p < 0.001$). These patients had

two times as much variance medial-lateral ($72.12 \pm 51.83 \text{ mm}$ vs. $29.15 \pm 14.95 \text{ mm}$, $p = 0.001$) and over three times as much anterior-posterior ($42.25 \pm 55.01 \text{ mm}$ vs. $9.17 \pm 4.83 \text{ mm}$, $p = 0.001$) compared to controls (Figure 9). Spatiotemporal parameters indicated that the CSM patients tending to have slower, shorter, and wider gait compared to controls, while spending greater amount of time in double support. Compensatory AM among CSM patients was significantly increased in all three anatomic planes, where whole body AM was approximately double that of controls (0.057 ± 0.034 vs. 0.023 ± 0.006 , $p < 0.001$).

CONCLUSION

Preoperative CSM patients showed significant alterations in spatiotemporal gait parameters and postural stability compared to controls, consistent with prior literature. Likewise, angular momentum analysis demonstrates that these patients have increased body excursion in all three anatomic planes to maintain dynamic balance. Specifically, a phase shift in increasing compensatory angular momentum in the sagittal and traverse planes correlated to delayed initiation into an unstable swing phase following a period of prolonged stable double support. Understanding these deficiencies is crucial in the development of targeted therapies and rehabilitation plans to prevent complications, like falls, and help restore functional capacity in this population.

Basic Science Research

Deciphering Macrophage Phenotype and Function in Disc Herniation and Associated Back/leg Pain

CLINICAL CHALLENGE

Incomplete understanding of the inflammatory cascade of disc herniation:




Figure 8. Subject with marker set highlighted in blue, green, and red overlay. Subject-specific model shown by frames aligned with limbs.




Figure 9. Measurement of gait and stability recorded by 12 Vicon Nexus system cameras and 5 floor-mounted Bertec force plates.

The normal intervertebral disc is an immune-privileged organ composed of the inner nucleus pulposus (NP) and the outer annulus fibrosus (AF). When discs wear out, the AF cracks and the NP herniates

out, which is recognized as a foreign body by our immune system. Immune cells infiltrate the disc hernia sites and evoke a cascade of events, such as cytokine production by both disc cells and immune cells, which exacerbate inflammation and pain.¹¹⁻¹⁴ Despite extensive studies, clinicians remain puzzled by patients' disproportional symptoms to herniation and response to treatments, e.g., epidural steroid injection. To solve this puzzle, it is critical to decode the inflammatory microenvironment of herniated discs.

Macrophages (MΦ) are the predominant infiltrated cells at disc hernia sites and may play distinct roles in various phases of disease progression: Emerging evidence and our preliminary data suggest that MΦ exhibit several subpopulations, often with competing biological functions at various stages of disc herniation.

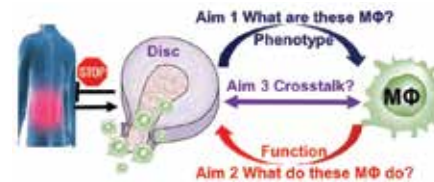
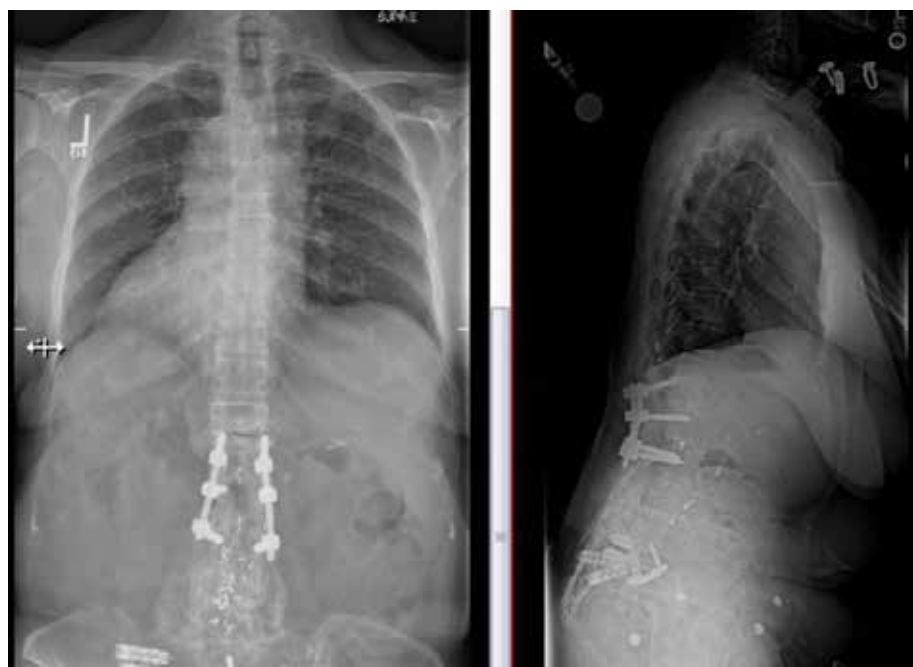

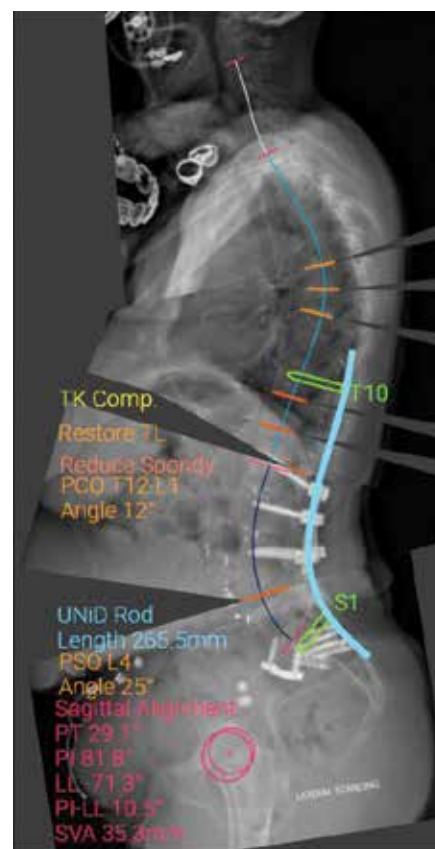Figure 10. Independent aims, contributing to decipher key roles of MΦ in disc herniation to tackle the disease in the long term.

We propose that the balance between MΦ subpopulations determines outcomes, such as back/leg pain. However, understanding in the field is rudimentary especially concerning: 1) Phenotypes—what MΦ subpopulations are and whether they correlate with disease progression; 2) Functions—how these MΦ alter inflammation and pain and the molecular regulators; and 3) Crosstalk—how the bidirectional disc-MΦ interactions contribute to the pathogenesis that will be studied on our innovative spatiotemporal controlled biochip. Our overarching hypothesis is that various subpopulations of MΦ contribute to the progression of disc herniation and pain in response to disease stage-specific environmental cues. We also hypothesize that modulation of MΦ will restore disc homeostasis and alleviate pain. Our objective for this project is to understand MΦ phenotypes/functions and disc-Mv interactions in disc herniation at a mechanistic level (Figure 10). Our long-term goal is to develop disease-modifying therapies to manage disc herniation and back/leg pain. ■

Sixth Time Is a Charm: A Case Study Highlighting a Complex Revision Spine Surgery



AP and lateral X-rays of 74-year-old female after five spine fusion surgeries and SI joint fusion. She has sagittal imbalance and flat lower back with fused spine from L1-S1.



Preoperative plan for rod and curve correction.

More than 1,500 spine procedures are performed each year at UVA Health by some of the leading spine specialists in the country. A significant number of these procedures are revision surgeries necessitated by a failed implant or hardware, the formation of scar tissue at the surgical site, surgical error or other complication. These revision surgeries require more complex decision making, surgical planning and skill to repair damage, restore mobility and reduce pain.

According to orthopaedic surgeon Xudong Joshua Li, MD, the more procedures a patient has had, the more challenging the repair. The patient featured in the case study below came to UVA for her

sixth spine surgery, making this surgery one of his most ambitious cases yet. Read more about the outcome below.

CASE STUDY: PROXIMAL JUNCTION FAILURE PATIENT: 74-YEAR-OLD FEMALE

Evaluated by: Orthopaedic surgeon

Xudong Joshua Li, MD

Diagnosis: Proximal junction failure and flat back without a natural lumbar curve

The patient arrived at UVA Health in 2019, two years after her fifth spine surgery, which was completed in Florida.

“Her initial surgeries were for back pain,” says surgeon Xudong Li, MD. “The surgeons started with a fusion of the lower spine and she developed junctional prob-

lems. She then had another surgery and another to relieve pain. It’s unusual for someone to have this many surgeries.”

“Her spine was fused almost straight from L1 to S1. She had no natural curvature in her spine, so she was walking leaning forward and she was in a lot of pain,” Li adds. “There was a screw cutting into the bone and a disc was breaking down.”

Treatment: L4 Pedicle Subtraction Osteotomy and Spinal Fusion from T10 to the Pelvis

“We made a detailed surgical plan, measuring the curve of her whole spine and spinopelvic angles and custom designed the curve of the rods. We had the advantage of using a robot to plan every screw placement prior to the surgery,” explains Li.

“Because her spine was fused straight, I had to first break down the fused spine or fracture it,” says Li.

Li then made a wedge-shaped cut, removed the L4 pedicle and then closed the gap to create a 25-degree curve in the patient’s spine. “The patient was on a bed that can flex and extend during the surgery, which helped us to close the gap and give her a more natural curve,” he says.



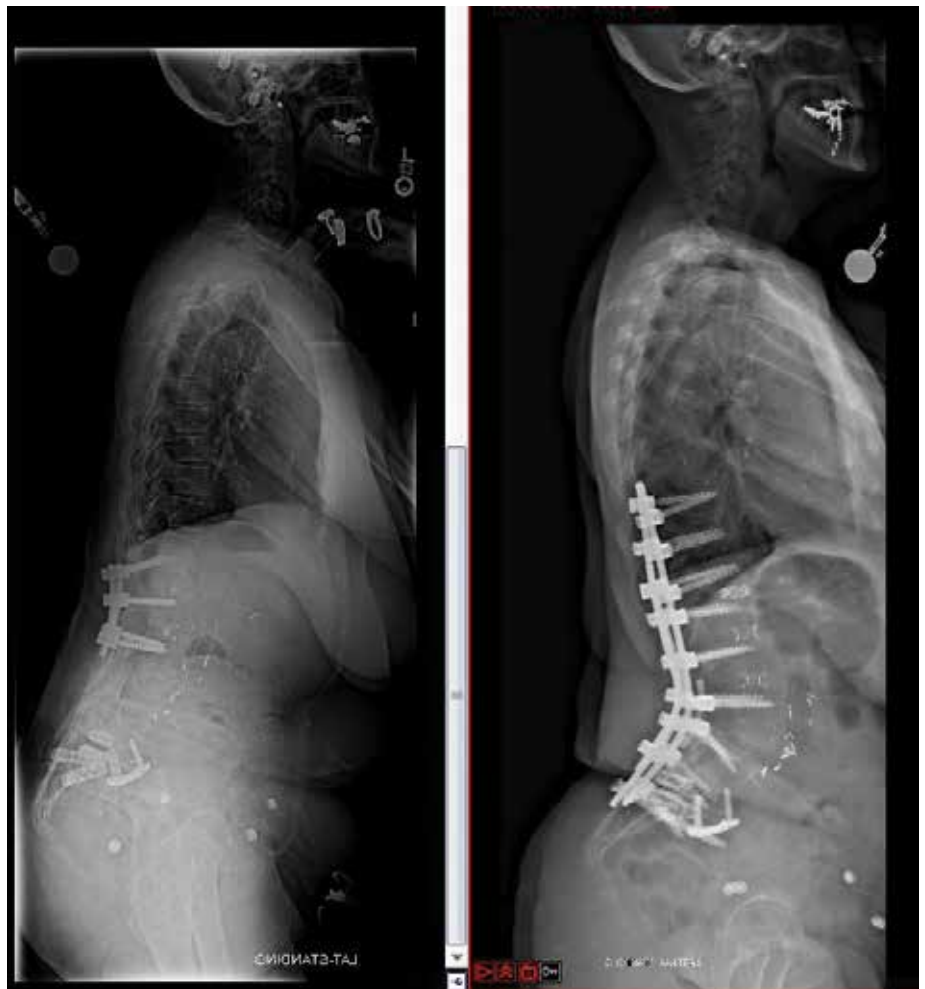Intraoperative images of L4 pedicle subtraction osteotomy with about 25 degrees of lordosis correction.

Outcome: Much Improved Spine Alignment and No Pain

After a period of rehabilitation and physical therapy to restore her mobility, the patient was able to walk upright and was completely pain-free in the back at a follow-up appointment six months after the surgery. It is first time in the last 15 years that she does not need pain medication.

“She is now back in Florida,” says Li. “I give my cellphone to all my patients who have surgery with me. She texted me last week that she was doing well.”

“The complexities of this surgery make it a standout case,” adds Li. “It’s another example of how the right technology and surgical expertise can result in good outcomes even for complex patients.”



X-rays showing spine alignment before and after surgery.



Stephen F. Brockmeier, MD

Professor

Dr. Brockmeier is a Professor of Orthopaedic Surgery in the Division of Sports Medicine at the University of Virginia. He is Director of the UVA Sports Medicine Fellowship and Team Physician for UVA Athletics, with primary coverage as the Head Team Physician for UVA Football, Men's Soccer, and Men's Lacrosse. A long-time Hoo, Dr. Brockmeier completed his undergraduate degree here at UVA in 1997 followed by medical school and Orthopaedic Surgery residency at Georgetown University. After residency, Dr. Brockmeier spent a year at the renowned Hospital for Special Surgery in New York where he completed a fellowship in Sports Medicine and Shoulder Reconstructive Surgery.

Prior to coming back to UVA as a faculty member in 2010, Dr. Brockmeier spent three years in practice in Charlotte, North Carolina, where he was the team physician for the NBA Charlotte Bobcats. His current practice at UVA focuses on sports medicine, knee and shoulder arthroscopy and reconstructive surgery, and the care of athletes and active individuals. He subspecializes in knee ligament, meniscus, and cartilage repair surgery, ACL reconstruction, and has become a regional expert in complex shoulder reconstruction, management of shoulder instability, rotator cuff surgery, as well as total shoulder arthroplasty and reverse shoulder arthroplasty.

Dr. Brockmeier's current research focuses on management of shoulder instability in the contact athlete, return to play strategies after ACL reconstruction, biologic options for rotator cuff repair, and cutting-edge and novel techniques in shoulder replacement surgery. He received the Deans' Award for Clinical Excellence at UVA, was selected for the prestigious AOSSM Traveling Fellowship to Europe in 2014, and is the current chair of the Education Committee for AOSSM. He was recently appointed as the Editor for the *Video Journal of Sports Medicine*, a new journal from the AOSSM Medical Publishing Board that launches in 2021.

Dr. Brockmeier is the immediate Past President of the ACCESS Society, was inducted into the Herodicus Society in 2019 and is an active member of ASES, AAOS, AOSSM, AANA, and MASES.



David R. Diduch, MD*

Allen F. Voshell Professor

Dr. David R. Diduch is the Allen F. Voshell Professor and Division Head of Sports Medicine at the University of Virginia. He is also the former Vice Chair of the department. Dr. Diduch is the Head Orthopaedic Team Physician for UVA athletics and has primary coverage for men's basketball, football, and women's soccer teams.

Dr. Diduch's training started with college at UNC followed by medical school at Harvard and Orthopaedic residency at UVA. After his sports fellowship in New York at the Insall-Scott-Kelly Institute, he joined the faculty in 1995. His practice is split between knee and shoulder surgery and care of injured athletes.

A major area of clinical and research focus for him involves taking care of patients with patella instability. He has extensive experience with treating complex patella instability problems with cutting-edge techniques, including tibial tubercle osteotomy, MPFL reconstruction, and limb realignment. He is one of very few surgeons in the U.S. performing deepening trochleoplasty procedures for trochlear dysplasia and patella instability. His other research interests include post-ACL surgery return to play decision-making, articular cartilage and meniscal repair, and novel knee unloading devices for early arthritis.

Dr. Diduch has received the UVA School of Medicine Master Clinician Award, served as chair of numerous committees for AOSSM as well as the Council of Delegates, served as President of the Virginia Orthopaedic Society, and has been inducted into the Herodicus Society. He is very active in research and academic pursuits with over 160 publications, 50 book chapters, and 30 research grants. He has been married to Lynn for over 30 years and has 3 grown boys, all of whom graduated from UVA.



F. Winston Gwathmey, MD

Associate Professor, Vice Chair for Education & Residency Program Director

Dr. F. Winston Gwathmey is the son of an orthopaedic hand surgeon, Dr. Gwathmey grew up in Norfolk, Virginia, and received his undergraduate degree from the University of Virginia. He received his medical degree from Eastern Virginia Medical School and returned to UVA for residency. He then completed a Sports Medicine and Shoulder Fellowship in Boston at Massachusetts General Hospital and pursued additional hip arthroscopy training with Dr. Thomas Byrd in Nashville, Tennessee.

Dr. Gwathmey returned to UVA as a faculty member in 2013 and currently is an Associate Professor in the Division of Sports Medicine with a special interest in arthroscopic techniques around the hip. He established the Hip Arthroscopy Program at UVA and currently performs upwards of 200 hip arthroscopic surgeries per year. He is the Orthopaedic Residency Program Director and active in the medical student curriculum as well. He has won multiple teaching awards including the Mulholland Teaching Award, the Charles W. Miller Resident Teaching Award, and the Dean's Award for Excellence in Medical Student Teaching.

Dr. Gwathmey is the Medical Director of the Sports Medicine Clinic. He is also one of the team physicians for both UVA and JMU Athletics. He is active in the American Orthopaedic Society for Sports Medicine and the Arthroscopy Association of North America, serving as faculty at annual meetings and in surgical skills courses throughout the year.

Outside of work, Dr. Gwathmey enjoys time with his wife, Kelly (a neurologist at VCU), and two kids, Cate and Robert. He enjoys cheering on the UVA and JMU athletic programs.



Mark D. Miller, MD

S. Ward Casscells Professor

Dr. Mark D. Miller is the S. Ward Casscells Professor of Orthopaedic Surgery and former Division Head of Sports Medicine at the University of Virginia. He is a retired Colonel in the US Air Force. He is a Distinguished Graduate (top 3%) of the US Air Force Academy and the Uniformed Services University of the Health Sciences (USUHS). He served in the Air Force as a Civil Engineer and earned his Professional Engineering (PE) certificate prior to attending medical school. After medical school, Dr. Miller completed his residency in Orthopaedic Surgery at Wilford Hall USAF Medical Center in San Antonio, Texas, and a fellowship in Sports Medicine and Shoulder Surgery at the prestigious University of Pittsburgh. He served as a surgeon and team physician at the Air Force Academy and as Chief of Sports Medicine and Deputy Chairman at Wilford Hall prior to coming to the University of Virginia. He served as Head Team Physician for James Madison University for 15 years.

Dr. Miller has authored over 200 articles and has authored and/or edited 40 textbooks. He has served in numerous leadership positions for the American Orthopaedic Society for Sports Medicine (AOSSM) and currently serves as President-Elect on the Board of Directors. Dr. Miller will be the AOSSM President in 2022-2023. He was awarded the AOSSM George Rovere Award for Education, the USUHS Distinguished Service Award, and the Virginia Orthopaedic Society Lifetime Achievement Award.

Mark Miller is a highly sought after speaker and has organized numerous Instructional Course Lectures (ICL), served as a Visiting Professor at multiple prestigious programs, and founded and directed the most successful review course in Orthopaedics, the Miller Review Course, established over 25 years ago. Dr. Miller's research interests include complex knee to include multiple ligament injuries, revision ACL, articular cartilage injuries and meniscal repair and transplantation.



Brian C. Werner, MD

Associate Professor

Brian Werner, MD, is an Associate Professor in the Department of Orthopaedic Surgery. He completed a fellowship in Sports Medicine and Shoulder Surgery at the Hospital for Special Surgery, where he was a team physician for the New York Giants and the New York Red Bulls. Dr. Werner currently serves as the Head Orthopaedic Team Physician for James Madison University athletics, where he provides primary coverage for all sports, including the 2016 FCS national championship football team, men's and women's basketball, men's and women's soccer and the 2018 national champion women's lacrosse team among others. Board-certified in Orthopaedic Surgery with subspecialty certification in Sports Medicine, he specializes in Sports Medicine and Shoulder Surgery. This includes both arthroscopic and open reconstructive surgery of the shoulder and knee. He focuses on all sports and athletic injuries, and has a particular clinical interest in shoulder replacement and ligament reconstruction of the knee.

Dr. Werner has a significant interest in both clinical and basic science research, has published over 250 peer-reviewed papers on a wide variety of orthopaedic topics and has presented his research both regionally and nationally over 400 times. He has won numerous national awards for his research. His current research interests include clinical outcomes after knee and shoulder surgery, biomechanical studies in the knee and shoulder, shoulder arthroplasty and cartilage injury and repair.

Dr. Werner has numerous national leadership roles, and serves on the research committee for the American Orthopaedic Society for Sports Medicine, education committee for the American Academy of Orthopaedic Surgeons, and the abstract review and research committees for the American Shoulder and Elbow Surgeons society.

The “N + 10 Rule” to avoid graft tunnel mismatch in bone-patellar tendon-bone anterior cruciate ligament reconstruction using independent femoral tunnel drilling

Ryan M. Graf, MD; Scott E. Dart, MD; Ian S. MacLean, MD; Laurel Barras, MD; Thomas Moran, MD; Brian C. Werner, MD; F. Winston Gwathmey, MD; David R. Diduch, MD; Mark D. Miller, MD

University of Virginia Health System, Charlottesville, VA, USA

BACKGROUND

Graft tunnel mismatch is a common problem in anterior cruciate ligament (ACL) reconstruction using bone-patellar tendon-bone (BTB) grafts. Direct measurement strategies for creating ideal tibial tunnel length are accurate, but can be cumbersome and technically difficult intraoperatively. Indirect strategies, like the “N + 7” degree rule, have also shown reproducible tibial tunnel lengths without the need for intraoperative measurement for transtibial femoral tunnel drilling. Our observation has been that this formula underestimates the ideal length of the tibial tunnel for independent femoral tunnel drilling, so we sought to assess the applicability of the novel “N + 10” rule for independent femoral tunnel drilling in this cadaveric study.

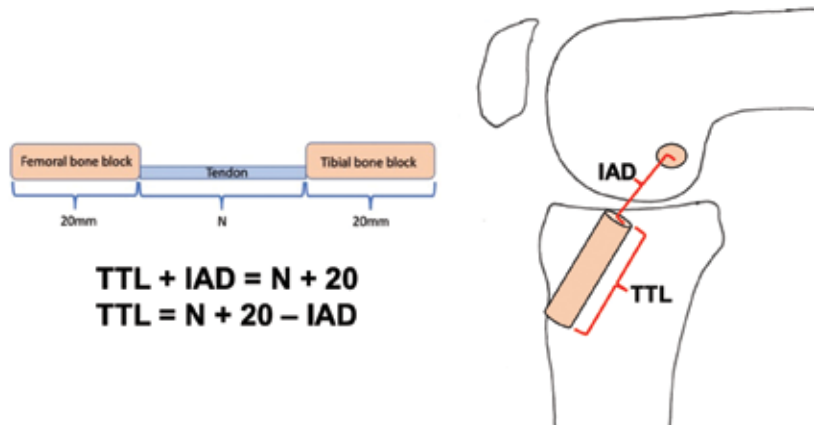


Figure 1. Derived formula for calculating ideal tibial tunnel length (TTL) using intraarticular distance (IAD), and the known values of the intertendinous distance (N) and lengths of the bone blocks (20 mm).

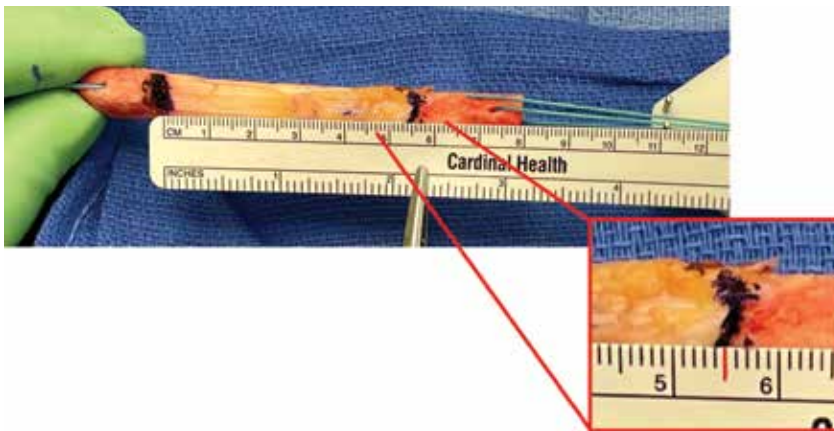


Figure 2. Intraoperative photo of BTB ACL graft measuring intertendinous distance between the bone plugs (N = 55mm). Following the “N + 10” rule.

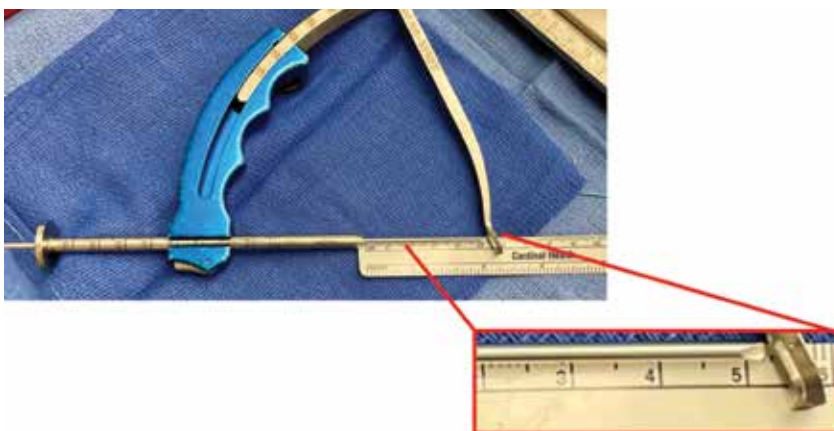


Figure 3. Intraoperative photo of tibial ACL guide measurement of tibial tunnel length at 50 mm with guide set to 65 degrees.

OBJECTIVES

1. To determine the amount of tibial graft tunnel mismatch during application of

the “N + 10” rule in arthroscopic assisted anterior cruciate ligament (ACL) reconstruction with bone-patellar ten-

don-bone (BTB) graft using independent femoral tunnel drilling.

2. To compare actual (measured) tibial tunnel length and desired (calculated) tibial tunnel length when using the “N + 10” rule for independent femoral tunnel drilling.

STUDY DESIGN

Controlled laboratory study

METHODS

Twenty paired knees from 10 fresh frozen cadaveric specimens (5 female and 5 male specimens) underwent arthroscopic assisted bone-patellar tendon-bone ACL reconstruction using independent femoral tunnel drilling with either a hyperflexion accessory anteromedial portal (n = 10) or flexible reamer technique (n = 10). The prepared patellar tendon graft bone blocks were trimmed to 10 x 20 mm for all specimens and the intertendinous distance (N) between the bone blocks was measured. The “N + 10 Rule” was used to set the angle of the ACL tibial tunnel guide to the appropriate degree setting for drilling. The amount of excursion or recession of the tibial bone plug in relation to the anterior tibial cortical aperture was measured in both flexion and extension. A +/- 6 mm threshold was used to assess this strategy based on prior biomechanical aperture fixation studies. As a secondary outcome, the intraarticular distance (IAD) and the actual tibial tunnel length (TTL) were measured and compared to the planned TTL based on the equation: $IAD + TTL = N + 20$ (size of bone plug in millimeters).

RESULTS

The average BTB ACL intertendinous distance (N) was 47.5 mm (SD = 5.5 mm). The average measured IAD was 27.2 mm (SD = 3.0 mm). Using the “N + 10 Rule”, the average mismatch of the tibial tunnel was 4.9 mm (SD = 3.6 mm) and 3.8 mm

(SD = 3.5 mm) in flexion and extension, respectively. Both values fall within the ± 6 mm threshold. When comparing the actual measured tibial tunnel length (TTL) to the desired TTL, there was an average difference of 5.4 mm (SD = 3.9 mm).

CONCLUSIONS

The “N + 10” rule resulted in an acceptable average mismatch in both flexion and extension using the threshold of ± 6 mm for 20 cadaveric knees. Measured actual TTL compared to the desired calculated

TTL were acceptable 61% of the time using the same threshold. The “N + 10” is a simple and effective intraoperative strategy for achieving desired tibial tunnel length to avoid excessive graft tunnel mismatch. ■

Lateral Extra-Articular Tenodesis Staple Risks Penetration of ACL Reconstruction Tunnel

Ian S. MacLean, MD; Gregory Anderson, MD; Laurel A. Barras, MD; Ryan M. Graf, MD; Thomas E. Moran, MD; F. Winston Gwathmey, MD; David R. Diduch, MD; Mark D. Miller, MD

University of Virginia Health System, Charlottesville, VA, USA

OBJECTIVES

The purpose of this study was to identify the risk of ACL femoral tunnel penetration by a small Richards staple used for lateral extra-articular tenodesis (LET) fixation and to determine whether or not the risk varies between two techniques for ACL femoral tunnel creation.

METHODS

20 paired fresh frozen cadaver knees underwent ACL reconstruction with an LET using the modified Lemaire technique (Getgood et al. *AJSM*, Jan 2020). Left and right knees were randomized to ACL reconstruction with femoral tunnel creation by either the accessory anteromedial portal (AMP) technique or the flexible guide pin and reamer method. The femoral tunnels in the accessory AMP technique arm were created using a 7 mm offset guide. Both arms used a 10 mm reamer and were reamed to a depth of 25 mm. After tunnel creation and prior

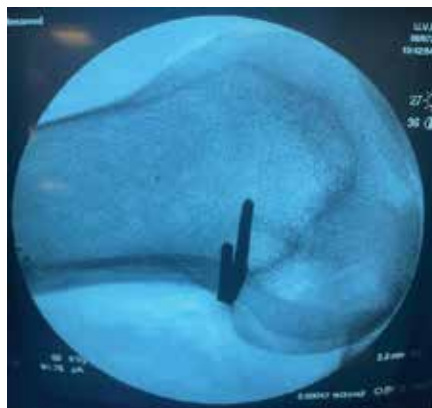

Figure 1. A lateral fluoroscopic view of the knee demonstrating the Richards staple fixation of the LET graft. It is positioned on the lateral metaphyseal flare proximal and posterior to the LCL insertion and is angled distally and anteriorly.

to passing the ACL graft, the LET was performed. This was completed by harvesting an 8 cm long and 10 mm wide central portion of the IT band which was left attached to its distal insertion on Gerdy’s tubercle. This was routed underneath the LCL and fixed with a small Richards staple on the lateral metaphyseal flare proximal and posterior to the LCL insertion. The staple was angled anteriorly and distally. Fluoroscopy was used to obtain a lateral view of the staple (Figure 1). Finally, tunneloscopy was performed from the anteromedial portal to investigate penetration of the staple into the

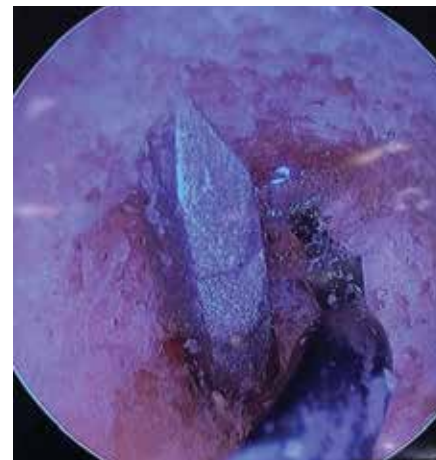

Figure 2. Arthroscopic view of the reamed ACL femoral tunnel showing penetration by the Richards staple.

femoral tunnel (Figure 2). A Fisher’s exact test was conducted to determine if there was any difference in tunnel penetration between tunnel creation techniques.

RESULTS

The staple was noted to penetrate the ACL femoral tunnel in 8/20 (40%) extremities. When stratified by tunnel creation technique, the Richards staple violated 5/10 (50%) of the tunnels made via the accessory AMP technique compared to 3/10 (30%) of those created with a flexible guide pin and reamer ($p = 0.65$).

CONCLUSIONS

Staple fixation of an LET carries significant risk of penetrating the ACL tunnel that does not vary by the technique of femoral tunnel creation. This raises concerns over the potential effect of the staple on ACL graft fixation and the ACL graft itself. ■



Michael M. Hadeed, MD

Assistant Professor

Dr. Michael Hadeed was born and raised in Northern Virginia. He completed medical school and residency at the University of Virginia, and his trauma fellowship at Denver Health. His focus is on optimizing early post-operative and non-operative recovery and improving access to trauma care. Outside of work, he enjoys family time, grilling and biking.



David B. Weiss, MD*

Associate Professor

Dr. David B. Weiss attended Johns Hopkins University in Baltimore, Maryland, for his undergraduate studies, majoring in Biomedical Engineering to facilitate his future career as an orthopaedic trauma surgeon involved with re-engineering humans instead of bridges and machines. Dr. Weiss attended Georgetown University for medical school and then completed a surgical internship at the University of Michigan. He then spent three years as an active duty Air Force flight surgeon stationed at McConnell AFB in Wichita, Kansas.

After serving in the Air Force, Dr. Weiss returned to the University of Michigan to finish an Orthopaedic Surgery Residency and then completed a one-year Fellowship in Orthopaedic Trauma at Harborview Hospital in Seattle, Washington. He spent the next five years as the Director of Orthopaedic Trauma at St Joseph Mercy Hospital in Ann Arbor, Michigan, and joined the University of Virginia in 2010 as the Division Head of Orthopaedic Trauma. His areas of clinical focus include complex fractures of the proximal and distal tibia and malformed or unhealed fractures of the hips, legs, and feet.

Dr. Weiss is heavily involved with the education of medical students and orthopaedic residents at the local and national level with our specialty organization, the Orthopaedic Trauma Association, the Academy of Orthopaedic Surgeons, and the AOTrauma foundation. He serves on education and patient safety committees for these organizations and has been honored with several education and teaching awards in addition to being selected as a Best Doctor for the last seven years and selected as one of the top 19 Traumatologists in North America in 2015.

Dr. Weiss enjoys trail running, biking, flying (general aviation), and military history. He is married with three boys. Keeping up with their activities is a second full-time job.



Seth R. Yarboro, MD

Associate Professor

Seth Yarboro is a North Carolina native who has been an orthopaedic surgeon at UVA since 2012. He specializes in fracture care of both acute and chronic injuries, as well as pathology involving soft tissue and infection. His approach to surgery utilizes both traditional as well as minimally invasive and computer-assisted surgical techniques.

Dr. Yarboro attended medical school at University of North Carolina at Chapel Hill, where he also completed his orthopaedic residency training. Dr. Yarboro then went on to complete orthopaedic trauma fellowships at UNC Hospital, an AOTrauma Fellowship in Hannover, Germany, and a fellowship in orthopaedic trauma and computer-assisted surgery in Ulm, Germany.

At UVA, Yarboro is an active researcher with a variety of interests, including infection treatment and prevention, ankle syndesmosis injuries, intraoperative advanced imaging, and quality outcomes after surgery. He has contributed to multiple publications and book chapters. He is also involved with the AO Technical Congress (AOTK) in their Computer-assisted and Image-guided Expert Group (CIEG), where technology is used to advance the field of surgery.

Dr. Yarboro currently serves as the patient safety and quality officer for the Department of Orthopaedics. This work involves organizing regular conferences within the department for case review and education, optimizing quality measures and reporting, and representing the department within the institution regarding quality-related policy.

He has specific interest in orthopaedic education, working routinely with residents in conferences and surgical training. He also works regularly with the Orthopaedic Trauma Association (OTA), participating in their resident fracture course. Additionally, he has served as program chair for educational meetings ranging from the local to national level.

“As an orthopaedic trauma surgeon, I try to understand the patient’s situation and provide helpful treatment options. Not every patient needs surgery, and we only consider surgery if it will reliably improve the long-term outcome. Whatever treatment path is chosen, we will work together to provide the best possible functional outcome.”

New Options for Post Traumatic Deformity: Case Example of Magnetic Lengthening Nail Used to Correct Chronic Post Traumatic Tibial Deformity

David Weiss, MD

University of Virginia,
Department of Orthopaedic Surgery
Charlottesville, VA

A 64 yo M had open tibia fracture 10 yrs prior and was treated with staged I and d and IMN as well as free flap for soft tissue defect. He states he had initially done well and was not treated long-term for an infection but had noticed a progressive increase in knee pain as well as valgus. He was able to fully weight bear without a brace but did use a cane for assistance. Had recently returned from trip to Europe and did more walking than usual which prompted him to seek evaluation for options.

POST TRAUMATIC DEFORMITY

The initial concern in a case like this is a chronic infection which is slowly progressing and at this point would be challeng-

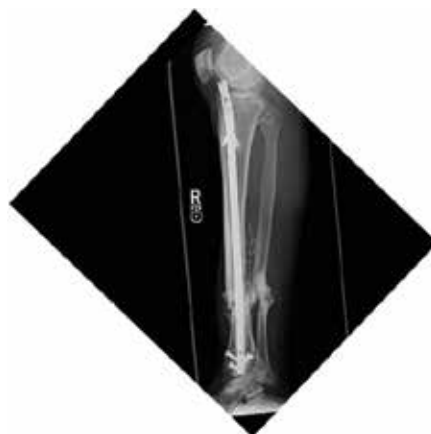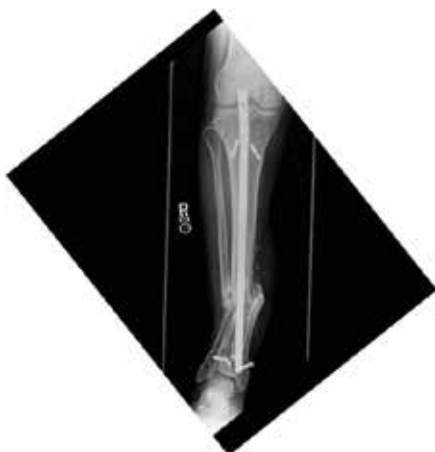ing to eradicate. Further workup including labs for infection and metabolic disorder as well as CT scan did not show any evidence of chronic infection and we discussed revision surgery to correct his deformity as well as option of below knee amputation. He had remained fairly active and wanted to pursue reconstruction. His deformity evaluation showed him to be in 20 degrees of valgus (nml 0-5) short ~4 cm and with prominent hardware in his knee joint. He was well aligned in the sagittal plane and with rotation compared to contralateral.

Previously this reconstruction would only have been possible with a hexapod frame. The bone at the original fracture site is sclerotic and likely dead. This will have to be excised and then a large defect will have to be grafted. While this could be accomplished through a few techniques, the shortening of the leg will require distraction osteogenesis and the multiplane external ring fixator would allow you to accomplish both the deformity correction

Magnetic lengthening nails allow distraction (or compression if desired for recalcitrant nonunions) by using an external controller to spin a powerful rare earth magnet inside the body of the nail which provides a precise movement of the nail and can allow for a steady and well controlled distraction rate. This can allow for lengthening with an all inside device which is much better tolerated.

and the lengthening. However, these devices are cumbersome and prone to pin site infection and have to remain in place for many months which can be a huge inconvenience for patients and their families.

Lengthening IM nails have been around for about 2 decades, but the original design used the patient's kinetic energy of walking and striking the ground to provide the stimulus for the nail to lengthen. These were somewhat inconsistent in how fast they lengthened with multiple case reports of "frozen" nails as well as "runaway" nails. Magnetic lengthening nails allow distraction (or compression if desired for recalcitrant nonunions) by using an external controller to spin a powerful rare earth magnet inside the body of the nail which provides a precise movement of the nail and can allow for a steady and well controlled distraction rate. This can allow for lengthening with an all inside device which is much better tolerated. Depending on the length and diameter of the nail there are different max-



RK

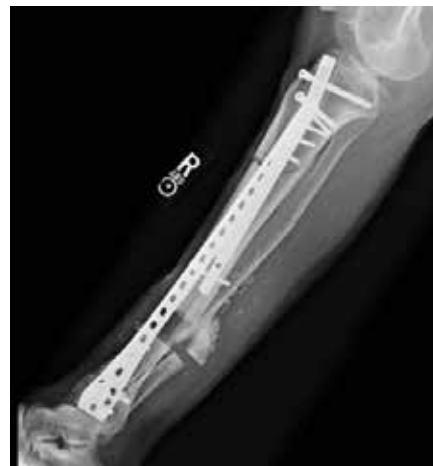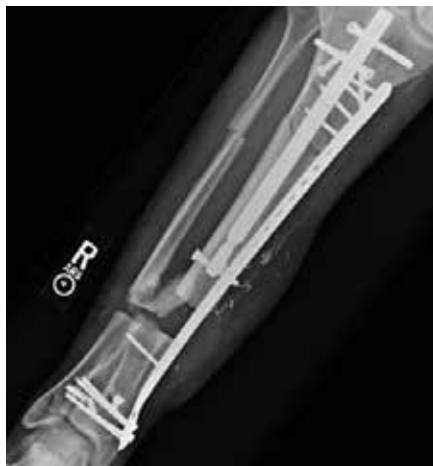imum stroke lengths available but the nail can also be rewound in a simple operation using a standard OR drill to spin an external magnet and rewind the nail in about 5-10 minutes. Meticulous pre op planning is critical to ensure accurate placement of the nail and the interlocking screws as well as the location of the osteotomy to allow the lengthening to occur safely.

1ST SURGERY

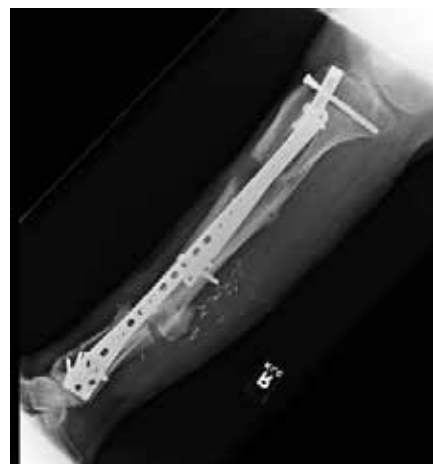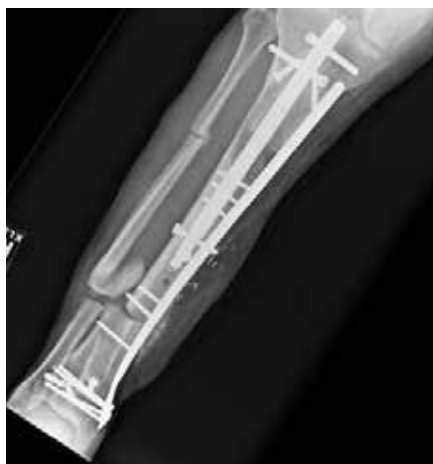The initial surgery focused on removing his nail and any broken interlock which would block additional steps. The dead bone around the fracture was resected leaving a 2.2 cm gap. Cultures were taken (which all remained negative) and a proximal osteotomy was made to begin pushing the proximal tibia down to close the gap created by the resection of the dead bone. A plate is applied to the medial tibia to serve a guide and a stabilizer to prevent coronal plane deformity during the

At 1 year post op his proximal regenerate is solid and his docking site has healed. He denies any issues with hardware prominence and is full weight bearing without assistive device except a small shoe lift.

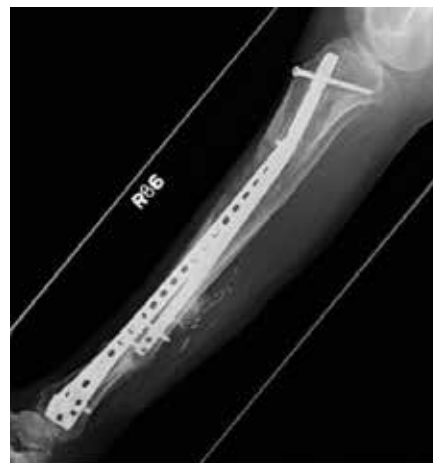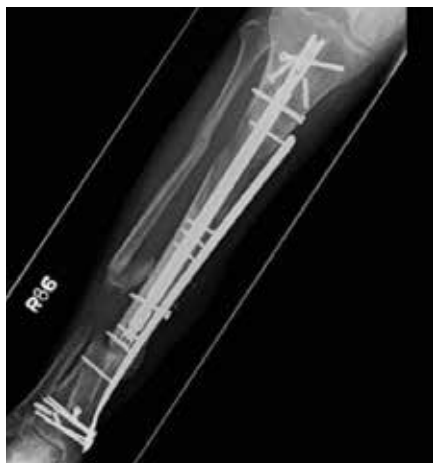lengthening. The newest generation of the nails (Bone Transport Nail) has an internal sliding component which allows distal locking beyond the gap and obviates the need for this plate, but was not yet available at the time of this surgery. The plate is secured with screws in the short residual distal segment and in the stable proximal segment and the intercalary segment is pushed down to close the defect at a rate of 0.75 mm/day.



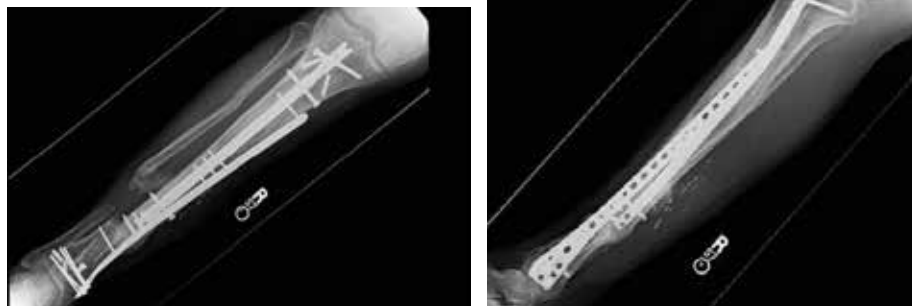
This shows the proximal osteotomy and the lengthening nail placed after the coronal deformity was acutely corrected and plate applied medially.



In these images you can see the regenerate bone proximally and the defect closed down. A small extension deformity developed during the lengthening which was within acceptable limits. Here the tip of the nail was also rewound to allow for additional stroke as the size of the nail limits the amount of stroke—in this case to 5 cm.



The docking site continues to consolidate and the proximal regenerate continues to calcify.



At 1 year post op his proximal regenerate is solid and his docking site has healed. He denies any issues with hardware prominence and is full weight bearing without assistive device except a small shoe lift. His leg lengths are 1 cm different and his alignment in the saggital and coronal planes is 5 degrees valgus and 10 degrees of extension when compared to his contralateral leg.

Once the defect had been closed down at 45 days post op, the docking site was bone grafted and the screws in the plate were removed from the proximal segment and placed into the intercalary segment so that the whole tibia could be lengthened to make up for the 4 cm defect in overall length.

Once the additional length needed was obtained at 100 days post op we allowed some consolidation of the regenerate to occur by stopping the lengthening and then we exchanged the lengthening nail for a standard trauma nail and allow progressive weight bearing. One downside of length-

ening internally is the components are not robust enough to tolerate significant weight bearing and the nails themselves must be removed by one year to prevent potential future issues with the magnets and the delicate mechanisms inside.

SUMMARY

Magnetic lengthening nails are a powerful tool to correct both deformity and limb length inequality as well as address issue of chronic aseptic bone necrosis which requires large sections of debridement and provides reliable growth of regenerate bone with far fewer inconveniences of wearing an external frame for many months and reduced risk of infection and skin breakdown from pin tracts. Similar to circular frames however, patient selection and ability to comply with weight bearing restrictions and apply the lengthening controller correctly is critical. ■

Development of a Finite Element Model for Evaluating Locked Plating Constructs for Distal Femur Fracture Fixation in Axial Loading

Seth Yarboro, MD, David Weiss, MD;
Ben Koerber, Sang-Hyun Lee PhD, Jee Soo Shin, Mark Lantieri, and Jason R. Kerrigan PhD

University of Virginia,
Department of Orthopaedic Surgery
Charlottesville, VA

INTRODUCTION

Locked plates in a bridging mode of application have become a standard method to treat comminuted femur fractures (1-3). This flexible fixation provides relative stability at the fracture site and stimulates callus formation through secondary fracture healing. In the mechanics of locked plate fixation, bridging constructs require some degree of interfrag-

mentary motion (IFM) at the fracture site. While IFM is considered the key element of fracture healing mechanism, its quantitative analysis remains challenging due to complex fracture patterns and geometries of the distal femur. Spatial distribution of IFM can be calculated using axial and shear components of interfragmentary strain (IFS) (1, 4), and finite element (FE) models are an effective tool to compute strains and stresses for such problems.

We undertook this study as a first step toward identifying mechanical factors in distal femur fracture healing. To determine deformation characteristics of locked plating constructs, synthetic femurs were tested

with different fixation and fracture gap conditions in axial loading. Then, IFS patterns at the fracture site were analyzed using FE models which were validated by construct stiffness, plate bending deflection, and principal strains from the axial loading tests.

MATERIALS AND METHODS

Test Specimens and Construct Configuration

Flexible fixation constructs were evaluated using synthetic femurs made of fiber-reinforced epoxy composite (Sawbones #3406; Pacific Research Laboratories Inc., Vashon Island, WA, USA) for minimal interspecimen variability. Two construct

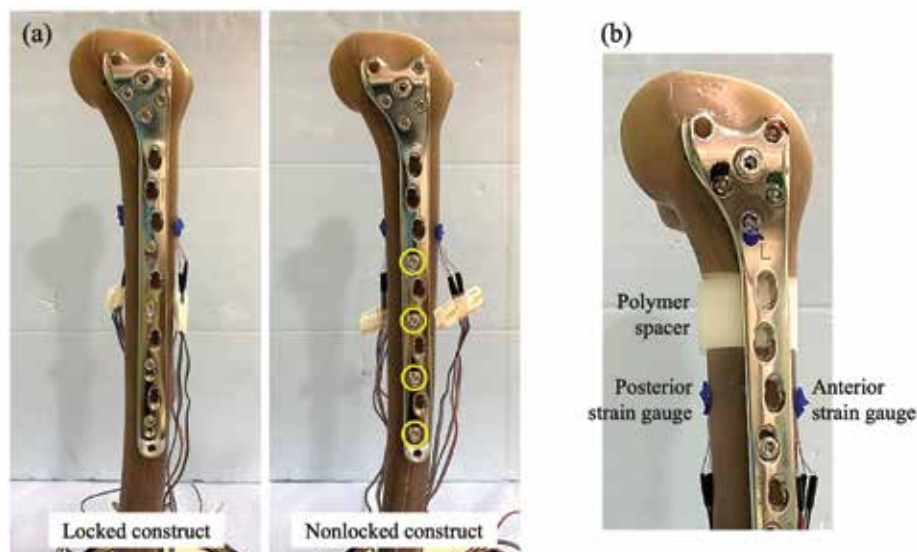


Figure 1. (a) Synthetic femur specimens with Locked and Nonlocked plating constructs (conventional screws are circled in the diaphysis), (b) Week 16 specimen with a polymer spacer and two strain gauges at anterior and posterior femur surfaces.




Figure 2. Axial loading test setup with three postoperative stages: (a) Week 48, (b) Week 16, and (c) Week 1 conditions.

configurations were created using 230 mm long distal femur plates (4.5 mm VA-LCP; Depuy Synthes, West Chester, PA, USA) with all locking screws for the “Locked” group and a combination of locking and conventional screws for the “Nonlocked” group (Figure 1a).

The plate type and size, screw type, and number of screws were based on a

common clinical configuration. Three different postoperative stages were applied to the synthetic femurs in each group (Figure 2).

Intact femurs of the Locked and Nonlocked constructs were tested as control cases (Week 48). As shown in Figures 1b and 2, a 25.4 mm gap osteotomy was applied to the tested femurs to simulate an

unstable multifragmentary fracture (AO/Orthopaedic Trauma Association 33A3) located 66 mm proximal to the lateral condyle (Week 1). Finally, a cylindrical polymer spacer of 38.1 mm diameter (Delrin 100AF; Mitsubishi Chemical America, Inc., USA) was placed in the fracture gap to represent stabilized callus formation at 16 weeks after surgery (Week 16) (5).

Finite Element Analysis

The femur FE model was developed using synthetic femur geometry and initial material properties available in the literature (6). The femur geometry was discretized by hexahedral elements and the cortical and trabecular bones were modeled as an isotropic bilinear elastoplastic material (LS-DYNA, Livermore Software Technology, CA, USA) (Figure 3). The initial material properties of the femur model were modified to match mechanical responses in axial loading and four-point bending experiments (7, 8). Multi-level model validation was conducted using construct stiffness, plate bending deflection, and principal strains from the axial loading tests.

RESULTS

Deformation Characteristics Under Axial Loading

The Locked plating group showed less reduction in construct stiffness from the Week 48 control to Week 16 and to Week 1 conditions than the Nonlocked plating group. The difference was noticeable in specimens with the Week 16 condition, and the Locked construct showed 42.5% higher normalized stiffness than the Nonlocked plate (Table 1). A smaller bending deflection of the femur at the fracture region was measured from the Locked-Week 16 construct (1.583 mm) compared to the Nonlocked-Week 16 construct (2.022 mm). There was no significant difference in plate bending deflection be-

Table 1. Construct stiffness, femur bending deflection, and plate bending deflection in axial loading tests.

Test condition		Construct stiffness (kN/mm)	Normalized construct stiffness	Femur bending deflection (mm)	Normalized femur bending deflection	Plate bending deflection (mm)	Normalized plate bending deflection
Locked	Week 48	1.925	1.000	0.977	1.000	0.155	1.000
	Week 16	1.808	0.939	1.583	1.620	0.235	1.516
	Week 1	1.075	0.558	-	-	1.030	6.645
Nonlocked	Week 48	2.067	1.000	0.985	1.000	0.217	1.000
	Week 16	1.063	0.514	2.022	2.053	0.236	1.088
	Week 1	0.864	0.418	-	-	1.033	4.760

tween the two groups. FE simulations of the six test conditions showed a good correlation with the test results of construct stiffness, plate bending deflection, and principal strains.

Clinical Impact and Future Work

Currently, the specific details of the techniques surgeons use when performing minimally invasive plate osteosynthesis (MIPO) surgeries are governed by surgeon experience, and rely on relatively subjective evaluations of fracture construct stability. Further clinical and biomechanical studies will be needed before any definitive clinical recommendations can be made, however this study begins work toward using the FE model to investigate real world cases of failed and successful fracture repair surgeries. Future work will need to be focused toward morphing the developed FE model to subject-specific geometries with the goal of simulating subject specific cases of fixation and quantifying amounts of IFM in a specific case. Then, IFM can be correlated with case outcomes. Using this framework, we hope to be able to provide surgeons with more concrete information about what type of fracture fixations to apply to specific fracture types. ■

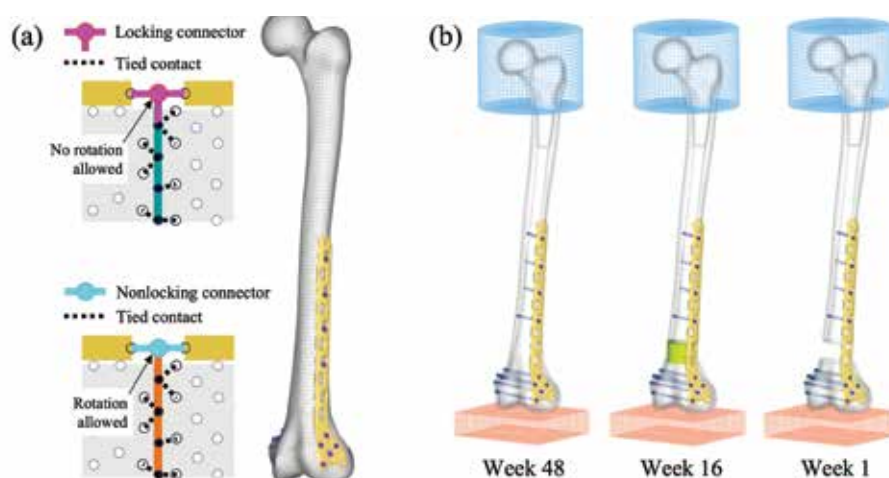



Figure 3. (a) Schematic of locking and nonlocking connectors in femur-plate-screw FE model. (b) Week 48, Week 16, and Week 1 FE models with axial loading boundary conditions (transparency applied for screw visualization).

REFERENCES

- Henschel J, Tsai S, Fitzpatrick DC, Marsh JL, Madey SM, Bottlang M. Comparison of 4 methods for dynamization of locking plates: Differences in the amount and type of fracture motion. *Journal of Orthopaedic Trauma*. 2017; 31(10):531.
- Ricci WM, Streubel PN, Morshed S, Collinge CA, Nork SE, Gardner MJ. Risk factors for failure of locked plate fixation of distal femur fractures: An analysis of 335 cases. *Journal of Orthopaedic Trauma*. 2014; 28(2):83-89.
- Rodriguez EK, Boulton C, Weaver MJ, Herder LM, Morgan JH, Chacko AT, Appleton PT, Zurakowski D, Vrahas MS. Predictive factors of distal femoral fracture nonunion after lateral locked plating: A retrospective multicenter case-control study of 283 fractures. *Injury*. 2014; 45(3):554-559.
- Claes L. Biomechanical principles and mechanobiologic aspects of flexible and locked plating. *Journal of Orthopaedic Trauma*. 2011; 25:S4-S7.
- Gardner TN, Stoll T, Marks L, Mishra S, Tate MK. The influence of mechanical stimulus on the pattern of tissue differentiation in a long bone fracture – an FEM study. *Journal of Biomechanics*. 2000; 33(4):415-425.
- Global Human Body Model Consortium. GHBMCM50 Users Manual Version 4.5. 2016.
- Nicayenzi B, Shah S, Schemitsch EH, Bougherara H, Zdero R. The biomechanical effect of changes in cancellous bone density on synthetic femur behaviour. Proceedings of the Institution of Mechanical Engineers, Part H. *Journal of Engineering in Medicine*. 2011; 225(11):1050-1060.
- Gardner MP, Chong AC, Pollock AG, Wooley PH. Mechanical evaluation of large-size fourth-generation composite femur and tibia models. *Annals of Biomedical Engineering*. 2010; 38(3):613-620.


PHYSICIAN ASSISTANTS 2021-2022



Nick Calabrese, PA-C
Adult Reconstruction



Traci Mahoney, PA-C
Adult Reconstruction



Chad Wilson, PA-C
Adult Reconstruction



Jim Shorten, PA-C
Foot & Ankle



Andrea White, PA-C
Foot & Ankle



Kelsey Parente, PA-C
Hand and Upper Extremity



Amy Radigan, PA-C
Hand and Upper Extremity



Emily Feiner, PA-C
Pediatrics



Megan Abrams, PA-C
Spine



Sara Rynders, PA-C
Spine



Rose Tyger, PA-C
Spine



Claire Denny, PA-C
Sports



Jen Hart, PA-C
Sports



GM Pugh, PA-C
Sports



Claire McMahon, FNP-C
Trauma




Jacquelyn Wilson, PA-C
Trauma

FELLOWS 2021-2022



Conner Ryan, MD
Adult Reconstruction



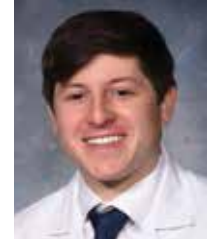
Wells Stewart, MD
Adult Reconstruction



B. Dale Sharpe, DO
Foot & Ankle



Andrew Ence, MD
Hand and Upper Extremity



Eduardo Natal, MD
Hand and Upper Extremity




Chuck Frank, MD
Spine



Laurel Barras, MD
Sports Medicine




Ryan Graf, MD
Sports Medicine



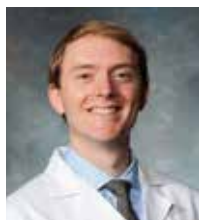
Ian MacLean, MD
Sports Medicine

RESIDENTS 2021-2022




Francis Bustos, MD

Chief



Matt Deasey, MD

Chief




Emanuel Haug, MD

Chief




Nicole Quinlan, MD

Chief



Baris Yildirim, MD

Chief




Ian Backlund, MD

PGY4




James Burgess, MD

PGY4




Zach Burnett, MD

PGY4




Tim Lancaster, MD

PGY4



David Noble, MD

PGY4




Cara Thorne, MD

PGY4




Alyssa Althoff, MD

PGY3




Neil Blanchard, MD

PGY3



Pearson Gean, MD

PGY3



Thomas Moran, MD

PGY3



Monica Arney, MD

PGY2



Richard Campbell, MD

PGY2



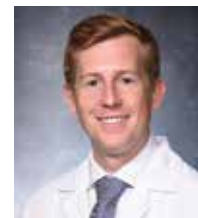
Lawal Labaran, MD

PGY2



Eliza Pelrine, MD

PGY2



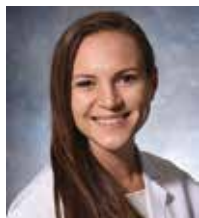Jeff Ruland, MD

PGY2



Pradip Ramamurti, MD

INTERN



Katie Schultz, MD

INTERN




Josh Schwartz, MD

INTERN



Vaib Tadepalli, MD

INTERN



Jesse Wang, MD

INTERN

Race, Gender, and Residency: A Survey of Trainee Experience

Surajudeen A. Bolarinwa, MD

University of Virginia,
Department of Orthopaedic Surgery
Charlottesville, VA

BACKGROUND

It has been previously observed that different groups, namely racial minorities and female trainees, undergo attrition at significantly higher rates than their counterparts. This is particularly concerning as it implies that simply having certain demographics can portend a diminished residency training experience. We hypothesize that racial minority and female trainees will report significantly different training experiences from counterpart demographics (non-minority and male, respectively) based on their responses to questions probing the key elements of their residency experience. Further, we hypothesize that thoughts of withdrawal and summative description of residency experience will be significantly impacted by access to mentorship and feelings of isolation.

METHODS

An anonymous link to a Qualtrics survey was distributed to trainees across all specialties in the US via program directors and coordinators. The survey was live from June through August of 2019 and collected data about respondent's demographics and posed questions addressing key elements of the residency experience. Responses were compared across demographics.

RESULTS

Minority trainees reported lower scores for ease of execution of orders placed compared to non-minority trainees. Females reported more frequently being mistaken for staff at lower training levels and more frequently feeling overwhelmed than male trainees, respectively. Males reported greater frequency of excess reprimand than female trainees. There was no significant difference between racial groupings or between gender groupings regarding access to mentorship or feelings of isolation. Using the entire sample, trainees who

had any thoughts of withdrawal reported less access to mentorship (3.12 vs. 3.88 $p = 0.001$) and more feelings of isolation (2.22 vs. 1.68 $p = 0.001$). Trainees who reported a more positive experience had greater access to mentorship and lower feelings of isolation than those who reported a neutral or negative experience, 3.89 vs. 3.14 vs. 2.79 ($p = 0.001$) and 1.60 vs. 2.21 vs. 2.82 ($p = 0.001$), respectively. Greater access to mentorship and more frequent family contact both significantly decreased feelings of isolation $p = 0.001$ and $p = 0.035$, respectively.

CONCLUSION

Racial minority status and female gender significantly impact some of the key elements of the residency experience. Thoughts of withdrawal and overall residency experience are significantly impacted by access to mentorship and feelings of isolation during residency. Access to mentorship and frequency of family contact significantly impact feelings of isolation. Special attention should be paid to ensuring that high risk trainees have adequate access to mentorship, as well as to cultivating a sense of community in a program that helps to combat feelings of isolation. ■

Gait Analysis Following Intramedullary Nailing of Midshaft Femur Fractures: How Surgical Approach Affects Early Post-operative Gait Patterns

Michael M. Hadeed, MD; John Mead;
Emily Dooley, RT(R); Shawn D. Russell, MD;
David B. Weiss, MD; Seth Yarboro, MD

University of Virginia,
Department of Orthopaedic Surgery
Charlottesville, VA

INTRODUCTION

Surgical approach for intramedullary nailing of midshaft femur fractures is often surgeon dependent. Early comparative studies noted an increase in hip pain after the antegrade approach and an increase in knee pain after the retrograde approach. Healing rates are similar between the two

approaches. The purpose of this study was to (1) determine if intramedullary nailing after midshaft femur fractures altered gait mechanics, (2) determine how long after surgery the gait patterns returned to normal, and (3) determine whether the gait changes were different based on surgical approach.

METHODS

Consecutive patients at a level 1 trauma center were screened for this prospective study between 2018 and 2020. Inclusion criteria were age > 18 and a midshaft femur fracture that could be treated with either a retrograde or antegrade femoral nail (as decided by the treating surgeon). Exclusion criteria were any fracture extension proximal or distal which would dictate a specific approach or concomitant injuries which would be expected to affect gait patterns. Gait analysis was completed at regular intervals (2, 6, 12, 26 weeks). Subjects were recorded using 3D motion capture and five force plates. Walking trials were collected on a 15 m walkway at a self-selected walking speed. A minimum of six trials were analyzed for each subject at each time point. The Plug-in-Gait mod-

el was used to calculate joint kinematics and kinetics, then exported to Matlab for analysis.

RESULTS

Gait kinematics were altered compared to normal controls in the post-operative period after intramedullary nailing for femoral shaft fractures. Antegrade patients showed significantly less deviation from the control group compared to retrograde patients. Gait patterns returned to near normal at the six-month timepoint. There was no difference in the rate of normalization. There were key differences to the gait kinematics depending on the surgical approach used. Retrograde patients had reduced knee flexion during early stance, an increased knee abduction moment, a decreased knee extension moment, and a decreased hip extension moment. The de-

creased flexion and extension of the injured knee combined with the decreased hip extension moment indicate that the patients walked with a straighter injured leg, leading to the increased knee abduction moment. Antegrade patients displayed a decrease in hip abduction moment and hip adduction angle.

CONCLUSIONS

This pilot data indicated that the approach for femoral nailing of midshaft femur fractures did affect early-postoperative gait mechanics. The retrograde cohort had significantly more deviation from a normal gait post-operatively. This may be important as surgeons strive to return patients to previous levels of function expeditiously in the post-operative period. More data is needed to draw conclusions which may affect clinical practice. ■

The Influence of Peri-Operative Nerve Block on Strength and Functional Return to Sports After Anterior Cruciate Ligament Reconstruction

Michelle E. Kew, MD; Stephan G. Bodkin, PhD; David R. Diduch, MD; Marvin K. Smith, MD, Anthony Wiggins, MD; Stephen F. Brockmeier, MD; Brian C. Werner, MD; F. Winston Gwathmey, MD; Mark D. Miller, MD; Joseph M. Hart, PhD

University of Virginia,
Department of Orthopaedic Surgery
Charlottesville, VA

ABSTRACT

Background: Patients often present with quadriceps or hamstring weakness following anterior cruciate ligament reconstruction (ACLR), despite postoperative physical therapy regimens; however, little evidence exists connecting nerve blocks and ACLR outcomes.

Purpose: The purpose of this study was to

compare muscle strength at return-to-play in patients who received a nerve block with ACLR, and whether a specific block type affected functional outcomes.

Study Design: Retrospective cohort study

Methods: Patients were recruited 5-7 months following primary, isolated ACLR and completed bilateral isokinetic strength tests of the knee extensor/flexor groups as a single session return-to-sport test. Strength was expressed as torque normalized to mass (Nm/kg) and limb-symmetry-index (LSI) as involved/uninvolved torque. Chart review determined the type of nerve block and graft used. Nerve block types were

classified as Knee Extensor Motor (femoral nerve), Knee Flexor Motor (sciatic nerve), or Isolated Sensory (adductor canal block/saphenous nerve). A one-way ANCOVA controlling for graft-type was used.

Results: A total of 169 patients were included. Graft type distribution: 102 (60.4%) ipsilateral bone patellar tendon bone (BTB), 67 (39.6%) ipsilateral hamstring (HS) tendon. Nerve block type distribution: 38 (22.5%) femoral, 25 (14.8%) saphenous, 45 (26.6%) femoral and sciatic, 61 (36.1%) saphenous and sciatic. No significant difference was found in knee extensor strength ($p = 0.113$) or symmetry ($p = 0.860$) between patients with Knee Extensor Motor blocks ($1.57 \pm .048$ Nm/kg, $70.1 \pm 0.18\%$) and those without ($1.47 \pm .047$ Nm/kg, $69.6 \pm .018\%$). A significant difference was found between patients with Knee Flexor Motor blocks ($0.83 \pm .027$ Nm/kg) and those without ($0.92 \pm .027$ Nm/kg) for normalized knee flexor strength ($p = 0.021$), but not knee flexor symmetry ($p = 0.592$).

Conclusion: Our data shows that use of a sciatic nerve block with ACLR in patients with HS and BTB grafts influences persistent knee flexor strength deficits at time of return-to-sport. Although the etiology

of postoperative muscular weakness is multifactorial, this study adds to the growing body of evidence suggesting that peri-operative nerve block affect muscular strength and functional rehabilitation after ACLR. ■

Evaluation of 30-Day Mortality Risk After Hip Fracture Surgery Using the Revised Cardiac Risk Index

Harrison Mahon, MD; Wendy Novicoff, PhD; Seth Yarboro, MD

University of Virginia,
Department of Orthopaedic Surgery
Charlottesville, VA

INTRODUCTION

Hip fractures are common among the elderly and carry a high rate of mortality, even when treated operatively. Several mortality risk prediction tools are used to predict early mortality after surgery, and many of these tools are not specific to hip fracture patients. One of the most commonly used tools is the Revised Cardiac Risk Index (RCRI). This study aims to retrospectively apply the RCRI to a cohort of patients at the University of Virginia that were treated surgically for a hip fracture. The goal of this study is to assess whether the RCRI can accurately predict 30-day mortality in patients undergoing surgery for hip fracture.

METHODS

311 patients who underwent surgical fixation of a hip fracture between 205 and 2017 at the University of Virginia were retrospectively evaluated based on the risk factors included in the RCRI. Patients younger than 65, periprosthetic fractures, revision procedures, and fractures treated

non-operatively were excluded. The primary outcome was 30-day mortality.

RESULTS

In our cohort of 311 patients treated surgically for hip fractures, 19 died within 30 days after surgery (6.1%). No significant correlation was found between total RCRI score and 30-day mortality risk ($r = 0.08$, $p = 0.17$). There was also no significant difference in RCRI score between patients who died within 30-days and those who did not ($p = 0.14$). Although the expected mortality rates based on RCRI risk class were similar to the observed mortality rates in each risk class group, the differences between these groups were not statistically significant ($p = 0.30$).

CONCLUSION

The Revised Cardiac Risk Index is widely used for predicting early mortality after surgery, but has not been extensively studied in hip fracture patients. In a cohort of patients undergoing hip fracture surgery at the University of Virginia, RCRI was found to not be significantly associated with 30-day mortality risk. Use of a risk prediction tool that is specific to hip fracture patients should be considered when estimating early mortality risk after hip fracture surgery. ■

Examining the Relationship Between Missed Doses of VTE Prophylaxis and VTE Events in The Trauma Population

Alyssa Althoff, MD; Alicia Eubanks, MD; Beth Turrentine; John Davis, MD

University of Virginia,
Department of Orthopaedic Surgery
Charlottesville, VA

INTRODUCTION

Venous thromboembolism (VTE) events are costly and can be fatal, but steps can be taken to reduce the risk of an event. Risk factors for developing a deep vein thrombosis or pulmonary embolus have previously been examined, however, missed VTE doses have not been well-studied. The goal of the current study is to examine the relationship between missed doses of VTE prophylaxis and VTE events in the trauma population.

METHODS

Adult patients (> 18 years of age) admitted to the University of Virginia Acute Care and Trauma Surgery Service (1/1/2018-10/13/2020) who underwent a procedure were included in the dataset. Demographic and comorbidity variables were abstracted. VTE rates, VTE prophylaxis dosing, and medication utilization were obtained from the electronic health record. Reasons for missing VTE doses were abstracted

from manual review of the health record and coded. Chi square was used to compare proportions.

RESULTS

1,144 trauma service patients underwent a procedure during the study period. Of the included patients, 32 (2.79%) had a documented VTE event. VTE events were significantly higher in those who missed a dose of VTE prophylaxis compared to those who did not (6.6% vs. 0.5%, $P < 0.0001$, respectively). See Table. The first missed dose occurred a median of 3 days after surgery.

Table. Adult Trauma patients with and without missed doses of VTE prophylaxis (2018-2020)

	Missed VTE prophylaxis doses N = 420	No Missed VTE prophylaxis doses N = 724	P-Value
Gender, male n (%)	257 (61)	396 (55)	
Age, mean, years	52	52	
Race, white	329 (78)	602 (83)	
Emergency	360 (86)	577 (80)	
Heparin, missed prophylaxis	166 (40)	-	
Enoxaparin, missed prophylaxis	249 (59)	-	
LOS, mean, days	15.3	7	
DVT/PE	28 (6.6)	4 (0.5)	< 0.0001

CONCLUSIONS

Missed doses of VTE prophylaxis impact VTE events. A better understanding why

prophylactic VTE doses are missed may provide opportunities to improve clinical outcomes. ■

Suture Repair of the Deltoid Ligament is an Effective Alternative to Traditional Suture Anchor Repair: A Clinical and Biomechanical Analysis

Max Hoggard, MD; Seth Yarboro, MD

University of Virginia,
Department of Orthopaedic Surgery
Charlottesville, VA

BACKGROUND

The deltoid ligament is a critical stabilizer of the ankle and an important determinant of tibiotalar kinematics. Approximately 40% of ankle fractures have a concomitant deltoid ligament injury and repair of these injuries has been shown to aid in fracture reduction and overall ankle stability. Multiple repair options have been described, with direct suture-only repair and suture anchor techniques being common. The purpose of this investigation is to compare the clinical and radiographic outcomes of these techniques, as well as their biomechanical implications. It is hypothesized that suture-only deltoid

ligament repair reliably accomplishes ankle stability and does not result in inferior radiographic or biomechanical results compared to repair with the suture anchor repair.

METHODS

A retrospective review was performed of 12 patients treated operatively for isolated deltoid ligament disruption. Patients were matched 1:1 based on demographic and surgical technique of deltoid ligament repair with barbed PDS suture alone versus with suture anchor. Patients were evaluated clinically and radiographically at 6-weeks and 3-months postoperatively. Additionally, 4 cadaveric specimens were obtained and prepared to simulate deltoid ligament injury. The specimens were tested to simulate both weightbearing and external rotation stresses using a hydraulic material testing apparatus. Relative rotational and trans-

lational changes were compared between specimens repaired with suture only and those repaired with suture anchors.

RESULTS

At 6-week and 3-month evaluation, patients in the suture-only group did not demonstrate radiographic evidence of medial clear space widening and had not undergone repeat surgery. One patient (16%) in the suture anchor group demonstrated medial clear space widening at 6 weeks. Also, 1 patient (16%) in the suture anchor group had undergone repeat surgery at 3-month evaluation. Two patients in the suture group endorsed intermittent pain with prolonged standing (33%) at 3 months, but all had returned to work ($n = 6$, 100%).

CONCLUSIONS

Deltoid suture repair with barbed PDS suture effectively reduces and maintains the medial clear space and is not inferior to traditional fixation in radiographic outcomes at 3 months following initial surgical intervention. It is a viable alternative to suture anchor repair while minimizing adverse events, sequelae, and cost of traditional approaches. ■

Allograft Bone Dowels Show Better Incorporation in Femoral versus Tibial Tunnels in Two-Stage Revision Anterior Cruciate Ligament Reconstruction: A CT-based Analysis

Thomas E. Moran, MD; Alex J. Demers, BS; Kaitlyn M. Shank, Ed, ATC; John T. Awowale, MD; Mark D. Miller, MD

University of Virginia,
Department of Orthopaedic Surgery
Charlottesville, VA

INTRODUCTION

Adequate arthroscopic examination and intervention requires complete visualization of the accessible intra-articular anatomy. Certain areas of the knee, specifically the posterior medial compartment, can be challenging to access for full visualiza-

Our group's published systematic review on percutaneous medial collateral ligament release found that there is very little short- or long-term morbidity associated with this procedure, but there is a paucity of data quantifying how much additional working space is produced in the medial compartment with its performance.

tion or allow for instrumentation without causing iatrogenic cartilage damage. The percutaneous, outside-in technique of "pie-crusting" the medial collateral ligament is one technique that allows for improved access to the posterior medial

compartment. Our group's published systematic review on percutaneous medial collateral ligament release found that there is very little short- or long-term morbidity associated with this procedure, but there is a paucity of data quantifying how much additional working space is produced in the medial compartment with its performance. It also remains unclear how long any iatrogenic laxity takes to resolve or whether bracing is required postoperatively. The purpose of this study was to quantify intraoperative joint space widening afforded by the outside-in, percutaneous release of the medial collateral ligament, and to evaluate its impact on medial compartment width and functional outcomes at six-week follow-up for patients undergoing a partial medial meniscectomy without postoperative bracing.

METHODS

Institutional Review Board approval was obtained. Patients met criteria for inclusion in this study if they were identified as having a posteromedial meniscus tear, with no evidence of ipsilateral knee pathology, and were electively undergoing partial medial meniscectomy. Patients were excluded if the operative knee was identified as having pre-existing varus or valgus laxity, had undergone prior ligamentous reconstruction, had malalignment greater than five degrees, or had Kellgren and Lawrence grade 3 to 4 arthrosis. Intraoperatively, medial compartment width was quantified

with fluoroscopy before and after performance of the percutaneous MCL release with an 18-gauge spinal needle proximal to the joint line. At six-week follow-up valgus stress radiographs re-evaluated medial compartment width. IKDC and PROMIS scores were completed pre-operatively and at six-week follow-up to evaluate functional outcomes in patients undergoing MCL release. A paired sample t-test performed at a 95% confidence interval was utilized to compare these variables.

RESULTS

Forty-two patients, with a mean age of 55.3 ± 10.7 years, were available for analysis of intraoperative medial compartment widening. Medial compartment width increased from a mean of 5.95 ± 1.32 mm to 11.09 ± 1.74 mm intraoperatively following the MCL release. At six week follow-up, radiographic assessment demonstrated a mean medial compartment width of $5.85 \pm .99$ mm, which represented an insignificant change in comparison to the preoperative value (CI[-.68-.33], $p = .474$). PROMIS and IKDC scores significantly improved from baseline, with increases of 6.9 ± 12.4 (CI[2.0-11.8], $p = .008$) and 11.7 ± 17.8 (CI[4.7-18.8], $p = .002$), respectively.

CONCLUSIONS

Percutaneous MCL release during knee arthroscopy improves visualization and facilitates instrumentation by providing an almost two-times wider working space within the medial tibiofemoral joint. In this study, the performance of percutaneous MCL release did not result in any complications. Radiographic and clinical resolution of iatrogenic laxity is demonstrated by six-weeks postoperatively, without the use of postoperative bracing. ■

Trends in Hospital and Surgeon Charges and Reimbursements for Revision Total Knee Arthroplasty

Nicole Quinlan, MD; Alyssa Althoff, MD;
Dennis Chen, MD; Brian Werner, MD;
Thomas Brown, MD; James Browne, MD

University of Virginia,
Department of Orthopaedic Surgery
Charlottesville, VA

INTRODUCTION

The relationship between surgeon and hospital charges and reimbursements for revision TKA has not been well examined. The objective of this study is to report trends and variation in hospital charges and payments compared to surgeons for stage 1 (S1) vs. stage 2 (S2) revision of septic TKA, and aseptic revision (AR) TKA.

METHODS

The 5% Medicare sample was used to capture hospital and surgeon charges and payments for revision TKA from 2005-2014. The

charge multiplier (CM), ratio of hospital to surgeon charges, and the payment multiplier (PM), ratio of hospital to surgeon payments, were calculated. Year to year variation and regional trends in patient demographics, Charlson Comorbidity Index (CCI), length of stay (LOS), CM and PM were evaluated. Statistical significance of trends was evaluated using simple linear regression analysis. Correlations between the financial multipliers and LOS were evaluated using a Pearson correlation coefficient (r).

RESULTS

4,570 AR TKA patients were included, as well as 1,323 S1 and 863 S2 revision patients. Hospital charges were significantly higher than surgeon charges for all cohorts and increased over time: from 8.1 to 13.8 for AR ($p < 0.001$), from 21.0 to 22.5 ($p = 0.07$) for S1, and from 11.8 to 22.0 ($p < 0.001$) for S2. PM followed a similar trend,

As healthcare shifts toward value-based care with shared responsibility for outcomes and cost, more closely aligned incentives between hospitals and providers are needed.

increasing 8.1 to 13.8 ($p < 0.001$) for AR, 19.8 to 27.3 ($p = 0.005$) for S1, and 14.7 to 30.7 ($p < 0.001$) for S2. Surgeon reimbursement decreased over time for all cohorts. LOS decreased for AR from 3.8 to 2.8 days, for S1 from 12.8 to 6.9 days, and for S2 from 4.5 to 3.9 days. CCI remained stable for the AR cohort but increased significantly for the S1 and S2 cohorts.

CONCLUSIONS

Hospital charges and payments relative to surgeon charges and payments have significantly increased for AR, S1 and S2 revision TKA despite stable or increasing patient complexity and decreasing LOS. As healthcare shifts toward value-based care with shared responsibility for outcomes and cost, more closely aligned incentives between hospitals and providers are needed. ■

DEPARTMENT SPOTLIGHT



UVA Sports Medicine and the Department of Kinesiology receive the 2020 UVA Collaboration Award via Zoom award ceremony


Sports Division Recognized with University-Wide Research Award

In 2014, the Sports Medicine Division initiated an outcomes assessment program for patients recovering from ACL reconstruction. The Lower Extremity Assessment Program (LEAP) is a point of care research partnership with the Department of Kinesiology where we perform routine strength, function and subjective evaluations on all patients with ACL reconstructions at 4, 6 and 8 months following surgery. LEAP data are used to guide rehabilitation progress and return-to-sports decisions. To date, we


have compiled data from over 1000 participants and nearly 2000 time-points. This project has led to over 30 peer-reviewed publications in top orthopaedic and rehabilitation journals and nearly twice as many abstract presentations at state, national and international society meetings. This research team was awarded the 2020 Collaboration Award – honored at the annual UVA [virtual] Research Achievement Award ceremony hosted by the UVA's President Ryan and the Vice President for Research.

Quality Presentation 2021 Total Joint PSQC

Average Length of Stay




- 1.74 average length of stay for Total Hip Patients
- 1.5 average length of stay for Total Knee Patients



The current efforts to improve performance include:

- Enhanced Recovery After Surgery
- Co-management
- Care coordination beginning in clinic
- Early mobility emphasis with therapies

Mortality




Zero mortalities within Total Joint patient population FY 21

The current efforts to improve performance include:

- Risk assessment and stratification
- Co-management

DVT/PE Incidence




Zero DVT/PE within Total Joint population FY 21

The current efforts to improve performance include:

- Risk stratification
- Early mobilization with reduced LOS
- Evidence-based protocols for prophylaxis in place

Service Line Presentation 2020 PSQC MSK

Hospital-Acquired Pressure Ulcer Stage II and Above



- FY20 Goal for HAPU Prevalence achieved
- Performance improved as evidenced by run rate

The current efforts to improve performance include:

- Standard Work
- Early mobility emphasis with therapies
- Team effort to minimize inpatient length of stay

30 Day Readmissions



- 30-Day All Cause Readmission Rates remain between threshold and target
- Favorable trend over 35 month run, lowest rate in history of SL
- MSK averaged 3.5 readmissions per month FYTD 20; 1.05 are planned.

The current efforts to improve performance include:

- Appropriate discharge disposition
- Ensure timely follow-up
- Care coordination

Team Member Injuries



- Total Case Incident Rate (TCIR) target was met for FY20
- Injuries were sprains/strains
- Injuries were typically related to patient handling
- Injuries were typically on MSK acute floor (6 East)

The current efforts to improve performance include:

- Standard work
- Utilization of minimal lift equipment
- Unit RN and PCA/T completion of Smart Move Coach training

2020-2021 Peer-Reviewed Publication Bibliography

1. Barras L, **Diduch DR**. Trochlea anatomy and surgery. In: Sherman S, Chahla J, Rodeo S, eds. *Knee Arthroscopy and Knee Preservation Surgery*. Springer; 2022: In press.
2. Gean RP, **Diduch D**. Patellofemoral disorders. In: **Werner B**, ed. *MRI-Arthroscopy Correlations: A Case Based Atlas of the Knee, Shoulder, Elbow, Hip and Ankle*. 2nd Edition. Springer; 2022: In press.
3. **Diduch DR**, Ed. Patellofemoral Instability Decision Making and Techniques, *An Issue of Clinics in Sports Medicine*. Elsevier; 2022.
4. Anderson G, **Diduch D**. MPFL reconstruction – Tips and tricks to get it right. In: **Diduch DR**, ed. *Patellofemoral Instability Decision Making and Techniques, An Issue of Clinics in Sports Medicine*. Elsevier; 2022.
5. **Hassanzadeh H**, Bell J, Doolley E, Puvanesarajah V, Kamalopathy P, Labaran L, **Shimer A**, **Shen FH**, Russell S. Evaluation of gait and functional stability in preoperative cervical spondylotic myelopathy patients. *Spine*. 2022 Feb 15;47(4):317-323. doi: 10.1097/BRS.0000000000004235.
6. Kew ME, Bodkin S, **Diduch DR**, **Brockmeier SF**, Lesevic M, **Hart JM**, **Werner BC**. Reinjury rates in adolescent patients 2 years following ACL Reconstruction. *J Pediatr Orthop*. 2022 Feb 1;42(2):90-95. doi: 10.1097/BPO.0000000000002031.
7. **Shen FH**, Gasbarrini A, Lui DF, Reynolds J, Capua J, Boriani S. Integrated custom composite polyetheretherketone/carbon fiber (PEEK/CF) vertebral body replacement (VBR) in the treatment of bone tumors of the spine: A preliminary report from a multicenter study. *Spine*. 2022 Feb 1;47(3):252-260. doi: 10.1097/BRS.0000000000004177.
8. Chen AF, Barrington JW, Duwelius PJ, **Browne JA**, Sporer SM, Gioe T, Porter K, Hsue P, Stavrakis AI. Trends in femoral neck fracture treatment using total hip arthroplasty: Reported from the American joint replacement registry. *J Am Acad Orthop Surg*. 2022 Jan 1;30(1):e124-e130. doi: 10.5435/JAAOS-D-21-00530.
9. Kamalopathy P, Moore A, **Brockmeier S**, **Diduch DR**. Status quo: Trends in diversity and unique traits among orthopaedic sports medicine fellowship directors. *J Am Acad Orthop Surg*. 2022 Jan 1;30(1):36-43. doi: 10.5435/JAAOS-D-21-00211
10. Porter KR, Illgen RL, Springer BD, Bozic KJ, Sporer SM, Hud-

dleston JI, Lewallen DG, **Browne JA**. Is American joint replacement registry data representative of national data? A comparative analysis. *J Am Acad Orthop Surg*. 2022 Jan 1;30(1):e124-e130. doi: 10.5435/JAAOS-D-21-00530. Epub 2021 Aug 25.

11. Kamalopathy PN, Vatani J, Raso J, **Hassanzadeh H**, Li X. How old is too old?: Matched analysis of geriatric patients undergoing anterior lumbar interbody fusion. *Clin Neurol Neurosurg*. 2022 Jan;212:107090. doi: 10.1016/j.clineuro.2021.107090. Epub 2021 Dec 14.

12. Passias PG, Brown AE, Bortz C, Alas H, Pierce K, Ahmad W, Naessig S, Lafage R, Lafage V, **Hassanzadeh H**, Labaran LA, Ames C, Burton DC, Gum J, Hart R, Hostin R, Kebaish KM, Neuman BJ, Bess S, Line B, Shaffrey C, Smith J, Schwab F, Klineberg E; International Spine Study Group. Increasing cost efficiency in adult spinal deformity surgery: Identifying predictors of lower total costs. *Spine*. 2022 Jan 1;47(1):21-26. doi: 10.1097/BRS.0000000000004201.

13. METRC; Stinner DJ, Rivera JC, Smith CS, **Weiss DB**, Hymes RA, Matuszewski PE, Gary JL, Morshed S, Schmidt AH, Wilken JM, Archer KR, Bailey L, Kleihege J, McLaughlin KH, Thompson RE, Chung S, Remenapp C, MacKenzie EJ, Reider L. Early advanced weight-bearing after periarticular fractures: A randomized trial comparing antigavity treadmill therapy versus standard of care. *J Orthop Trauma*. 2022 Jan 1;36(Suppl 1):S8-S13. doi: 10.1097/BOT.0000000000002285.

14. Quinn C, Ignozzi A, **Diduch D**. Meniscal root repair. In: Cole B, Chahla J, eds. *Surgical Techniques of the Shoulder, Elbow and Knee in Sports Medicine*. Elsevier, 2021: In press.

15. Quinn C, Ignozzi A, **Diduch D**. Arthroscopic meniscal repair: All inside technique. In: Cole B, Chahla J, eds. *Surgical Techniques of the Shoulder, Elbow and Knee in Sports Medicine*. Elsevier; 2021: In press.

16. Eliasberg CD, **Diduch DR**, Strickland S. Failure of patellofemoral joint preservation. In: Gomoll A, ed. *Operative Techniques in Sports Medicine*. Elsevier; 2001: In press.

17. **Werner BC**. Are we actually guided by clinical practice guidelines? Commentary and perspective on “Hyaluronic acid injections for knee osteoarthritis: Has utilization among Medicare beneficiaries changed between 2012-2018?” *JBJS*. 2021; In press.

18. Kamalopathy PN, Dunne PJ, **Yarboro S**. National evaluation of social determinants of health in orthopaedic fracture care: Decreased social determinants of health is associated with increased adverse complications after surgery. *J Orthop Trauma*. 2021 Dec 17. doi: 10.1097/BOT.0000000000002331.

19. Kuruvilla SI, Schaeffer CV, **Cooper MT**, DeGeorge BR Jr. The feasibility of targeted muscle reinnervation for the management of Morton’s neuroma. *Foot Ankle Spec*. 2021 Dec 2;19386400211002702. doi: 10.1177/19386400211002702. Online ahead of print.

20. Mont MA, Backstein DJ, **Browne JA**, Krebs VE, Krueger CA, Mason JB, Taunton MJ, Callaghan JJ. Our efforts towards a diversity pledge. *J Arthroplasty*. 2021 Dec;36(12):3823-3824. doi: 10.1016/j.arth.2021.10.007.

21. **Shen FH** et al. Use of the dual construct lowers rod strains in flexion-extension and lateral bending compared to two-rod and two-rod satellite constructs in a cadaveric spine corpectomy model. *Spine J*. 2021 Dec;21(12):2104-2111. doi: 10.1016/j.spinee.2021.05.022. Epub 2021 May 29.

22. Burrus MT, Denard PJ, Lederman E, Gobezie R, **Werner BC**. Reverse total shoulder arthroplasty for patients with preserved active elevation and moderate to severe pain: A matched cohort study. *JSES International*. 2021 Nov 19. <https://doi.org/10.1016/j.jseint.2021.10.004>.

23. Cole EW, Moulton SG, **Werner BC**, Denard PJ. Why patients fail to achieve a patient acceptable symptom state (PASS) after total shoulder arthroplasty. *JSES Int*. 2021 Nov 16. doi: <https://doi.org/10.1016/j.jseint.2021.09.017>

24. Wang KY, McNeely EL, Dhanjani SA, Raad M, Puvanesarajah V, Neuman BJ, Cohen D, Khanna AJ, Kebaish F, **Hassanzadeh H**, Kebaish KM. COVID-19 significantly impacted hospital length of stay and discharge patterns for adult spinal deformity patients. *Spine*. 2021 Nov 15;46(22):1551-1556. doi: 10.1097/BRS.0000000000004204.

25. **Werner BC**, McClish SJ, Mealey NC, Wijdicks C, Thompson T, Higgins LD. A biomechanical comparison of subscapularis tenotomy repair techniques for stemless shoulder arthroplasty. *J Shoulder Elbow Surg*. 2021 Nov 11; S1058-2746(21)00776-X. doi: 10.1016/j.jse.2021.10.017. Online ahead of print.

26. Kamalopathy PN, **Hassanzadeh H**, et al. Propensity scored analysis of outpatient anterior lumbar interbody fusion: No increased complications. *Clin Spine Surg*. 2021 Nov 4. doi: 10.1097/BSD.0000000000001271. Online ahead of print.

27. Verhey JT, Deckey DG, Tummala S, Hasebrock JD, Dulle D, Long JR, **Miller MD**, **Chhabra A**. A novel meniscofemoral ligament variant intra-substance to the PCL. *Knee Surg Sports Traumatol Arthrosc*. 2021 Nov 3. doi: 10.1007/s00167-021-06791-6. Epub ahead of print.

28. Cancienne JM, Walters JD, Denard PJ, Garrigues GE, **Werner BC**. Use of preoperative advanced imaging for reverse total shoulder arthroplasty. *JSES Arthro*. 2021 Nov 1;31(4):791-797. doi: <https://doi.org/10.1053/j.sart.2021.05.007>. Epub 2021 Jun 1.

29. Denard PJ, **Werner BC**, Gobezie R, Cohen BS, Lederman E. Cause for revision differs between a short and standard length stem at 5 year follow-up. *JSES Arthro*. 2021 Nov 1;31(4):836-841. doi: <https://doi.org/10.1053/j.sart.2021.05.014>. ePub 2021 Jul 17.

30. Griffin JW, Denard PJ, Romeo AA, Gobezie R, Lederman E, **Werner BC**. Inclination correction is associated with improved clinical outcomes in anatomic total shoulder arthroplasty. *JSES Arthro*. 2021 Nov 1;31(4):557-562. doi: <https://doi.org/10.1053/j.sart.2021.03.005>.

31. **Werner BC**, Creighton RA, Denard PJ, Lederman ES, Romeo AA, Griffin JW. Prosthetic humeral head center of rotation shift from ideal is associated with inferior clinical outcomes after anatomic total shoulder arthroplasty. *JSES Arthro*. 2021 Nov 1;31(4):668-676. doi: <https://doi.org/10.1053/j.sart.2021.04.004>.

32. **Werner BC**, Lederman ES, Gobezie R, Denard PJ. Understanding the variables that are associated with failure to achieve an acceptable symptom state after reverse shoulder arthroplasty. *JSES Arthro*. 2021 Nov 1;31(4):730-736. doi: <https://doi.org/10.1053/j.sart.2021.05.001>. ePub 2021 May 25.

33. **Werner BC**, Lederman E, Gobezie R, Denard PJ. Glenoid lateralization influences active internal rotation after reverse shoulder arthroplasty. *J Shoulder Elbow Surg*. 2021 Nov;30(11):2498-2505. doi: 10.1016/j.jse.2021.02.021. Epub 2021 Mar 19.

34. Moran T, Ignozzi A, Dart S, **Diduch DR**. Technical considerations for an anteromedializing tibial tubercle osteotomy. *VJSM*. 2021 Nov 1;1(6). doi: 10.1177/26350254211045994.

35. **Chhabra AB**, Yildirim B. Adult distal radius fracture management. *J Am Acad Orthop Surg*. 2021 Nov;29(22):e1105-e1116. doi: 10.5435/JAAOS-D-20-01335.

36. Bradford PS, Akyeampong D, Fleming MA 2nd, **Dacus AR**, **Chhabra AB**, **DeGeorge BR Jr**. Racial and gender discrimination in hand surgery letters of recommendation. *J Hand Surg Am*. 2021 Nov;46(11):998-1005.e2. doi: 10.1016/j.jhsa.2021.07.009. Epub 2021 Aug 20.

37. Erickson BJ, **Werner BC**, Griffin JW, Gobezie R, Lederman E, Sears B, Denard PJ. A comprehensive evaluation of the association of radiographic measures of lateralization with clinical outcomes following reverse total shoulder arthroplasty. *J Shoulder Elbow Surg*. 2021 Oct 29;S1058-2746(21)00759-X. doi: 10.1016/j.jse.2021.10.010. Online ahead of print.
38. Kamalopathy PN, Sequeira S, Chen D, Bell J, **Park J, Werner BC**. Postoperative complications following ankle arthrodesis in patients with hepatitis C: Matched propensity score analysis. *Foot Ankle Spec*. 2021 Oct 28;19386400211053943. doi: 10.1177/19386400211053943. Online ahead of print.
39. Jin L, Xiao L, Ding M, Pan A, Balian G, Sung SS, Li X. Heterogeneous macrophages contribute to the pathology of disc herniation induced radiculopathy. *Spine J*. 2021 Oct 27;S1529-9430(21)00974-8. doi: 10.1016/j.spinee.2021.10.014. Online ahead of print.
40. Burrus MT, Griffin JW, Denard PJ, Lederman E, Gobezie R, **Werner BC**. Anatomic total shoulder arthroplasty for patients with preserved preoperative motion. *JSESArthro*. 2021 Oct 25. doi: <https://doi.org/10.1053/j.sart.2021.09.009>.
41. Anciano Granadillo VJ, **Werner BC**, Moran TE, **Park JS, Cooper MT**. Perioperative opioid analgesics and hallux valgus correction surgery: Trends, risk factors for prolonged use and complications. *J Foot Ankle Surg*. 2021 Oct 22;S1067-2516(21)00401-4. doi: 10.1053/j.jfas.2021.10.011. Online ahead of print.
42. Xiao W, Le Q, Zhu D, **Dighe A, Cui Q**, Yang X. Association of FPR1 gene expression with osteogenesis and adipogenesis of adipose derived stem cells. *Biochem Biophys Res Commun*. 2021 Oct 15;574:33-38. doi: 10.1016/j.bbrc.101.08.044. Epub 2021 Aug 19.
43. Casp AJ, Bodkin S, Smith MK, Tran SJ, **Gwathmey FW**, Carson E, **Werner B, Miller MD, Diduch DR, Brockmeier S, Hart J**. Effect of meniscal treatment on functional outcomes 6 months after anterior cruciate ligament reconstruction. *Orthop J Sports Med*. 2021 Oct 6;9(10):23259671211031281. doi: 10.1177/23259671211031281. eCollection 2021 Oct.
44. Moran TE, Ignozzi AJ, **Werner BC**. Comparing the use of flexible and rigid reaming systems through an anteromedial portal for femoral tunnel creation during ACL reconstruction: A systematic review. *Orthop J Sports Med*. 2021 Oct 4;9(10):23259671211035741. doi: 10.1177/23259671211035741. eCollection 2021 Oct.
45. **Miller MD**. Sports imaging: Plan your trip. *Clin Sports Med*. 2021 Oct;40(4):ix. doi: 10.1016/j.csm.2021.06.002.
46. Cancienne JM, Blanchard NP, Broome J, Dempsey IJ, **Werner BC**. Urinary tract infections diagnosed within two weeks prior to shoulder arthroplasty are associated with increased postoperative infection rates. *JSESArthro*. 2021 Oct. doi: 10.1053/j.sart.2021.08.006.
47. Chalian M, Nacey NC, Rawat U, Knight J, Lancaster T, **Deal DN**, Pierce J. Ultrasound-guided percutaneous needle tenotomy using Tenex system for refractory lateral epicondylitis; short and long-term effectiveness and contributing factors. *Skeletal Radiol*. 2021 Oct;50(10):2049-2057. doi: 10.1007/s00256-021-03778-9. Epub 2021 Apr 10.
48. **Werner BC**, Griffin JW, Thompson T, Lendhey M, Higgins LD, Denard PJ. Biomechanical evaluation of two techniques of repair after subscapularis peel for stemless shoulder arthroplasty. *J Shoulder Elbow Surg*. 2021 Oct;30(10):2240-2246. doi: 10.1016/j.jse.2021.01.037. Epub 2021 Mar 3.
49. Quinn CA, **Miller MD**, Turk RD, Lewis DC, Gaskin CM, **Werner BC**. Determining the ratio of wedge height to degree of correction for anterior tibial closing wedge osteotomies for excessive posterior tibial slope. *Am J Sports Med*. 2021 Sep 30;3635465211044136. doi: 10.1177/03635465211044136. Epub ahead of print.
50. Le Q, Madhu V, **Hart JM**, Farber CR, Zunder ER, **Dighe AS, Cui Q**. Current evidence on potential of adipose derived stem cells to enhance bone regeneration and future projection. *World J Stem Cells*. 2021 Sep 26;13(9):1248-1277. doi: 10.4252/wjsc.v13.i9.1248.
51. Keil LG, Mullis BH, Iii PT, Alley MC, Olszewski NP, Wheeler JA, von Kaeppler EP, Morshed S, Matar RN, Archdeacon MT, Smith TW, Miller AN, Horwitz DS, Baig MS, Telgheder ZL, Azer E, Manzano GW, Vallier HA, Barnett SA, Krause PC, Bornes TD, Ricci WM, Dunne PJ, **Yarboro SR**, Ment AJ, Marcantonio AJ, Alqudhaya RS, Leighton RK, Ostrum RF. Proximal tibia fracture dislocations: Management and outcomes of a severe and under-recognized injury. *Injury*. 2021 Sep 23;S0020-1383(21)00809-3. doi: 10.1016/j.injury.2021.09.035.
52. Segal DN, Ball J, Fletcher ND, Yoon E, Bastrom T, Vitale MG; Harms Study Group. Risk factors for the development of DJK in AIS patients undergoing posterior spinal instrumentation and fusion. *Spine Deform*. 2021 Sep 16. doi: 10.1007/s43390-021-00413-4. Online ahead of print.
53. Koldenhoven RM, **Hart J, Abel MF**, Saliba S, Hertel J. Running gait biomechanics in females with chronic ankle instability and ankle sprain copers. *Sports Biomech*. 2021 Sep 13:1-13. doi: 0.1080/14763141.2021.1977378. Online ahead of print.
54. **Miller MD**, Kew ME, Quinn CA. Anterior cruciate ligament revision reconstruction. *J Am Acad Orthop Surg*. 2021 Sep 1;29(17):723-731. doi: 10.5435/JAAOS-D-21-00088.
55. Major Extremity Trauma Research Consortium (METRC) authors. Outcomes following severe distal tibial, ankle, and/or mid/hindfoot trauma: Comparison of limb salvage and transtibial amputation (OUTLET). *J Bone Joint Surg Am*. 2021 Sep 1;103(17):1588-1597. doi: 10.2106/JBJS.20.01320.
56. Althoff AD, Reeves RA, Traven SA, Slone HS, **Deal DN, Werner BC**. Risk factors for infection following total wrist arthroplasty and arthrodesis: An analysis of 6,641 patients. *Hand (NY)*. 2021 Sep;16(5):657-663. doi: 10.1177/1558944719890036. Epub 2019 Dec 6.
57. Althoff AD, Kamalopathy P, Vatani J, **Hassanzadeh H, Li X**. Osteoporosis is associated with increased minor complications following single level ALIF and PSIF: An analysis of 7,004 patients. *J Spine Surg*. 2021 Sep;7(3):269-276. doi: 10.21037/jss-21-29.
58. Althoff AD, Reeves RA, Traven SA, Slone HS, **Deal DN, Werner BC**. Risk factors for infection following total wrist arthroplasty and arthrodesis: An analysis of 6641 patients. *Hand (NY)*. 2021 Sep;16(5):657-663. doi: 10.1177/1558944719890036. Epub 2019 Dec 6.
59. Althoff AD, Kamalopathy PN, Vatani J, **Hassanzadeh H, Li X**. Osteoporosis is associated with increased minor complications and pulmonary embolism following single level ALIF and PSIF spine stabilization. *J Spine Surg*. 2021 Sep;7(3):267-276. doi: 10.21037/jss-21-29.
60. **Werner BC**, Griffin JW, Lederman E, Gobezie R, Denard PJ. Glenosphere inclination and clinical outcomes after reverse shoulder arthroplasty. *JSESArthro*. 2021 Sep;31(3):430-437. doi: <https://doi.org/10.1053/j.sart.2020.12.014>.
61. Wang KY, Puvanesarajah V, Xu A, Zhang B, Raad M, **Hassanzadeh H**, Keibaish KM. Growing racial disparities in the utilization of adult spinal deformity surgery: An analysis of trends from 2004 to 2014. *Spine*. 2021 Aug 18. doi: 10.1097/BRS.0000000000004180. Online ahead of print.
62. Moran TE, **Freilich AM**. Hand infection. [Updated 2021 Aug 11]. In: StatPearls [Internet]. Treasure

Island (FL): StatPearls Publishing; 2022 Jan-. Available from: <https://www.ncbi.nlm.nih.gov/books/NBK557849>.

63. **Duensing IM**, Stanley S, Bolognesi M. Fracture of a 40-mm BILOX delta femoral head. *Arthroplast Today*. 2021 Aug 5;10:144-148. doi: 10.1016/j.artd.2021.06.021. eCollection 2021 Aug.

64. Bell J, Bhatia M, **Hadeed MM**, George J, Hill A, **Novicoff WM**, Nacey NC, **Shimer AL**. Fluoroscopically guided facet cyst rupture: Rate of conversion to surgery and risk factor analysis. *Clin Spine Surg*. 2021 Aug 1;34(7):E410-E414. doi: 10.1097/BSD.0000000000001146.

65. Cancienne JM, Dempsey IJ, Garrigues GE, Cole BJ, **Brockmeier SF**, **Werner BC**. Trends and impact of three-dimensional preoperative imaging for anatomic total shoulder arthroplasty. *Shoulder & Elbow*. 2021 Aug;13(4):380-387. doi: 10.1177/1758573220908865. Epub 2020 Mar 2.

66. Wright RW, Huston LJ, Haas AK, Pennings JS, Allen CR, Cooper DE, DeBerardino TM, Dunn WR, Lantz BBA, Spindler KP, Stuart MJ, Albright JP, Amendola AN, Andrich JT, Annunziata CC, Arciero RA, Bach BR Jr, Baker CL 3rd, Bartolozzi AR, Baumgarten KM, Bechler JR, Berg JH, Bernas GA, **Brockmeier SF**, Brophy RH, Bush-Joseph CA, Brad Butler V J, Campbell JD, Carey JL, Carpenter JE, Cole BJ, Cooper JM, Cox CL, Creighton RA, Dahm DL, David TS, Flanigan DC, Frederick RW, Ganley TJ, Garofoli EA, Gatt CJ Jr, Gecha SR, Giffin JR, Hame SL, Hannafin JA, Harner CD, Harris NL Jr, Hechtman KS, Hershman EB, Hoellrich RG, Johnson DC, Johnson TS, Jones MH, Kaeding CC, Kamath GV, Klootwyk TE, Levy BA, Ma CB, Maiers GP 2nd, Marx RG, Matava MJ, Mathien GM, McAllister DR, McCarty EC, McCormack RG, Miller BS, Nissen CW, O'Neill DF, Owens BD, Parker RD, Purnell ML, Ramappa AJ, Rauh MA, Rettig AC, Sekiya JK, Shea KG, Sherman OH, Slaughterbeck JR, Smith MV, Spang JT, Svoboda LSJ, Taft TN, Tenuta JJ, Tingstad EM, Vidal AF,

Viskontas DG, White RA, Williams JS Jr, Wolcott ML, Wolf BR, York JJ; MARS Group. Association between graft choice and 6-year outcomes of revision anterior cruciate ligament reconstruction in the MARS cohort. *Am J Sports Med*. 2021 Aug;49(10):2589-2598. doi: 10.1177/03635465211027170. Epub 2021 Jul 14.

67. Kamalopathy P, Hines J, **Cui Q**. Navigation assisted total knee arthroplasty in 54,114 patients: No increased risk in acute complications and hospital utilization. *Int J Med Robot*. 2021 Aug; 17(4):e2256. doi: 10.1002/rcs.2256. Epub 2021 Apr 12.

68. Kamalopathy P, Kurker KP, Althoff AD, **Browne JA**, **Werner BC**. The impact of mental illness on postoperative adverse outcomes after outpatient joint surgery. *J Arthroplasty*. 2021 Aug;36(8):P2734-2741. doi: 10.1016/j.arth.2021.04.002. Epub 2021 Apr 20.

69. Kamalopathy PN, **Hassanzadeh H**, et al. Safety profile of outpatient vs. inpatient ACFD: An analysis of 33,807 outpatient ACFDs. *Clin Neurol Neurosurg*. 2021 Aug;207:106743. doi: 10.1016/j.clineuro.2021.106743. Epub 2021 Jun 8.

70. Huang Z, Li T, Lin N, **Cui Q**, Chen W. Evaluation of radiographic outcomes after core decompression for osteonecrosis of the femoral head: The Beijing University of Chinese Medicine X-ray evaluation method. *J Bone Joint Surg Am*. 2021 Jul 28. doi: 10.2106/JBJS.20.00478. Online ahead of print.

71. Roecker Z, Kamalopathy P, **Werner BC**. Male sex, cartilage surgery, tobacco use, and opioid disorders are associated with an increased risk of infection after ACL reconstruction. *Arthroscopy*. 2021 Jul 28. doi: <https://doi.org/10.1016/j.arthro.2021.07.025>.

72. Lesevic M, Awowale J, Moran TE, **Diduch DR**, **Brockmeier SF**, **Werner BC**. Immediate pain relief at time of corticosteroid injection for idiopathic adhesive capsulitis is not predictive of eventual outcome. *Orthop J Sports Med*. 2021

Jul;9(7):23259671211019353. doi: 10.1177/23259671211019353. Published online 2021 Jul 13.

73. Yildirim B, Bustos FP, Dibbern ME, **Dacus AR**. Traumatic osteonecrosis of the distal ulna. *J Hand Surg Am*. 2021 Jul 12:S0363-5023(21)00332-4. doi: 10.1016/j.jhssa.2021.05.019. Online ahead of print.

74. Ignozzy AJ, Anderson G, **Diduch DR**. Repair of a complete radial tear of the lateral meniscus. *VSM*. 2021 Jul 5. doi:10.1177/26350254211014208.

75. Chen DQ, Quinlan ND, **Browne JA**, **Werner BC**. Increased Reimbursement for Surgical Fixation of Hip Fractures: The Difference Between the Hospital and the Surgeon. *J Orthop Trauma*. 2021 Jul 1;35(7):P339-344. doi: 10.1097/BOT.0000000000002092.

76. Lesevic M, Awowale JT, Moran TE, **Diduch DR**, **Brockmeier SF**, **Werner BC**. Immediate pain relief at time of corticosteroid injection for idiopathic adhesive capsulitis as a predictor of eventual outcomes. *Orthop J Sports Med*. 2021 Jul;9(7):23259671211019353. doi: 10.1177/23259671211019353. eCollection 2021 Jul.

77. Krueger CA, Backstein DJ, **Browne JA**, Krebs VE, Mason JB, Mont MA, Taunton MJ, Callaghan JJ. Real time conversations: Changes to the letters to the editor. *J Arthroplasty*. 2021 Jul;36(7):2249. doi: 10.1016/j.arth.2021.05.011.

78. **Bachmann KR**. Spinal Deformities in the Adolescent Athlete. *Clin Sports Med*. 2021 Jul;40(3):541-554. doi: 10.1016/j.csm.2021.03.007.

79. Patel A, Pahys JM, Samdani AF, Newton PO, Bastrom TP, Shah SA, Miyajni F, Hwang SW; Harms Study Group. Early and late hospital readmissions in adolescent idiopathic scoliosis. *Spine Deform*. 2021 Jul;9(4):1041-1048. doi: 10.1007/s43390-021-00294-7. Epub 2021 May 3.

80. **Miller MD**. Sports medicine is not spineless! *Clin Sports Med*. 2021 Jul;40(3):ix. doi: 10.1016/j.csm.2021.04.005.

81. **Shimer AL**, **Shen FH**. Not just shoulders and knees: An athlete has a spine too! *Clin Sports Med*. 2021 Jul;40(3):xi-xii. doi: 10.1016/j.csm.2021.04.004.

82. Chung CC, **Shimer AL**. Lumbosacral spondylolysis and spondylolisthesis. *Clin Sports Med*. 2021 Jul;40(3): 471-490. doi: 10.1016/j.csm.2021.03.004.

83. **Browne JA**. Leveraging early discharge and telehealth technology to safely conserve resources and minimize personal contact during COVID-19 in an arthroplasty practice. *J Arthroplasty*. 2021 Jul;36(7S):S52-S55. doi: 10.1016/j.arth.21021.01.009. Epub 2021 Jan 11.

84. Quinlan ND, Althoff AD, Chen DQ, **Werner BC**, **Brown TE**, **Browne JA**. Trends in hospital and surgeon charges and reimbursements for revision total knee arthroplasty. *J Arthroplasty*. 2021 Jul;36(7S):S145-S154. doi: 10.1016/j.arth.2021.01.078. Epub 2021 Feb 5.

85. Haug EC, Quinlan ND, Pottanat PJ, Chen DQ, **Browne JA**, **Werner BC**. Reimbursements for revision total hip arthroplasty have increased for hospitals but not for surgeons. *J Arthroplasty*. 2021 Jul;36(7S):S160-S167. doi: 10.1016/j.arth.2021.02.034. Epub 2021 Feb 16.

86. Quinlan ND, **Werner BC**, **Browne JA**. Prior nonarthroplasty surgery increases risk of complication in primary total knee arthroplasty. *J Arthroplasty*. 2021 Jul;36(7):2445-2451.e1. doi: 10.1016/j.arth.2021.02.055. Epub 2021 Mar 1.

87. Bodkin S, Hertel J, **Diduch DR**, Saliba S, **Novicoff W**, **Brockmeier S**, **Miller M**, **Gwathmey FW**, **Werner B**, **Hart J**. Predicting ACL reinjury from return to activity assessments at 6-months post-surgery: A prospective cohort study. *J Athl Train*. 2021 Jun 15. doi:10.4085/1062-6050-0407.20. Online ahead of print.

88. Moran J, Porrino J, Cheng R, Schneble CA, Kahan JB, Molho DA, Katz L, **Miller MD**, Medvecky MJ. An imaging overview of the posterior septum of the knee and trans-septal portal procedure: Normal anatomy, indications, and unique imaging considerations. *Curr Probl Diagn Radiol*. 2021 Jun 11;S0363-0188(21)00096-7. doi: 10.1067/j.cpradiol.2021.04.001. Epub ahead of print.
89. LaPrade MD, Camp CL, Krych AJ, **Werner BC**. Analysis of charges and payments for outpatient arthroscopic meniscectomy from 2005 to 2014: Hospital reimbursement increased steadily as surgeon payments declined. *Orthop J Sports Med*. 2021 Jun 8;9(6):23259671211010482. doi: 10.1177/23259671211010482. eCollection 2021 Jun.
90. Cancienne JM, Denard PJ, Garrigues GE, **Werner BC**. The relationship of staged, bilateral arthroscopic primary rotator cuff repair timing and postoperative complications. *Am J Sports Med*. 2021 Jun 3;49(8):2027-2034. doi:10.1177/03635465211015198
91. Deasey M, Lesevic M, **Diduch D**. Osteochondritis dissecans and avascular necrosis. In: Wiesel S, ed. *Operative Techniques in Orthopaedic Surgery*. 3rd edition. Wolters Kluwer, Philadelphia; 2021 Jun 2.
92. Rush J, Deasey M, Lesevic M, DeJour D, **Diduch D**. Trochleoplasty. In: Wiesel S, ed. *Operative Techniques in Orthopaedic Surgery*. 3rd edition. Wolters Kluwer, Philadelphia; 2021 Jun 2.
93. Bradford PS, **Dacus AR**, **Chhabra AB**, Butler PD, **DeGeorge BR Jr**. How to be an antiracist hand surgery educator. *J Hand Surg Am*. 2021 Jun;46(6):507-511. doi: 10.1016/j.jhsa.2021.01.017. Epub 2021 Mar 21.
94. Aryee JNA, **Akinleye SD**, **Freilich AM**, **Deal DN**. Mycobacterium immunogenum flexor tenosynovitis: A case report. *J Wrist Surg*. 2021 Jun;10(3):241-244. doi: 10.1055/s-0040-1715803. Epub 2020 Aug 31.
95. Godin JA, Clinic S, Richter DL, **Werner BC**, Clements JR, **Cooper MT**. Osteochondral lesions: What's new from our sports medicine colleagues? *Foot Ankle Spec*. 2021 Jun;14(3):249-254. doi: 0.1177/19386400211023702.
96. Lee W, **Cooper MT**, **Perumal V**, Tran S, **Park JS**. Does the length of the plate affect the failure rate of hallux MTP joint arthrodesis for severe hallux valgus? *The Foot*. 2021 Jun;47:101773. doi: 10.1016/j.foot.2020.101773. Epub 2021 Jan 2.
97. Krueger CA, Mont MA, Backstein DJ, **Browne JA**, Krebs VE, Mason JB, Taunton MJ, Callaghan JJ. The problem with fragile results. *J Arthroplasty*. 2021 Jun;36(6):1847-1848. doi: 10.1016/j.arth.2021.04.018.
98. Kamalpathy P, Rush J, Montgomery SR, **Diduch DR**, **Werner BC**. A national perspective of patellar instability in children and adolescents in the United States: MPFL reconstruction is three times higher than the incidence of isolated lateral release. *Arthroscopy*. 2021 Jun. doi: 10.1016/j.arthro.2021.05.061.
99. Jung T, Kim Y, Kelly LE, Wagatsuma M, Jung Y, **Abel MF**. Comparison of treadmill and over-ground walking with children and adolescents. *Percept Mot Skills*. 2021 Jun;128(3):988-1001. doi: 10.1177/0031512521993102. Epub 2021 Feb 10.
100. Buyukdogan K, Laidlaw MS, Kew ME, **Miller MD**. Allograft bone dowels show better incorporation in femoral versus tibial tunnels in 2-stage revision anterior cruciate ligament reconstruction: A computed tomography-based analysis. *Arthroscopy*. 2021 Jun;37(6):1920-1928. doi: 10.1016/j.arthro.2021.01.066. Epub 2021 Feb 10.
101. Bradford PS, **Dacus AR**, **Chhabra AB**, Butler PD, **DeGeorge BR**. How to be an antiracist hand surgeon Educator. *J Hand Surg Am*. 2021 Jun;46(6):507-511. doi: 10.1016/j.jhsa.2021.01.017. Epub 2021 Mar 21.
102. Hines JT, Jo WL, **Cui Q**, Mont MA, Koo KH, Cheng EY, Goodman SB, Ha YC, Hernigou P, Jones LC, Kim SY, Sakai T, Sugano N, Yamamoto T, Lee MS, Zhao D, Drescher W, Kim TY, Lee YK, Yoon BH, Baek SH, Ando W, Kim HS, Park JW. Osteonecrosis of the femoral head: An updated review of ARCO on pathogenesis, staging and treatment. *J Korean Med Sci*. 2021 Jun 21;36(24):e177. doi: 10.3346/jkms.2021.36.e177.
103. **Shen FH**, Woods D, **Miller M**, Murrell B, Vadapalli S. Use of the dual construct lowers rod strains in the flexion-extension and lateral bending compared to two-rod and two-rod satellite constructs in a cadaveric spine corpectomy model. *Spine J*. 2021 May 29;S1529-9430(21)00286-2. doi: 10.1016/j.spinee.2021.05.022. Online ahead of print.
104. Cheng EY, **Cui Q**, Goodman SB, Ando W, Baek SH, Bakker C, Drescher W, Hernigou P, Jones LC, Kim H, Kim SY, Kim TY, Ha YC, Koo KH, Lee MS, Mont MA, Reichert I, Sakai T, Salem HS, Sierra RJ, Stronach B, Sugano N, Yamamoto T, Yoon BH, Zhao D. Diagnosis and treatment of femoral head osteonecrosis: A protocol for development of evidence-based clinical practice guidelines. *Surg Technol Int*. 2021 May 27;38:sti38/1437. doi: 10.52198/21.STI.38. OS1437. Epub ahead of print.
105. Yang X, Ignozzi AJ, He R, Zhu D, Wang X, Chordia MD, Pan D, **Cui Q**. Detection of osteoarthritis inflammation by single-photon emission computed tomography based on an inflammation-targeting peptide cFLFLF. *Mol Imaging Biol*. 2021 May 24. doi: 10.1007/s11307-021-01616-x. Online ahead of print.
106. Ignozzi AJ, Hyde Z, Dart SE, **Diduch DR**. Sulcus-deepening trochleoplasty for trochlear dysplasia. *VJSM*. 2021 May 18;1(3). doi: 10.1177/26350254211011184.
107. Kamalpathy PN, Du Plessis MI, Chen D, Bell J, **Park JS**, **Werner BC**. Obesity and postoperative complications following ankle arthrodesis: A propensity score matched analysis. *J Foot Ankle Surg*. 2021 May 17;S1067-2516(21)00173-3. doi: 10.1053/j.jfas.2021.05.004. Online ahead of print.
108. O'Toole RV, Joshi M, Carlini AR, Murray CK, Allen LE, Huang Y, Scharfstein DO, O'Hara NN, Gary JL, Bosse MJ, Castillo RC, Bishop JA, Weaver MJ, Firoozabadi R, Hsu JR, Karunakar MA, Seymour RB, Sims SH, Churchill C, Brennan ML, Gonzales G, Reilly RM, Zura RD, Howes CR, Mir HR, Wagstrom EA, Westberg J, Gaski GE, Kempton LB, Natoli RM, Sorkin AT, Virkus WW, Hill LC, Hymes RA, Holzman M, Malekzadeh AS, Schulman JE, Ramsey L, Cuff JAN, Haaser S, Osgood GM, Shafiq B, Laljani V, Lee OC, Krause PC, Rowe CJ, Hilliard CL, Morandi MM, Mullins A, Achor TS, Choo AM, Munz JW, Boutte SJ, Vallier HA, Breslin MA, Frisch HM, Kaufman AM, Large TM, LeCroy CM, Riggsbee C, Smith CS, Crickard CV, Phieffer LS, Sheridan E, Jones CB, Sietsema DL, Reid JS, Ringenbach K, Hayda R, Evans AR, Crisco MJ, Rivera JC, Osborn PM, Kimmel J, Stawicki SP, Nwachuku CO, Wojda TR, Rehman S, Donnelly JM, Caroom C, Jenkins MD, Boulton CL, Costales TG, LeBrun CT, Manson TT, Mascarenhas DC, Nascone JW, Pollak AN, Sciadini MF, Slobogean GW, Berger PZ, Connelly DW, Degani Y, Howe AL, Marinos DP, Montalvo RN, Reahl GB, Schoonover CD, Schroder LK, Vang S, Bergin PF, Graves ML, Russell GV, Spittle CA, Hydrick JM, Teague D, Ertl W, Hickerson LE, Moloney GB, Weinlein JC, Zelle BA, Agarwal A, Karia RA, Sathy AK, Au B, Maroto M, Sanders D, Higgins TF, Haller JM, Rothberg DL, **Weiss DB**, **Yarboro SR**, McVey ED, Lester-Ballard V, Goodspeed D, Lang GJ, Whiting PS, Siy AB, Obremskey WT, Jahangir AA, Attum B, Burgos EJ, Molina CS, Rodriguez-Buitrago A, Gajari V, Trochez KM, Halvorson JJ, Miller AN, Goodman JB, Holden MB, McAndrew CM, Gardner MJ, Ricci WM, Spraggus-Hughes A, Collins SC, Taylor TJ, Zadnik M; Major Extremity Trauma Research Consortium (METRC). Effect of Intrawound Vancomycin Powder in Operatively Treated High-risk Tibia Fractures: A Randomized Clinical Trial. *JAMA Surg*. 2021 May 1;156(5):e207259. doi: 10.1001/jamasurg.2020.7259. Epub 2021 May 12.
109. Burke JF, Anciano V, **Novicoff WM**, **Yarboro SR**. Use of standardized language for C-arm fluoroscopy improves intraoperative communication and efficiency.

J Am Acad Orthop Surg. 2021 May 1;29(9):e458-e464. doi: 10.5435/JAAOS-D-20-00314.

110. Bedard NA, Carender CN, DeMik DE, **Browne JA**, Schwarzkopf R, Callaghan JJ. The impact of transitioning from international classification of diseases, ninth revision to international classification of diseases, tenth revision on reported complication rates following primary total knee arthroplasty. *J Arthroplasty.* 2021 May;36(5):1617-1620. doi: 10.1016/j.arth.2020.12.009. Epub 2020 Dec 13.

111. Lewis DC, Athoff AD, Kamalopathy P, **Yarboro SR, Miller MD**, Werner BC. Risk factors for infection and revision surgery following patellar tendon and quadriceps tendon repairs: An analysis of 3,442 Patients. *J Knee Surg.* 2021 Apr 14. doi: 10.1055/s-0041-1727113. Epub ahead of print.

112. Büyükdogan K, Laidlaw MS, Fox MA, Kew ME, **Miller MD**. Effect of tibial tunnel placement using the lateral meniscus as a landmark on clinical outcomes of anatomic single-bundle anterior cruciate ligament reconstruction. *Am J Sports Med.* 2021 Apr 8;363546521999672. doi: 10.1177/0363546521999672.

113. **Miller MD**. Editorial commentary: Anterior cruciate ligament tunnel aperture overlap determines need for 1- versus 2-stage revision: Setting the stage. *Arthroscopy.* 2021 Apr;37(4):1233-1234. doi: 10.1016/j.arthro.2021.01.033.

114. **Miller MD**. Hip, hip, hurrah! *Clin Sports Med.* 2021 Apr;40(2):xiii. doi: 10.1016/j.csm.2021.02.001. Epub 2021 Feb 10.

115. Aryee JNA, Bolarinwa SA, Montgomery SR Jr, **Novicoff W, Dacus AR**. Race, gender, and residency: A survey of trainee experience. *J Natl Med Assoc.* 2021 Apr;113(2):199-207. doi: 10.1016/j.jnma.2020.09.001. Epub 2020 Sep 24.

116. Richter DL, **Gwathmey FW**. Hip pain in the athlete: The source is key. *Clin Sports Med.* 2021 Apr;40(2):xv-xvi. doi:

10.1016/j.csm.2021.01.004. Epub 2021 Feb 5.

117. Quinlan ND, **Werner BC, Novicoff WM, Browne JA**. Are patients more susceptible to viral illness immediately following hip and knee arthroplasty? An analysis of influenza diagnoses using multiple administrative databases. *J Arthroplasty.* 2021 Apr;36(4):1251-1256.e5. doi: 10.1016/j.arth.2020.10/045. Epub 2020 Oct 28.

118. **Browne JA**, NandyMazumdar M, Paranjapye A, Leir SH, Harris A. The Bromodomain Containing 8 (BRD8) transcriptional network in human lung epithelial cells. *Mol Cell Endocrinol.* 2021 Mar 15;524:111169. doi: 10.1016/j.mce.2021.111169. Epub 2021 Jan 19.

119. **Cui Q**, Jo WL, Koo KH, Cheng EY, Drescher W, Goodman SB, Ha YC, Hernigou P, Jones LC, Kim SY, Lee KS, Lee MS, Lee YJ, Mont MA, Sugano N, Taliaferro J, Yamamoto T, Zhao D. ARCO consensus on the pathogenesis of non-traumatic osteonecrosis of the femoral head. *J Korean Med Sci.* 2021 Mar 15;36(10):e65. doi: 10.3346/jkms.2021.36.e65.

120. Kurzweil P, Krych AJ, Anz A, **Gwathmey FW**, Loren G, Lavery M, Flanigan DC. Favorable reoperation rate at 2 years following repair of horizontal cleavage tears using an all suture-based technique: A prospective, multicenter trial. *Arthrosc Sports Med Rehabil.* 2021 Mar 13;3(3):e773-e780. doi: 10.1016/j.asmr.2021.01.018. eCollection 2021 Jun.

121. Krueger CA, Mont MA, Backstein DJ, **Browne JA**, Krebs VE, Mason JB, Taunton MJ, Callaghan JJ. COVID will end but telemedicine may be here to stay. *J Arthroplasty.* 2021 Mar;36(3):789-790. doi: 10.1016/j.arth.2021.01.034.

122. Verhofste BP, Berry JG, Miller PE, Crofton CN, Garrity BM, Fletcher ND, Marks MC, Shah SA, Newton PO, Samdani AF, **Abel MF**, Sponseller PD; Harms Study Group, Glotzbecker MP. Risk factors for gastrointestinal complications after spinal fusion in children with cerebral palsy. *Spine Deform.* 2021 Mar;9(2):567-578. doi:

10.1007/s43390-020-00233-y. Epub 2020 Nov 17.

123. Feger MA, Donovan L, Herb CC, **Hart JM**, Saliba SA, **Abel MF**, Hertel J. Effects of 4-week impairment-based rehabilitation on jump-landing biomechanics in chronic ankle instability patients. *Phys Ther Sport.* 2021 Mar;48:201-208. doi: 10.1016/j.ptsp.2020.07.005. Epub 2020 Jul 25.

124. Walters JD, Ignozzi A, Bustos F, **Werner BC, Brockmeier SF**. Better radiographic reduction and lower complication rates with combined coracoclavicular and acromioclavicular ligament reconstruction than with isolated coracoclavicular reconstruction. *Arthrosc Sports Med Rehabil.* 2021 Feb;3(2):e441-e448. doi: 10.1016/j.asmr.2020.10.009. eCollection 2021 Apr.

125. Smith JM, Cancienne JM, **Brockmeier SF, Werner BC**. Vitamin D deficiency and total shoulder arthroplasty complications. *Shoulder & Elbow.* 2021 Feb;13(1):99-105. doi: 10.1177/1758573220906520. Epub 2020 Mar 29.

126. Brophy RH, Wright RW, Huston LJ, Haas AK, Allen CR, Anderson AF, Cooper DE, DeBerardino TM, Dunn WR, Lantz BBA, Mann B, Spindler KP, Stuart MJ, Albright JP, Amendola AN, Andrish JT, Annunziata CC, Arciero RA, Bach BR, Baker CL, Bartolozzi AR, Baumgarten KM, Bechler JR, Berg JH, Bernas GA, **Brockmeier SF**, Bush-Joseph CA, Butler JBV, Campbell JD, Carey JL, Carpenter JE, Cole BJ, Cooper JM, Cox CL, Alexander Creighton R, Dahm DL, David TS, Flanigan DC, Frederick RW, Ganley TJ, Garofoli EA, Gatt CJ, Gecha SR, Giffin JR, Hame SL, Hannafin JA, Harner CD, Harris NL, Hechtman KS, Hershman EB, Hoellrich RG, Hosea TM, Johnson DC, Johnson TS, Jones MH, Kaeding CC, Kamath GV, Klootwyk TE, Levy BA, Benjamin Ma C, Peter Maiers G, Marx RG, Matava MJ, Mathien GM, McAllister DR, McCarty EC, McCormack RG, Miller BS, Nissen CW, O'Neill DF, Owens BD, Parker RD, Purnell ML, Ramappa AJ, Rauh MA, Rettig AC, Sekiya JK, Shea KG, Sherman OH, Li X, Slauterbeck JR, Smith MV, Spang JT,

Svoboda LSJ, Taft TN, Tenuta JJ, Tingstad EM, Vidal AF, Viskontas DG, White RA, Williams JS, Wolcott ML, Wolf BR, York JJ; MARS Group. Rate of infection following revision anterior cruciate ligament reconstruction and associated patient- and surgeon-dependent risk factors: Retrospective results from MOON and MARS data collected from 2002 to 2011. *J Orthop Res.* 2021 Feb;39(2):274-280. doi: 10.1002/jor.24871. Epub 2020 Oct 19.

127. Walters JD, Denard PJ, **Brockmeier SF, Werner BC**. The relationship of bilateral shoulder arthroplasty timing and postoperative complications. *J Shoulder Elbow Surg.* 2021 Feb;30(2):317-323. doi: 10.1016/j.jse.2020.06.010. Epub 2020 Jul 2.

128. Mont MA, Backstein DJ, **Browne JA**, Krebs VE, Krueger CA, Mason JB, Taunton MJ, Callaghan JJ. The second surge of COVID-19: Better prepared and a brighter light at the end of the tunnel. *J Arthroplasty.* 2021 Feb;36(2):395-396. doi: 10.1016/j.arth.2020.12.020.

129. Casp A, Bodkin S, Kew M, Noona S, Lesevic M, **Hart JM, Diduch DR**. Quadriceps strength is influenced by skeletal maturity in adolescents recovering from anterior cruciate ligament reconstruction. *J Pediatr Orthop.* 2021 Feb;41(2):e141-e146; doi: 10.1097/BPO.0000000000001706.

130. Gaily CD, Wang EJ, Jin L, Ahmadi S, Brautigam DL, **Li X**, Xu W, Scott MM, Fu Z. Phosphosite T674A mutation in kinesin family member 3A fails to reproduce tissue and ciliary defects characteristic of CILK1 loss of function. *Dev Dyn.* 2021 Feb; 250(2):263-273. doi: 10.1002/dvdy.252. Epub 2020 Oct 7.

131. Büyükdogan K, Laidlaw MS, Kew ME, **Miller MD**. Allograft bone dowels show better incorporation in femoral vs. tibial tunnels in 2-stage revision anterior cruciate ligament reconstruction: A computed tomography-based analysis. *Arthroscopy.* 2021 Feb 10;S0749-8063(21)00130-4. doi: 10.1016/j.arthro.2021.01.066.

132. Thiele RH, Sarosiek BM, Modesitt SC, McMurry TL, Tiouririne M, Martin LW, Blank RS, Shilling A, **Browne JA**, Bogdonoff DL, Bauer TW, Hedrick TL. Development and impact of an institutional enhanced recovery program on opioid use, length of stay, and hospital costs within an academic medical center: A cohort analysis of 7774 patients. *Anesth Analg*. 2021 Feb 1;132(2):442-455. doi: 10.1213/ANE.0000000000005182.
133. **Hadeed MM**, Prakash H, **Yarboro SR**, **Weiss DB**. Intramedullary nailing of extra-articular distal tibial fractures. *Bone Joint J*. 2021 Feb;103-B(2):294-298. doi: 10.1302/0301-620X.103B2.BJJ-2020-0404.R2.
134. **Werner BC**, Denard PJ, Tokish JM, Bedi A, Donegan RP, Metcalfe N, Dines JS. The addition of preoperative three-dimensional analysis alters implant choice in shoulder arthroplasty. *Shoulder & Elbow*. 2021 Feb. doi:10.1177/1758573221989306.
135. Bodkin SG, Bruce AS, Hertel J, **Diduch DR**, Saliba SA, **Novicoff WM**, **Hart JM**. Visuomotor therapy modulates corticospinal excitability in patients following anterior cruciate ligament reconstruction: A randomized crossover trial. *Clin Biomech* (Bristol, Avon). 2021 Jan;81:105238. doi: 10.1016/j.clinbiomech.2020.105238. Epub 2020 Nov 20.
136. Bodkin SG, Hertel J, Bruce AS, **Diduch DR**, Saliba SA, **Novicoff WM**, **Hart JM**. Patient function in serial assessments throughout the post-ACL reconstruction progression. *Phys Ther Sport*. 2021 Jan;47(1):85-90. doi: 10.1016/j.ptsp.2020.11.025. Epub 2020 Nov 11.
137. **Miller MD**. Sport-related concussion: Heads up! *Clin Sports Med*. 2021 Jan;40(1):xiii. doi: 10.1016/j.csm.2020.10.001.
138. Moran TE, Demers AJ, Shank KM, Awowale JT, **Miller MD**. Percutaneous medial collateral ligament release improves medial compartment access during knee arthroscopy. *Arthrosc Sports Med Rehabil*. 2020 Dec 27;3(1):e105-e114. doi: 10.1016/j.asmr.2020.08.014.
139. Yaszay B, Bartley CE, Sponseller PD, **Abel M**, Cahill PJ, Shah SA, Miyanji F, Samdani AF, Daquino C, Newton PO. Major complications following surgical correction of spine deformity in 257 patients with cerebral palsy. *Spine Deform*. 2020 Dec;8(6):1305-1312. doi: 10.1007/s43390-020-00165-7. Epub 2020 Jul 27.
140. Taleghani ER, Thompson SR, **Yarboro SR**, Schaller TM, **Miller MD**. Treatment algorithm for surgical site infections following extensor mechanism repair. *JBJS Rev*. 2020 Dec 18;8(12):e20.00078. doi: 10.2106/JBJS.RVW.20.00078.
141. Cancienne JM, Browning R, Haug E, **Browne JA**, **Werner BC**. Certificate-of-need programs are associated with a reduced incidence, expenditure, and rate of complications with respect to knee arthroscopy in the Medicare population. *HSS J*. 2020 Dec;16(-Suppl 2):264-271. doi: 10.1007/s11420-019-09693-z. Epub 2019 Jul 29.
142. Quinlan ND, **Werner BC**, **Brown TE**, **Browne JA**. Risk of prosthetic joint infection increases following early aseptic revision surgery of total hip and knee arthroplasty. *J Arthroplasty*. 2020 Dec;35(12):3661-3667. doi: 10.1016/j.arth.2020.06.089. Epub 2020 Jul 3.
143. Wiater JM, Levy JC, Wright SA, **Brockmeier SF**, Duquin TR, Wright JO, Codd TP. Prospective, blinded, randomized controlled trial of stemless versus stemmed humeral components in anatomic total shoulder arthroplasty: Results at short-term follow-up. *J Bone Joint Surg Am*. 2020 Nov;102(22):1974-1984. doi: 10.2106/JBJS.19.01478.
144. Althoff AD, Prakash H, Gean RP, **Yarboro SR**. Small fragment instrumentation for periprosthetic humerus. *Tech Shoulder Elb Surg*. 2020 Nov;21(4):132-135. doi: 10.1097/bte.0000000000000200
145. Quinlan ND, Hogarth DA, Chen DQ, **Werner BC**, **Brown JA**. Hospital and surgeon reimbursement trends for femoral neck fractures treated with hip hemiarthroplasty and total hip arthroplasty. *J Arthroplasty*. 2020 Nov;35(11):3067-3075. doi: 10.1016/j.arth.2020.05.059. Epub 2020 May 28.
146. Moran TE, Burke JF, **Diduch DR**. Small (3.2mm), short, oblique patellar tunnels for patellar fixation in MPFL reconstruction. *Arthroscopy Techniques*. 2020 Oct 2;9(10):e1613-e1617. doi: 10.1016/j.eats.2020.07.001. eCollection 2020 Oct.
147. Deasey M, Moran T, Lesevic M, Burnett Z, **Diduch DR**. Small (3.2 mm), short, oblique patellar tunnels for patellar fixation do not increase fracture risk or complications in MPFL reconstruction: A retrospective cohort study. *Orth J Sports Med*. 2020 Oct 1;8(10):2325967120954430. doi: 10.1177/2325967120954430. eCollection 2020 Oct.
148. Wright RW, Huston LJ, Haas AK, Nwosu SK, Allen CR, Anderson AF, Cooper DE, DeBerardino TM, Dunn WR, Lantz BBA, Mann B, Spindler KP, Stuart MJ, Penning JS, Albright JP, Amendola AN, Andrish JT, Annunziata CC, Arciero RA, Bach BR Jr, Baker CL 3rd, Bartolozzi AR, Baumgarten KM, Bechler JR, Berg JH, Bernas GA, **Brockmeier SF**, Brophy RH, Bush-Joseph CA, Butler V JB, Campbell JD, Carey JL, Carpenter JE, Cole BJ, Cooper JM, Cox CL, Creighton RA, Dahm DL, David TS, Flanigan DC, Frederick RW, Ganley TJ, Garofoli EA, Gatt CJ Jr, Gecha SR, Giffin JR, Hame SL, Hannafin JA, Harner CD, Harris NL Jr, Hechtman KS, Hershman EB, Hoellrich RG, Hosea TM, Johnson DC, Johnson TS, Jones MH, Kaeding CC, Kamath GV, Klootwyk TE, Levy BA, Ma CB, Maiers GP 2nd, Marx RG, Matava MJ, Mathien GM, McAllister DR, McCarty EC, McCormack RG, Miller BS, Nissen CW, O'Neill DF, Owens BD, Parker RD, Purnell ML, Ramappa AJ, Rauh MA, Rettig AC, Sekiya JK, Shea KG, Sherman OH, Slaughterbeck JR, Smith MV, Spang JT, Steven J Svoboda L, Taft TN, Tenuta JJ, Tingstad EM, Vidal AF, Viskontas DG, White RA, Williams JS Jr, Wolcott ML, Wolf BR, York JJ; MARS Group. Meniscal repair in the setting of revision anterior cruciate ligament reconstruction: Results from the MARS cohort. *Am J Sports Med*. 2020 Oct;48(12):2978-2985. doi: 10.1177/0363546520948850. Epub 2020 Aug 21.
149. Casp AJ, Sequeira S, Kew ME, **Brockmeier SF**, **Werner BC**. Red cell distribution width as a novel predictor of mortality and complications after primary shoulder arthroplasty. *J Am Acad Orthop Surg*. 2020 Oct;28(19):802-807. doi: 10.5435/JAAOS-D-19-00499.
150. **Cooper MT**. The role of deltoid repair and arthroscopy in ankle fractures. *Clin Sports Med*. 2020 Oct;39(4):733-743. doi: 10.1016/j.csm.2020.06.003. Epub 2020 Aug 13.
151. Baldwin KD, Cahill PJ, Sponseller PD, **Abel MF**, Spiegel DA, Flynn JM, Pahys JM; Harms Study Group. BMI change following spinal fusion for neuromuscular scoliosis surgery. *Spine Deform*. 2020 Oct;8(5):1081-1087. doi: 10.1007/s43390-020-00109-1. Epub 2020 May 11.
152. **Miller MD**. Best foot foreword. *Clin Sports Med*. 2020 Oct;39(4):xiii-xiv. doi: 10.1016/j.csm.2020.07.009. Epub 2020 Aug 14.
153. Brown A, Lebovic J, Alas H, Pierce KE, Bortz CA, Ahmad W, Naessig S, **Hassanzadeh H**, Labaran L, Puvanesarajah V, Vasquez-Montes D, Wang E, Raman T, Diebo BG, Vira S, Protopsaltis T, Lafage V, Lafage R, Buckland A, Gerling M, Passias PG. A cost utility analysis of treating different adult spinal deformity frailty states. *J Clin Neurosci*. 2020 Oct;80:223-228. doi: 10.1016/j.jocn.2020.07.047. Epub 2020 Aug 27.
154. Testa A, Rennó Santos M, **Weiss DB**. Incarceration rates and hospital beds per capita: A cross-national study of 36 countries, 1971-2015. *Soc Sci Med*. 2020 Oct;263:113262. doi: 10.1016/j.socscimed.2020.113262. Epub 2020 Aug 3.
155. Kadakia AR, **Park JS**. Preface. *Clin Sports Med*. 2020 Oct;39(4):xv-xvi. doi: 10.1016/j.

csm.2020.07.008. Epub 2020 Aug 14.

156. **Park JS**, Casale MJ. Posterior tibial tendon transfer for common peroneal nerve injury. *Clin Sports Med*. 2020 Oct;39(4):819-828. doi: 10.1016/j.csm.2020.07.003. Epub 2020 Aug 14.

157. Cross KM, McMurray M, Hertel J, Magrum E, Templeton R, **Brockmeier S**, **Gwathmey F**. Shoulder and elbow injury rates and characteristics among collegiate baseball student-athletes. *Int J Sports Phys Ther*. 2020 Oct;15(5):792-803. doi: 10.26603/ijsp20200792.

158. Hannon CP, Fillingham YA, **Browne JA**, Schemitsch EH, AAHKS Anesthesia & Analgesia Clinical Practice Guideline Workgroup, Buvanendran A, Hamilton WG, Della Valle CJ. Gabapentinoids in total joint arthroplasty: The clinical practice guidelines of the American Association of Hip and Knee Surgeons, American Society of Regional Anesthesia and Pain Medicine, American Academy of Orthopaedic Surgeons, Hip Society, and Knee Society. *J Arthroplasty*. 2020 Oct;35(10):2700-2703. doi: 10.1016/j.arth.2020.05.031. Epub 2020 May 26.

159. Hannon CP, Fillingham YA, **Browne JA**, Schemitsch EH, Mullen K, Casambre F, Visvabharathy V, Hamilton WG, Della Valle CJ. The efficacy and safety of gabapentinoids in total joint arthroplasty: Systematic review and direct meta-analysis. *J Arthroplasty*. 2020 Oct;35(10):2730-2738.e6. doi: 10.1016/j.arth.2020.05.033. Epub 2020 May 26.

160. Bell JE, Sequeira SB, Chen DQ, Haug EC, **Werner BC**, **Browne JA**. Preoperative pain management: Is tramadol a safe alternative to traditional opioids before total hip arthroplasty? *J Arthroplasty*. 2020 Oct;35(10):2886-2891. doi: 10.1016/j.arth.2020.04.093. Epub 2020 May 7.

161. **Hadeed MM**, Fashandi A, **Yarboro SR**. Anteroposterior (AP) view of the knee does not

reliably replace the lateral view during evaluation of femoral torsion. *Current Orthopaedic Practice*. 2020 Sep 25;31(6):561-564. doi: 10.1097/BCO.0000000000000928.

162. Kent JB, Jin L, **Li XJ**. Quantifying biofield therapy through biophoton emission in a cellular model. *J Sci Explor*. 2020 Fall; 34(3):434-454. doi: 10.31275/20201691. Epub 2020 Sep 15.

163. Mortensen AJ, **Duensing I**, Aoki S. Arthroscopic femoral osteochondroplasty for cam-type femoroacetabular impingement: Cortical-cancellous sclerotic boundary guides resection depth. *Arthrosc Tech*. 2020 Sep 4;9(9):e1309-e1314. doi: 10.1016/j.eats.2020.05.011.

164. Laprade MD, Camp CL, **Brockmeier SF**, Krych AJ, **Werner BC**. The cost of outpatient arthroscopic rotator cuff repairs: Hospital reimbursement is on the rise while surgeon payments remain unchanged. *Arthroscopy*. 2020 Sep;36(9):2354-2361. doi: 10.1016/j.arthro.2020.03.038. Epub 2020 May 1.

165. LaValva SM, Baldwin K, Swarup I, Flynn JM, Pahys JM, Yaszay B, **Abel MF**, **Bachmann K**, Shah SA, Sponseller PD, Cahill PJ; Harms Study Group. Prolonged postoperative intubation after spinal fusion in cerebral palsy: Are there modifiable risk factors and associated consequences? *J Pediatr Orthop*. 2020 Sep;40(8):431-437. doi: 10.1097/BPO.0000000000001566.

166. Hess DE, Carstensen SE, Moore S, **Dacus AR**. Smoking increases postoperative complications after distal radius fracture fixation: A review of 417 patients from a level 1 trauma center. *Hand*. 2020 Sep;15(5):686-691. doi: 10.1177/1558944718810882.

167. Althoff AD, Chen DQ, Quinlan ND, **Werner BC**, **Browne JA**. Urinary self-catheterization is not associated with increased risk of major complications following total hip and knee arthroplasty. *J Arthroplasty*.

2020 Sep;35(9):2380-2385. doi: 10.1016/j.arth.2020.04.017. Epub 2020 Apr 11.

168. Sequeira SB, Chen DQ, Bell JE, Quinlan ND, **Werner BC**, **Browne JA**. Hypogonadism is associated with increased risks of postoperative complications following total hip arthroplasty. *J Arthroplasty*. 2020 Sep;35(9):2495-2500. doi: 10.1016/j.arth.2020.04.009. Epub 2020 Apr 11.

169. Moran TE, Sequeira S, **Cooper MT**, **Park J**. A retrospective analysis of outcomes from foot and ankle arthrodesis and open reduction and internal fixation using cellular bone allograft augmentation. *Foot Ankle Spec*. 2020 Aug 31;1938640020952301. doi: 10.1177/1938640020952301. Online ahead of print.

170. Levinson J, Reissig J, Schaeen E, Lee W, **Park J**. Complications and radiographic outcomes after tibiototalcaneal fusion with a retrograde intramedullary nail. *Foot Ankle Spec*. 2020 Aug 24;1938640020950153. doi: 10.1177/1938640020950153. Epub ahead of print.

171. Yildirim B, **Deal DN**, **Chhabra AB**. Two-screw fixation of scaphoid waist fractures. *J Hand Surg Am*. 2020 Aug;45(8):783.e1-783.e4. doi: 10.1016/j.jhssa.2020.03.013. Epub 2020 Apr 20.

172. **Park JS**, Porter DA, Sferra JJ, **Cooper MT**. Post-operative weight bearing and rehabilitation after foot and ankle surgery. *Foot Ankle Spec*. 2020 Aug;13(4):330-334. doi: 10.1177/1938640020938912.

173. **Hadeed MM**, Jennewine BR, George J, **Yarboro SR**. Harris heel view is inadequate to visualize screw prominence of the medial calcaneus: A case report and cadaveric evaluation. *JBS Case Connect*. 2020 Jul-Sep;10(3):e2000161. doi: 10.2106/JBS.CC.20.00161.

174. Jain A, Yeramaneni S, Keabaish KM, Raad M, Gum JL, Klineberg EO, **Hassanzadeh H**, Kelly MP, Passias PG, Ames CP,

Smith JS, Shaffrey CI, Bess S, Lafage V, Glassman S, Carreon LY, Hostin RA; The International Spine Study Group. Cost-utility analysis of rhBMP-2 use in adult spinal deformity surgery. *Spine*. 2020 Jul 15;45(14):1009-1015. doi: 10.1097/BRS.0000000000003442.

175. Myhre L, **Duensing I**, Jones K, Holmes S. Iatrogenic Physseal Separation During Attempted Reduction of an Obturator Hip Dislocation: Don't do this case report. *JPOSNA*. 2020 Jul 5;2(2). Retrieved from <https://www.jposna.org/ojs/index.php/jposna/article/view/108>.

176. Moran TE, Awowale JT, **Werner BC**, Fox MA, **Miller MD**. Author reply to 'Regarding "Associated morbidity after the percutaneous release of the medial collateral ligament for knee arthroscopy."' *Arthroscopy*. 2020 Jul;36(7):1798-1799. doi: 10.1016/j.arthro.2020.05.017. Epub 2020 May 20.

177. **Miller MD**. Elbowing our way beyond Tommy John. *Clin Sports Med*. 2020 Jul;39(3):xiii. doi: 10.1016/j.csm.2020.04.003.

178. Smith JM, Rush J, Carstensen SE, **Diduch D**. Trochleoplasty: Indications and results. In: Dejour D, Arendt EA, Sillanpää, Dirisamer F. *Patellofemoral Pain, Instability, and Arthritis*. 2nd ed. ESKA, Springer; 2020 May 24: Chapter 25:303-312.

179. Yuan X, Zhang P, Zhang Y, Holzer L, Xiao L, He Y, Majumda R, Yu X, Ramasubramanian R, Jin L, Wang Y, **Li X**, Oberholzer J. A multi-throughput mechanical loading system for mouse intervertebral disc. *J Mech Behav Biomed Mater*. 2020 May;105:103636. doi: <https://doi.org/10.1016/j.jmbbm.2020.103636>.

180. **Hadeed MM**, Dempsey JJ, Tyrrell Burrus M, **Werner BC**, Walker JB, **Perumal V**, Park JS. Predictors of osteochondral lesions of the talus in patients undergoing Broström-Gould ankle ligament reconstruction. *J Foot Ankle Surg*. 2020 Jan-Feb;59(1):21-26. doi: 10.1053/j.jfas.2018.05.006.



REVOLUTIONIZING HOW THE WORLD VIEWS HUMAN MUSCLE



Springbok's AI-powered technology transforms musculoskeletal MRI data into interactive 3D analyses - providing objective, holistic data to enable true precision medicine.

Email us at Info@springbokanalytics.com or visit us online at SpringbokAnalytics.com



Know more. Cut less.

Know how some things are simply better together? Like the knowledge that comes from a CT-based plan that captures each patient's unique anatomy, and Mako's AccuStop™ haptic technology, which helps you use this knowledge to precisely and accurately cut what you've planned.^{1,2,3}

So you know more and cut less.^{4,5,6,7*}

That's Mako. SmartRobotics™.



Visit makosmartrobotics.com to learn more.

*** For the Mako Total Knee application, "cut less" refers to less soft tissue damage and greater bone preservation as compared to manual surgery.^{5,6} For the Mako Total Hip and Partial Knee applications, "cut less" refers to greater bone preservation as compared to manual surgery.^{4,7}**

1. Anthony I, Bell SW, Blyth M, Jones B et al. Improved accuracy of component positioning with robotic-assisted unicompartmental knee arthroplasty. *J Bone Joint Surg Am*. 2016;98-A(8):627-35.
2. Illgen, R, Bukowski, B, Abiola, R, Anderson, P, Chughtai, M, Khlopas, A, Mont, M. Robotic-assisted total hip arthroplasty: Outcomes at minimum two year follow up. *Surgical Technology International*. 2017 July 25; 30:365-372.
3. Mahoney O, Kinsey T, Mont M, Hozack W, Orozco F, Chen A. Can computer generated 3D bone models improve the accuracy of total knee component placement compared to manual instrumentation: a prospective multi-center evaluation? *International Society for Technology in Arthroplasty 32nd Annual Congress*. Toronto, Canada. October 2-5, 2019.
4. Suarez-Ahedo, C; Gui, C; Martin, T; Chandrasekaran, S; Domb, B. Robotic arm assisted total hip arthroplasty results in smaller acetabular cup size in relation to the femoral head size: A Matched-Pair Controlled Study. *Hip Int*. 2017; 27 (2): 147-152.
5. Haddad, FS, et al. Iatrogenic Bone and Soft Tissue Trauma in Robotic-Arm Assisted Total Knee Arthroplasty Compared With Conventional Jig-Based Total Knee Arthroplasty: A Prospective Cohort Study and Validation of a New Classification System. *J Arthroplasty*. 2018 Aug;33(8):2496-2501. Epub 2018 Mar 27.
6. Hozack, W, Chen, A, Khlopas, A, Mahoney, O, Mont, M, Murray, T, Orozco, F, Higuera Rueda, C, Stearns, K. Multicenter Analysis of Outcomes after Robotic-Arm Assisted Total Knee Arthroplasty. *American Academy of Orthopedic Surgeons Annual Meeting*. Las Vegas, NV. March 12-16, 2019.
7. Banks, Scott A, PhD. Haptic Robotics Enable a Systems Approach to Design of a Minimally Invasive Modular Knee Arthroplasty. *Am J Orthop*. 2009;38(2 suppl):23-27. February 2009.

A surgeon must always rely on his or her own professional clinical judgment when deciding whether to use a particular product when treating a particular patient. Stryker does not dispense medical advice and recommends that surgeons be trained in the use of any particular product before using it in surgery. The information presented is intended to demonstrate the breadth of Stryker's product offerings. A surgeon must always refer to the package insert, product label and/or instructions for use before using any of Stryker's products.

Products may not be available in all markets because product availability is subject to the regulatory and/or medical practices in individual markets. Please contact your sales representative if you have questions about the availability of products in your area. Stryker Corporation or its divisions or other corporate affiliated entities own, use or have applied for the following trademarks or service marks: AccuStop, Mako, SmartRobotics, Stryker. All other trademarks are trademarks of their respective owners or holders.

EMPOWER™

LEADING THE MOVEMENT

A culmination of research, clinical legacy and material technologies that have resulted in hip and knee products that help restore healthy kinematics and provide surgical efficiencies optimized for today's health care environment.

djoglobal.com/empower



EMPOWR
Acetabular™ Cup



EMPOWR™
Complex Primary
Knee



EMPOWR
Porous™ Knee



EMPOWR
3D Knee™



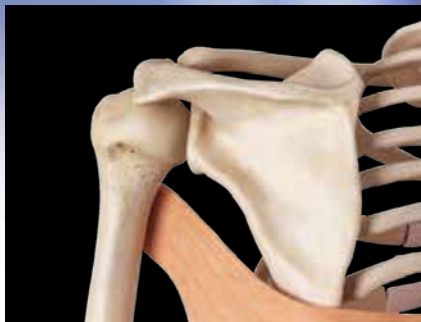T 800.456.8696 D 512.832.9500 F 512.834.6300
9800 Metric Blvd. | Austin, TX 78758 | U.S.A.
DJOGlobal.com/surgical

Copyright © 2020 by DJO, LLC
MKT0171037-001REV A

Individual results may vary. DJO Surgical® is a manufacturer of orthopedic implants and does not practice medicine. Only an orthopedic surgeon can determine what treatment is appropriate. The contents of this document do not constitute medical, legal or any other type of professional advice. This material is intended for the sole use and benefit of the DJO Surgical sales force and physicians. It is not to be redistributed, duplicated or disclosed without the express written consent of DJO Surgical. For product information, including indications, contraindications, warnings, precautions and side effects, refer to the Instructions for Use supplied with the device.

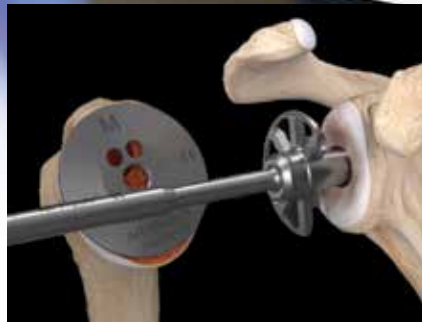OrthoPedia

Orthopedic Surgery Education



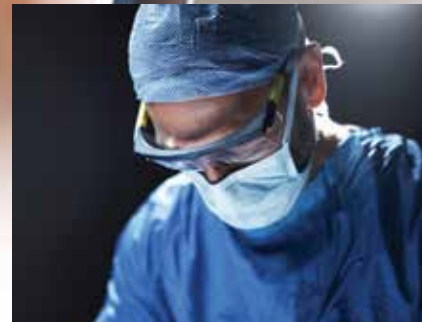ANATOMY

Based on pathology



BIOMECHANICS

Pathomechanics and classifications



CLINICAL APPLICATIONS

Surgical procedures by experts

For more information,
visit [OrthoPedia.com](https://www.OrthoPedia.com)



VELYS™ Robotics

Designed for digital precision in knee replacement

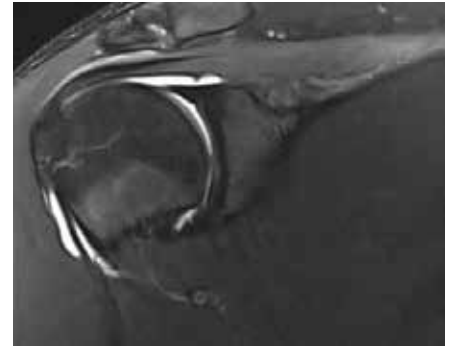
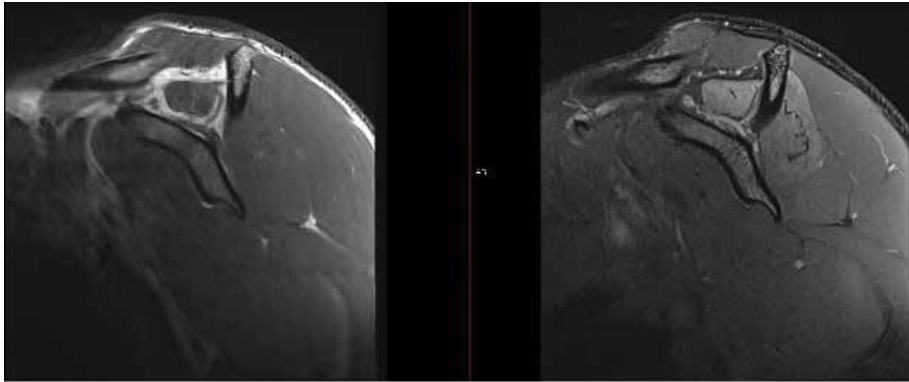
Start moving again with the VELYS™ Robotic-Assisted Solution

To learn more, talk to your doctor or visit
VELYSPatient.com

The knee featured is a visual representation of the ATTUNE® Knee System implant position.
Please refer to the instructions for use for a complete list of indications, contraindications, warnings, and precautions.
Every patient is different, and individual results vary. Not all patients are candidates for joint replacement. All surgeries carry risks.
©DePuy Synthes 2021. All rights reserved. 169671-210308 DSUS

2 MINUTE CONSULT

A 20 year old male was seen in the Sports clinic with left shoulder pain. He denied any antecedent trauma, but did endorse an insidious onset of pain coinciding with his recent increase in weight-lifting frequency and intensity. More recently he has begun to notice weakness in shoulder abduction and difficulty hitting the highest cymbal on his drum kit. An MR arthrogram was obtained. What is the diagnosis, and what is the best treatment for this issue?

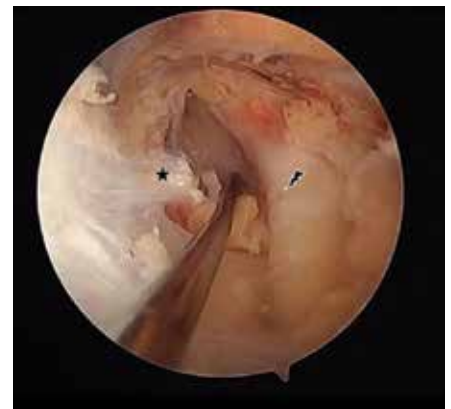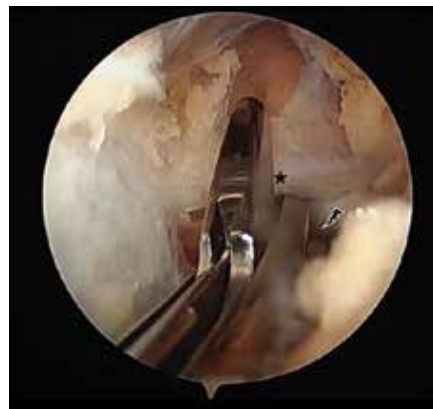

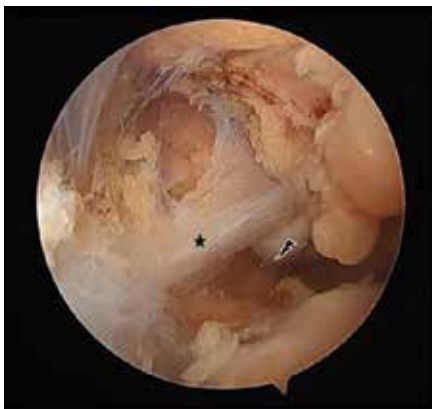
This patient's history is concerning for labral and rotator cuff pathology. His diagnosis of *suprascapular nerve entrapment* becomes more clear after viewing his coronal and sagittal MR images. The coronal images show intact supraspinatus tendon, while the sagittal images reveal muscular edema of the supraspinatus and infraspinatus muscle bellies

with profound atrophy of the supraspinatus.

The best treatment option for this patient is arthroscopic decompression of the suprascapular nerve. The suprascapular nerve is commonly compressed in one of two locations: the suprascapular notch and the spinoglenoid notch. Given that the spinoglenoid notch exists distal to the innervation of supraspinatus,

this patient's compression must be occurring at the suprascapular notch. The best treatment for this patient is arthroscopic division of the transverse scapular ligament. Arthroscopic images show the intact ligament (denoted by a star) compressing the suprascapular nerve (denoted by a lightning bolt), transection of the ligament, and the decompressed nerve. ■



Help Make Great Orthopaedic Care at UVA Even Better.

Many alumni want to ensure the future success of the department that prepared them for their careers.

Private support is critical to advancing innovation in patient care and education.

You can help.

UVA Musculoskeletal Center at Ivy Mountain Donor Opportunities

Construction of an extraordinary new orthopaedic and sports medicine facility is underway. This world-class complex will offer nationally ranked expertise and care found in few other places—all in one setting. Complete with walking gardens and outdoor therapeutic spaces, UVA's Musculoskeletal Center at Ivy Mountain will offer a comprehensive healing environment for both athletes and community members alike. Highlights include:

- All services in one location, with easy patient access
- Convenient parking
- Nationally ranked specialist care
- On-site diagnosis, imaging, surgery, physical therapy, and rehabilitation
- Outpatient hip and knee joint replacement facility
- Unique opportunities for ongoing research and education

The Shepard Hurwitz Research Fund

The University of Virginia Orthopaedic Research Fund supports our orthopaedic surgeon scientists as they perform groundbreaking research, provide the highest quality patient care, and educate tomorrow's leaders in orthopaedic surgery. Your support can:

- Speed groundbreaking discoveries to prevent and treat challenging orthopaedic diseases
- Quickly move discoveries out of the lab and into the clinic
- Put more scientists to work on finding cures by establishing professorships to help recruit the most talented physicians and scientists
- Give our investigators the resources and equipment they need to search for answers

The Gwo-Jaw Wang Orthopaedic Resident Education Fund and the Frank McCue Orthopaedic Resident Education Fund

Your gift to support education is an investment in the future of healthcare.

Endowment gifts are long-term investments that are aimed at securing the success of the Health System for years to come. An endowment may be used to fund a named scholarship or fellowship with a gift of \$250,000 or \$500,000.

In addition, a gift of \$2 million or more can be used to endow a professorship that enhances research by the Department of Orthopaedic Surgery. These endowed professorships generate funds for salary support that enables UVA to attract and retain distinguished faculty.

Your generous contribution—no matter its size—can be used where the need is greatest, or you can designate an area that is especially meaningful to you.

To Make a Gift or Learn More, visit:

<https://med.virginia.edu/orthopaedic-surgery/mission-statement/orthopaedic-giving/>

Or, if you prefer, you may speak directly with a development officer by calling: 434-962-3675



**ORTHOPAEDIC
JOURNAL**

2280 Ivy Road
Charlottesville, VA 22903

PRESORT
STANDARD
US Postage
PAID
Waynesboro, VA
Permit No. 129



**ORTHOPAEDIC
JOURNAL**

www.uvaortho.com