



# WHAT YOU OTO KNOW

THE UNIVERSITY OF VIRGINIA  
DEPARTMENT OF OTOLARYNGOLOGY-  
HEAD AND NECK SURGERY

SPRING 2021  
VOL. 2, NO. 1

## CLINIC UPDATE

Meet our new clinic manager and learn about challenges during her first year and plans moving forward

---

## DIVISION PEARLS

Clinical pearls explored by faculty & residents

---

## RESIDENT LIFE

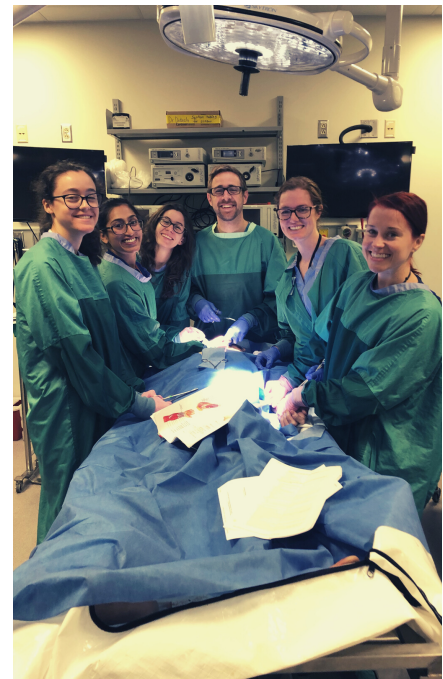
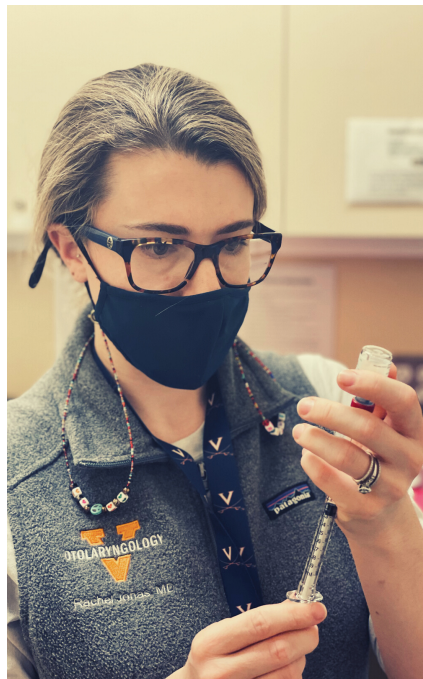An interview with our chiefs on their residency experience and next steps



# Department of Otolaryngology- Head and Neck Surgery

The University of Virginia Department of  
Otolaryngology-HNS  
P.O. Box 800713  
Charlottesville, VA 22908

[med.virginia.edu/otolaryngology](http://med.virginia.edu/otolaryngology)



What You Oto Know is a biannual  
newsletter published by The University of  
Virginia Department of Otolaryngology-  
Head and Neck Surgery.

Please send questions, comments and  
requests for hard copies to Andrew  
Strumpf. [as9qn@virginia.edu](mailto:as9qn@virginia.edu)

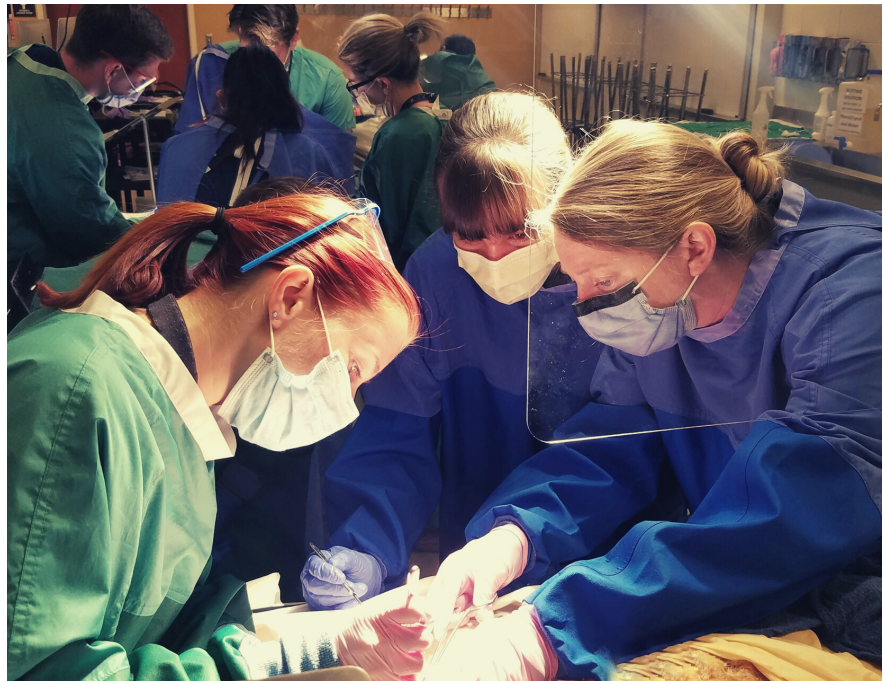## What You Oto Know Spring 2021 VOL. 2, NO. 1

### Editor

Andrew Strumpf

### Creative Director

Chelsey Jankowski



NEWS &  
FEATURES



Find previous issues and subscribe  
to future issues on our website.  
[med.virginia.edu/otolaryngology/about/what-you-oto-know](http://med.virginia.edu/otolaryngology/about/what-you-oto-know)

PAGE 12-13

Research &  
Publications  
PAGE 14-18

Alumni Feature

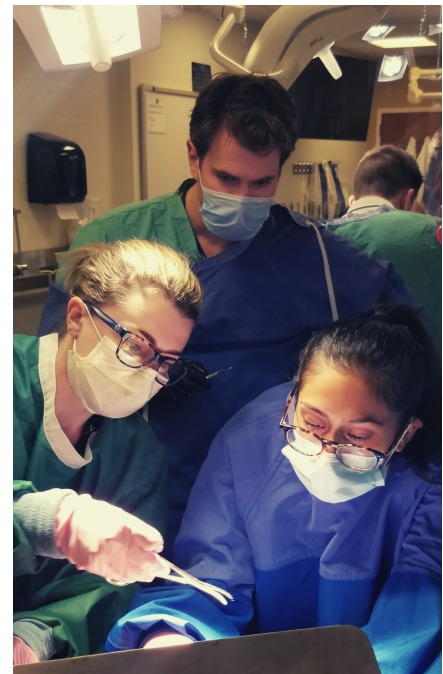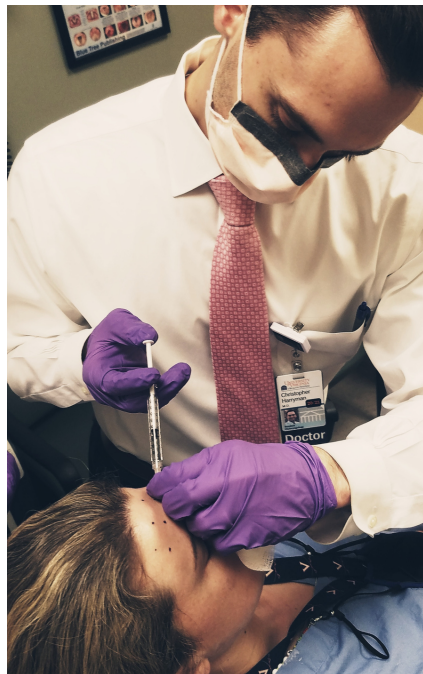PAGE 19-20

Giving Back

PAGE 21

Honors & Awards  
PAGE 22

Recent & Upcoming  
Events  
PAGE 23





# NEWS & FEATURES

---

**Faculty**  
**PAGE 3**

**Residents & Fellows**  
**PAGE 4**

**Staff Update & Upcoming Events**  
**PAGE 5**

**Clinic Update**  
**PAGE 6**

**Division Pearls**  
**PAGE 7-12**

**Research Update**  
**PAGE 13**

**Resident Life**  
**PAGE 14**



# LOCATIONS

---




- UVA Health
- ENT Clinic at Fontaine
- Emily Couric Clinical Cancer Center
- Pediatric Oto Clinic at the Battle Building
- Charlottesville ENT Associates  
(Not pictured)



# FACULTY

## Facial Plastic & Reconstructive Surgery



Stephen Park, MD  
Department Chair,  
Division Director,  
Professor




Samuel Oyer, MD  
Associate Professor

## Rhinology & Endoscopic Sinus Surgery



Spencer Payne, MD  
Division Director,  
Associate Professor




Jose Mattos, MD, MPH  
Assistant Program Director,  
Assistant Professor


## Head & Neck Oncologic & Microvascular Surgery



Mark Jameson, MD, PhD  
Division Director,  
Associate Professor



David Shonka, MD  
Associate Professor



Katherine Fedder, MD  
Assistant Professor



Jonathan Garneau, MD  
Assistant Professor


## Laryngology & Voice Care




James Daniero, MD, MS  
Division Director,  
Associate Professor



Patrick McGarey Jr., MD  
Assistant Professor



George Hashisaki, MD  
Division Director,  
Associate Professor



Bradley Kesser, MD  
Vice-Chair,  
Program Director,  
Professor

## Otology & Neurotology

## Pediatric Otolaryngology



Stephen Early, MD  
Division Director,  
Associate Professor



William Brand, MD  
Assistant Professor



Daniel Landes, MD  
Associate Professor

## General Otolaryngology



John Mason, MD  
Associate Professor


## Audiology/Vestibular & Balance Center



Lori Grove, PhD  
Division Director,  
Assistant Professor

# RESIDENTS

CHIEFS



Harry Bartels, MD



Garrett Casale, MD


PGY4



Delaney Carpenter, MD



Ian Churnin, MD



Caitlin Iorio, MD

PGY3



Annesha Basu, MD




Rachel Jonas, MD



Neil Saez, MD

PGY2



Simone Barker, MD



Hyunseo "David"  
Jung, MD



Jeffrey Mella, MD

PGY1



Nelson  
Gruszczynski, MD



Claudia Gutierrez, MD



Christopher  
Harryman, MD

## FELLOWS



Geoffrey Casazza, MD  
Neurotology Fellow



Shruti Jayachandra, MD  
Facial Plastic &  
Reconstructive Surgery  
Fellow



## Happy Retirement Dr. Gleason

After 20 years of dedicated service to UVA's Department of Otolaryngology-Head & Neck Surgery, Tucker Gleason, PhD, Director of Audiology and the Vestibular & Balance Center, is setting her sights on a well-deserved retirement.

A lifelong Virginian, Dr. Gleason received both her Master's degree in Audiology and her PhD from UVA. Joining UVA faculty in 2000 she became the Director of the Vestibular & Balance Center in 2001 and has maintained the title of Director of Audiology since 2009. During her tenure Dr. Gleason has served on numerous national and state level committees, boards and councils in addition to her committee participation within the University. She has also held a secondary faculty appointment in the UVA Department of Neurology.

Dr. Gleason's leadership in her division has been an integral part of framing Audiology at UVA. Her contributions to our department will always be valued and remembered. Please join us in wishing her all the best in her retirement!

*Stephen S. Park*  
DEPARTMENT CHAIR

## UPCOMING EVENTS

### **Combined Otolaryngology Spring Meetings: April 6-11**

Dr. Bradley Kesser, UVA Program Director and President of the American Neurotology Society (ANS) will be presenting presidential citations at the Spring ANS meeting April 10 to Dr. Paul Lambert, Dr. Paul Levine, Dr. George Hashisaki, and Dr. Robert Jahrsdoerfer (posthumously).

### **World Voice Day: April 16, 2021**

### **Jahrsdoerfer Visiting Professor: April 21, 2021**

Dr. Stephanie Moody-Antonio, MD, Associate Professor of Otolaryngology-Head and Neck Surgery, Eastern Virginia Medical School.

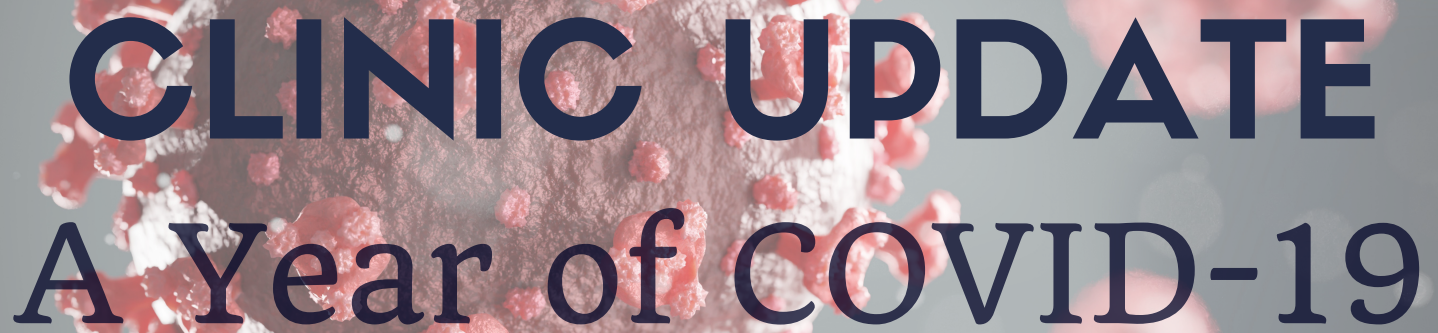
### **The 45th Annual Fitz-Hugh Symposium & UVA Department of Otolaryngology- Head and Neck Surgery Alumni Reunion: June 18-19, 2021**



## Welcome Dr. Grove

We are pleased to announce that Lori Grove, PhD is our newest Director of Audiology and the Vestibular Balance Center. Dr. Grove grew up in rural southwestern Virginia, but after moving to the beautiful Shenandoah Valley for her graduate work, she

knew this was home. She earned her PhD in Audiology from James Madison University under the mentorship of Dr. Roger Ruth, founder of the Audiology program at UVA. Dr. Grove joined the UVA Audiology Division in 2006 with a clinical focus in the areas of cochlear implants, electrophysiology and intraoperative monitoring. She has also served as the Coordinator of the Audiology Fellowship Program since 2012, cultivating a love for student mentorship and clinical education. Dr. Grove is excited to take on this new role leading the outstanding Audiology team at UVA. Outside of work, she and her husband, Tim, enjoy operating their Christmas tree farm and spending time with their two boys, Emmett and Isaac.



# CLINIC UPDATE

## A Year of COVID-19

Unprecedented. Over the past year we have heard that word used more times than ever before, and if asked to describe 2020 in one word, it would be the one I chose. Looking back on the past year, we can't help but to reflect on the many challenges faced in our clinical practice while learning how to navigate through the new-normal of the COVID-19 world we find ourselves in. It seems that almost every standard and practice traditionally held was modified or negated to mitigate the threat of the COVID-19 virus.

During the first wave of the COVID-19 pandemic we saw significant changes in our day-to-day practice. In late March 2020, the first statewide healthcare restrictions banned elective procedures and surgeries. It became necessary to prioritize resources based on patient needs. The ENT Surgical Subspecialties Pod, which is responsible for scheduling all appointments for our clinic, began fielding over 200 phone calls a day while also contacting patients to reschedule appointments. The clinic limited in-person visits based on need at a rate of no more than 20 patients per day. During this time we launched telemedicine appointments throughout the department which gave us the ability to provide care for patients with nonessential needs.

Starting in June, Virginia entered Phase 2 which authorized elective surgery operations. Adopting social distancing policy, PPE practices and pre-appointment COVID-19 screenings allowed the clinic to resume in-office procedures that were previously deemed too dangerous due to the potential for high aerosolization.

Today, clinic traffic is back to a normal flow despite many restrictions still in place. Patients must attend appointments alone with minimal exceptions however, patients can contact family members from the clinic room to speak directly to physicians and nursing staff. Telemedicine appointments remain an option for follow-up appointments at the patient's request. We have resumed our efforts to increase our pre-COVID staffing by 1RN and 2 CMAs in order to meet high demand.

As we continue to ramp up clinical activities, we look forward to exploring opportunities to improve upon the patient experience and work environment within the clinic setting. Our goals include streamlining the check-in and check-out process to cut back on paperwork and decrease patient wait times. We continue to tweak and improve on a service specific staffing model to ensure each division, and eventually each physician, has their own service staff to include a nurse and CMA. This will allow for a dedicated team of content experts in each subspecialty. Finally, we will continue to focus on our commitment to always meet and exceed regulatory requirements, such as The Joint Commission.

Adapting to the many changes in how we conduct patient care it is easy to see how the COVID-19 pandemic has reshaped healthcare for the future. We look forward to meeting those expectations head-on to provide the best care to our patients.

**HEATHER BLANCH, RN**  
CLINIC MANAGER

# The Nasal Valve

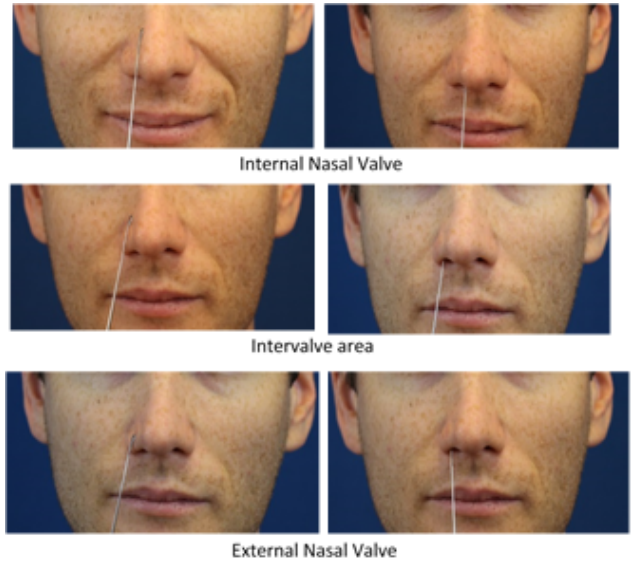
## DIVISION: FACIAL PLASTIC & RECONSTRUCTIVE SURGERY

Nasal obstruction is a common complaint in an otolaryngologic practice and has a dramatic impact on patient quality of life. The source of the problem is often multifactorial and most otolaryngologists are adept at diagnosing anatomical deformities of the septum and turbinates. Nasal valve dysfunction (NVD), on the other hand, can be challenging to diagnose precisely and may be overlooked as a source of nasal obstruction. The purpose of this article is to provide an overview of nasal valve dysfunction for the general otolaryngologist.

The nasal valve is the cross-sectional area at different points of the nasal cavity correlating with the greatest overall resistance to airflow, thus acting as a dominant determinant for nasal inspiration. It is further subdivided: The **internal valve** is the triangular cross-sectional area between the caudal border of the ULCs, the septum, the head of the inferior turbinate, and nasal floor. The **external valve** has classically referred to the area in the nasal vestibule, under the alar lobule, formed by the caudal septum, medial crura of the alar cartilages, alar rim, and nasal sill. Lastly, and perhaps most importantly, the **intervalve area** is defined as the caudal-lateral aspect of the lateral crus, including the fibrofatty tissue, which extends to the piriform aperture and immediately deep to the supra-alar crease. It is the space between the internal and external valves.

Nasal airflow is affected by both Pouseille's law and the Bernouli Principle. A structurally narrowed radius is consistent with Static NVD. If the nasal sidewall lacks rigidity, the nasal valve will collapse during inspiration as seen in Dynamic NVD. The etiology of both static and dynamic nasal valve dysfunction can be post-traumatic, idiopathic, or iatrogenic following prior nasal surgery.

It is always practical to consider mucosal causes of obstruction, e.g. allergies, medications, etc. Structural components often begin with the septum and turbinates. Assessing the nasal valve is an essential component of this exam.



The traditional Cottle maneuver is performed by pulling the cheek superiorly and laterally to assess a change in nasal patency; this is a nonspecific maneuver improving the intranasal space irrespective of the obstructive pathology. The modified Cottle maneuver is designed to precisely address nasal valve dysfunction and the anatomic etiology. This is performed using an ear curette to stabilize or slightly lateralize different points of the lateral nasal wall during inspiration. The figure shows the height to which the ear curette is placed inside the nasal cavity to evaluate the respective regions of stenosis/collapse. It is critical to support the tissue gently as to approximate what could reasonably be achieved surgically. An assessment of an audible change in nasal airflow as well as the patient's subjective experience determine the response to the maneuver. It may also simulate a subtle change to the external appearance.

Management of NVD often requires surgical intervention and selecting the appropriate technique depends on the location and type of dysfunction (dynamic/static). Corrective maneuvers include spreader grafts, flaring sutures, batten grafts, and lateral crural tensioning grafts. A future "pearl" will review our surgical techniques. Nasal obstruction has a multifactorial etiology and one should always look for and consider the nasal valve and lateral wall dysfunction.

**JEFFREY MELLA, MD**  
PGY-2



# Diagnosis and Management of Chronic Rhinosinusitis

## DIVISION: RHINOLOGY & ENDOSCOPIC SINUS SURGERY

**Chronic rhinosinusitis (CRS)** affects 10-15% of the population and is one of the most common chronic inflammatory and debilitating conditions in North America. (1) This condition has significant socioeconomic implications, with approximately \$8.3 billion spent annually on CRS. (1) The indirect cost is also consequential and on average accounts for one to two lost workdays per patient every year. (1) The accurate diagnosis of CRS can present a clinical challenge, as the symptom profile overlaps with a variety of conditions, including seasonal allergies, rhinitis, anatomic nasal obstruction, and headache/facial pain disorders.

The American Academy of Otolaryngology has established clear diagnostic guidelines for CRS, outlined below: (1)

- 12 weeks or longer of two or more of the following signs and symptoms:
  - Mucopurulent drainage (anterior, posterior, or both)
  - Nasal obstruction (congestion)
  - Facial pain-pressure-fullness
  - Decreased sense of smell
- AND inflammation is documented by one or more of the following findings:
  - Purulent (not clear) mucus or edema in the middle meatus or anterior ethmoid region
  - Polyps in nasal cavity or the middle meatus
  - Radiographic imaging showing inflammation of the paranasal sinuses

Despite these guidelines, the diagnosis can still present a challenge, particularly when the primary symptom complex surrounds facial pain and pressure. The clinician should proceed with caution when treating patients for CRS whose primary complaints include pain symptoms. In these patients, there should be a high level of clinical suspicion for a primary or co-morbid neurological diagnosis.

In these cases, the diagnosis should be confirmed with imaging, and medical management should be maximized before considering procedural intervention. Even in patients with objective findings of CRS who fail to improve on medical therapy, the clinician should carefully counsel the patient pre-operatively and manage post-procedural expectations. Sinus surgery has been shown to be most effective in improving the nasal components of CRS, like nasal obstruction and nasal discharge, but less effective in improving facial pain. Sinus surgery or sinuplasty pursued for the treatment of facial pain alone is likely to result in failure. (3) This is likely due to the fact that most facial pain or headache associated to CRS is likely due a secondary diagnosis or headache or atypical facial pain.

The most common **topical treatment** options for CRS are saline irrigation and topical corticosteroids. (1) While these are both well tolerated and cost-effective treatments, patients are often refractory to these therapies and are left with few other available topical alternatives. Endoscopic sinus surgery (ESS) has been shown to improve signs, symptoms, and quality of life in individuals with CRS. (2) Although topical therapies and ESS provide relief for many patients with CRS, refractory CRS continues to make up a large portion of the population, necessitating the need to develop novel, low-cost therapeutics with minimal adverse effects to provide some relief to these chronic sufferers. The UVA Department of Otolaryngology- Head and Neck Surgery is actively researching potential avenues to expand the therapeutic options of patients with CRS including adopting established therapeutic agents in other conditions and designing randomized clinical trials, as well as exploring novel and alternative therapies for these patients.

**ANNESHA BASU, MD**  
PGY-3

# Hypoglossal Nerve Stimulator

## DIVISION: HEAD & NECK ONCOLOGIC & MICROVASCULAR SURGERY

Several surgeries have been proposed to treat obstructive sleep apnea (OSA) but the gold standard of therapy remains use of continuous positive airway pressure (CPAP). A large subset of patients with OSA struggle with CPAP intolerance. As a result these patients remain undertreated or untreated and are at significantly increased risk for cardiovascular complications.

A new option for patients with OSA and CPAP intolerance is the hypoglossal nerve stimulator. This device selectively stimulates the muscles that protrude the tongue. It has 3 components: a stimulator lead, a battery/generator, and a respiratory sensor.

The device is implanted in an outpatient procedure under general anesthesia. The first incision is made just below the mandible. The branches of the hypoglossal nerve responsible for tongue protrusion are isolated and the stimulator lead is placed. A second incision is made in the upper chest and the generator is placed within a subcutaneous pocket, very similar to a pacemaker. A final incision is made in the lateral chest wall and the respiratory sensor is placed between the intercostal muscles. The two leads are then connected to the generator through subcutaneous tunnels.

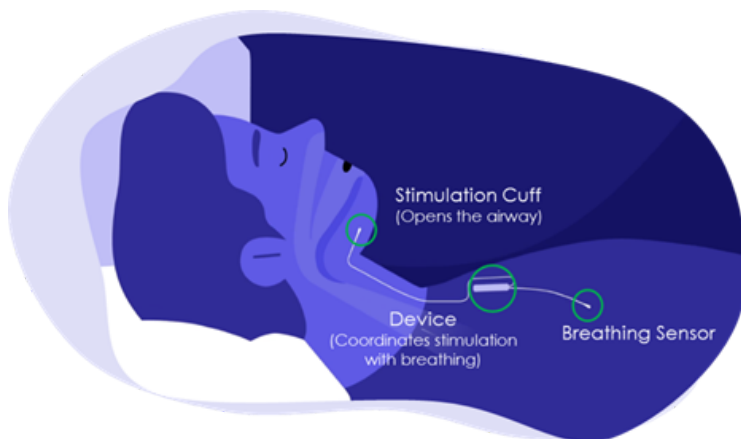
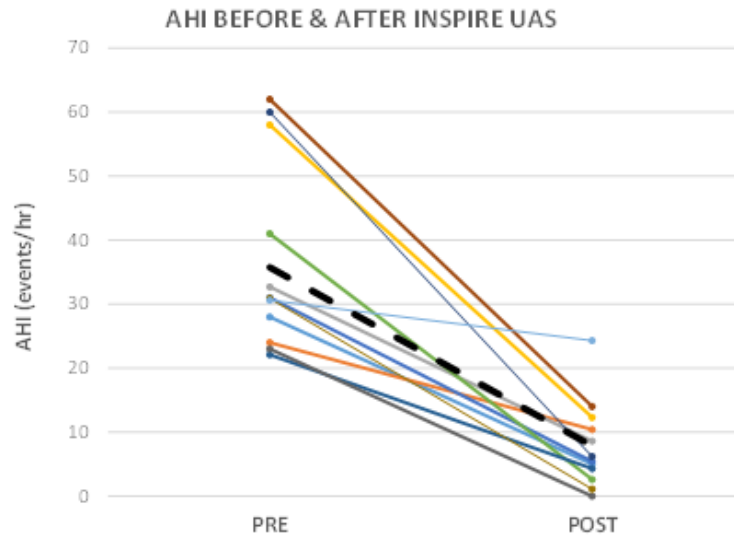


Image courtesy of Inspire Medical Systems, Inc.



Functional outcomes for the first 12 upper airway stimulator implants at UVA. Dashed line represents average change in AHI.

The device is activated at the time of sleep and functions by syncing chest wall expansion with protrusion of the tongue and stiffening of the palate. This reduces upper airway obstruction during inspiration in patients who obstruct at the tongue base and palate. The device can result in improvement of OSA, reducing or eliminating the need for CPAP.

To qualify for hypoglossal nerve stimulator patients must be at least 22 years old, have moderate to severe OSA (AHI 15-65), be unable to tolerate CPAP, and be free of complete concentric collapse at the palate as determined by a pre-operative drug-induced sleep endoscopy (DISE).

At UVA, we have found the device to be effective in most patients and, unlike CPAP, patient compliance is high. With appropriate patient selection and surgical expertise, the hypoglossal nerve stimulator is a promising new device that can help patients with OSA lead a healthier and happier life.

**GARRETT CASALE, MD**  
CHIEF RESIDENT

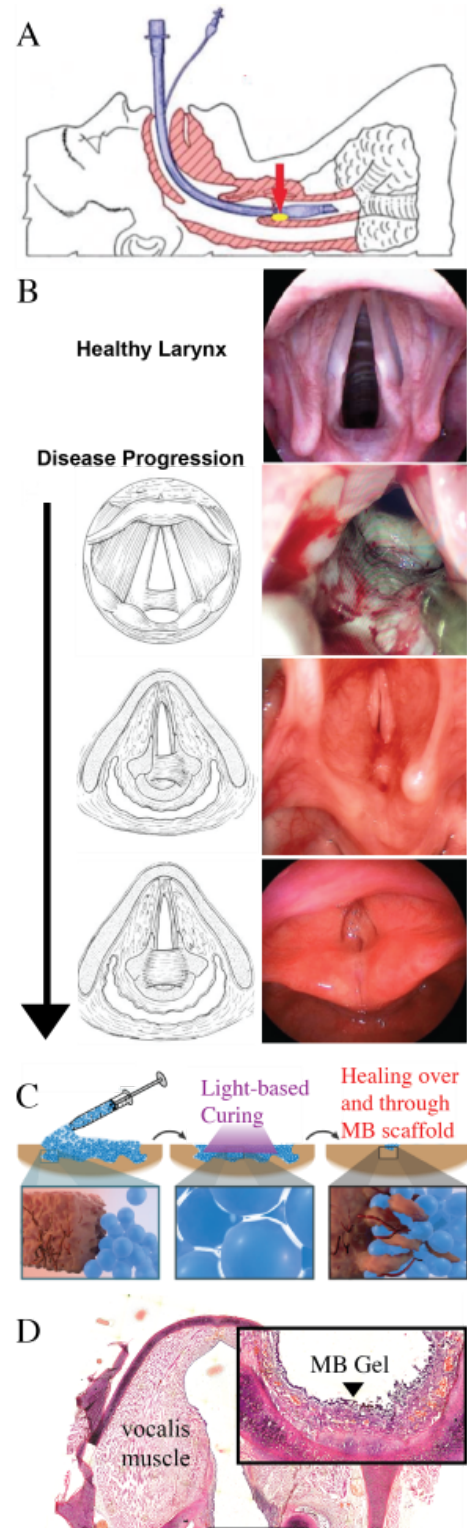
# Addressing the Laryngeal Sequela of COVID-19

**DIVISION: LARYNGOLOGY & VOICE CARE**

An unfortunate side effect of ICU treatment of COVID-19 patients has been a dramatic increase in long-term tracheal intubation. Extended intubation of greater than 10 days results in a high likelihood (>30%) of pressure-associated ulcer formation and production of a poorly healing laryngeal mucosal defect. Mucosal defects regularly create dense scars that can impair voice, obstruct breathing and swallowing. As a result, surgical excision of the fibrotic blockage is necessary. Unfortunately, methods of preventing scar recurrence are marginally effective, at best. This potentially fatal complication has afflicted many COVID-19 survivors. Research in the department is leading the charge dealing with this problem by developing a biomaterial device that will simultaneously accelerate healing and prevent scar recurrence following surgical excision of fibrotic blockages (Figure 1.). Specifically, this project will focus on the adaptation of a biomaterial platform that has proven successful in dermal regeneration with a focus on building from promising pilot result by designing an electrostatically charged biomaterial to promote retention within the mechanically traumatic tissue environment (e.g. swallowing and coughing). The group is currently establishing a structure-function relationship (material design and retention within mucosal tissue) and validation of pro-regenerative/anti-fibrotic healing effects in a clinically relevant surgical revision animal model, respectively. Through this work we have been able to establish a new line of NIH-funded research and partnership between Drs. Daniero and Griffin (Biomedical Engineering). The team has recently been awarded an R21 grant over the next 2 years to develop this technology that could revolutionize the way we manage mucosal injury.

Figure 1: (A) Endotracheal intubation for long periods promotes iatrogenic intubation injury (arrow indicates site of pressure-induced wound)5. 31% of patients intubated for >10 days leads to (B) onset of posterior glottic stenosis (PGS). Clinical images provided by Dr. Daniero. (C) The MB scaffold is composed of an injectable slurry of microparticles that are light-cured in situ to form a regenerative scaffold. (D) Our pilot study with a homogeneous chitosan scaffold treatment of a rabbit PGS model yielded mixed results as the scaffold adherence to the tissue was maintained after 2 weeks, however the material showed cohesive failure (i.e. thin layer of particles remained).

**JAMES DANIERO, MD**  
DIVISION DIRECTOR &  
ASSOCIATE PROFESSOR



# Balloon Eustachian Tuboplasty

## DIVISION: OTOLGY & NEUROTOLOGY

Conventional management of Eustachian tube dysfunction (ETD) has relied on treating the sequelae of ETD, including chronic otitis media with effusion (COME), middle ear atelectasis, tympanic membrane retraction and perforation, and cholesteatoma, without addressing the underlying ET pathophysiology. With new technology, clinicians are now addressing the fundamental Eustachian tube dilatory dysfunction that undergirds chronic ear disease.

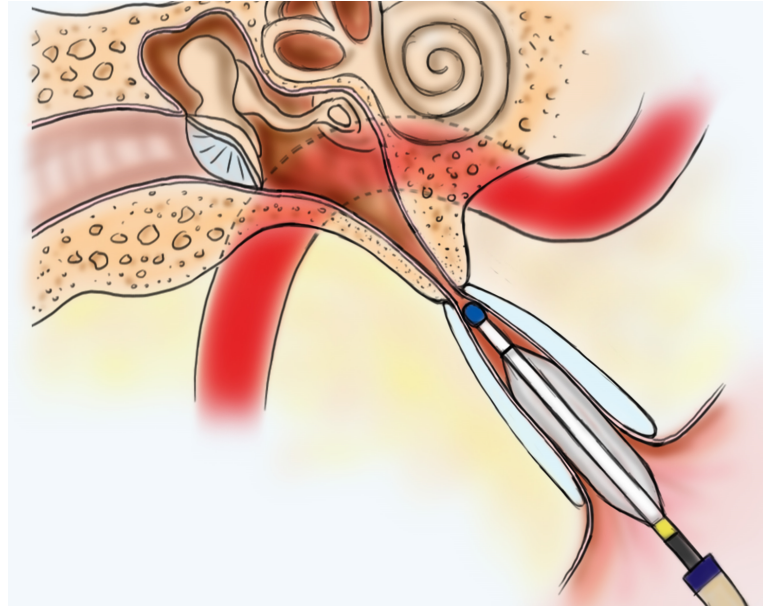
Balloon eustachian tuboplasty (BET), threading a balloon catheter into the cartilaginous portion of the ET and inflating the balloon to dilate the ET under nasal endoscopic control, has emerged as a viable treatment option for chronic ET dysfunction. Early feasibility studies in human cadavers demonstrated the safety of BET and that BET can increase the volume of the cartilaginous ET lumen an average of 357%. (1-2) Otolologists at UVA have embarked on this promising technology.

Surgeons recommend high-resolution computed tomography (CT) scanning preoperatively in patients undergoing the procedure to evaluate the course of the bony carotid canal to ensure safety of the procedure.

The procedure is typically performed under general anesthesia after topical decongestion and anesthesia of the nose. A catheter with a balloon on the end is introduced into the nasal cavity under direct endoscopic guidance using a 00 or 300 nasal endoscope. The catheter is gently inserted into the ET opening, and the balloon is advanced into the cartilaginous portion of the ET. The balloon is inflated with saline to 10 to 12 atm of pressure and left inflated for two minutes.

A second inflation can be performed after the balloon is deflated. (3-6) Angle of insertion can be changed if the catheter does not pass easily.

To assess the efficacy of the procedure, authors have turned to objective outcome measures of ETD and treatment, including the ability to autoinsufflate the ME, resolution of OME, tubomanometry, as well as a validated ET questionnaire (ETDQ-7). (7)



Two randomized controlled trials show efficacy of BET compared to medical management. (8-9) In one study, normalization of the tympanogram in 62.2% of patients was observed at 24 weeks with normalization of the ETDQ-7 in 56.2% at 6 week follow-up. (8) The other study showed a significant reduction in the mean ETDQ-7 score compared to control (medical management, daily intranasal steroid spray or one course of oral steroids) at the 6 week and 12 month marks. (9) Long-term follow-up (mean 29 months) of the latter cohort of patients showed persistent reduction from baseline in the ETDQ-7 score with 76% showing normal tympanic membrane position and 62.5% with normalization of the tympanogram. (10) No adverse events were reported in either study, although cervicofacial and mediastinal emphysema have been reported. (11)

Although there is a wide range of treatment modalities for ETD, (12) clearly, no ideal procedure or technology exists to reverse ongoing, chronic ETD. Nevertheless, these preliminary studies do hold promise not only for treating chronic ETD but also for potentially furthering our understanding of this complex structure and its dysfunction.

**BRADLEY KESSER, MD**  
**VICE CHAIR, PROGRAM DIRECTOR, & PROFESSOR**

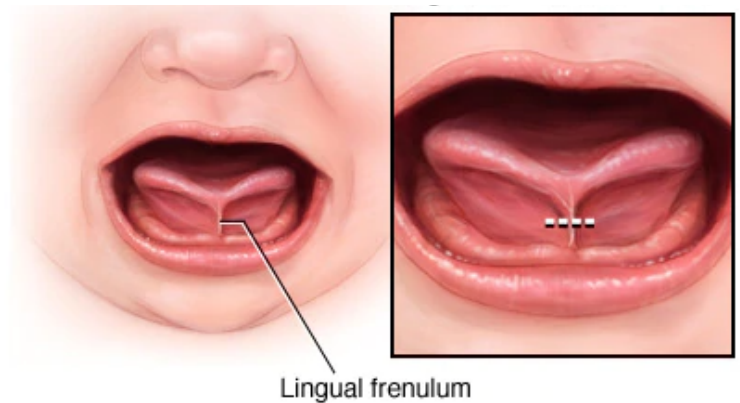
# Frenotomy

## DIVISION: PEDIATRIC OTOLARYNGOLOGY

For many otolaryngologists, tongue tie referrals can be very closely related to headaches. The push for breast feeding has led to increasing focus on ankyloglossia as a possible treatable cause for difficulty with breast feeding. Referrals for frenotomy have grown over time - research has shown greater than five fold increases in both ankyloglossia diagnoses and frenotomies performed over the last twenty years. Many of us also share the common experience of being approached by groups advocating for frenotomy and, unfortunately, many of us have not had the time to delve into the research to form opinions that we can be confident in.

Fortunately, ASPO recently developed a consensus statement for frenotomy. In practice, this has allowed our team to take a reasoned approach to the patients with ankyloglossia who pass through the offices in the Battle Building here at UVA. Many of us know the indications for frenotomy, which were posited in the statement (breast feeding difficulties with pain and latch). Therefore, it may be helpful to highlight a few of the other statements which may affect one's practice and/or allow for better counseling of patients:

1. Buccal frenotomy should not be performed.
2. Presence of an upper lip frenulum is normal in infants and labial frenotomy will not prevent future upper incisor diastema
3. Infants should ideally be evaluated by a lactation consultant or speech pathologist prior to lingual frenotomy, as oftentimes frenotomy can be avoided.
4. There is no evidence to support a standard post procedure care regimen (stretching, massaging, etc.).
5. Ankyloglossia does not cause sleep apnea.
6. Ankyloglossia does not typically cause speech issues and evaluation by speech pathology should be undertaken prior to frenotomy/frenuloplasty in older children.



© MAYO FOUNDATION FOR MEDICAL EDUCATION AND RESEARCH. ALL RIGHTS RESERVED.

The scissors are tried and true for frenotomy performance, but their use will often lead to bleeding. There are also arguments that the use of cold techniques has a somewhat higher recurrence rate - evidence of this has not been seen in the literature, but patients who Google will certainly find this. By making use of a jeweler's bipolar forceps (set to 15 watts) and a grooved director (also known as a "mickey mouse"), we have been able to get good results on all ties with minimal to no bleeding. As a bonus, this also allows for releasing tight muscle or mucosa that may be involved in the tie, meaning essentially all ties can be approached in clinic. Lastly, in situations where one is performing both lingual and labial frenotomy at the same time, this also permits for these both to be done in a very efficient manner, decreasing the time required for hemostasis through holding pressure. In our clinic, use of bipolar cautery has helped streamline procedure performance, allowing for a near seamless transition back to seeing patients, with good short and long term results.

**WILLIAM BRAND, MD**  
ASSISTANT PROFESSOR-  
PEDIATRIC OTOTLARYNGOLOGY

# RESEARCH UPDATE

APPLY  
NOW  
THROUGH  
MARCH  
31ST

## OTOLARYNGOLOGY RESEARCH FELLOWSHIP

12 Month  
Fellowship  
open to 3rd &  
4th year medical  
students or recent  
MD graduates

### Research Fellowship

The University of Virginia Department of Otolaryngology –Head & Neck Surgery is pleased to announce a new opportunity for medical students or recent MD graduates seeking 12 months of specialized research training. Through the mentorship from our committed faculty, the Fellow will gain invaluable experience leading novel projects that align with their area(s) of interest and help to support ongoing departmental research projects. The overall goal of this program is for the Fellow to develop: foundational knowledge and principles of study design, conduct, and data analysis; exposure to different otolaryngologic and research disciplines; and expertise supporting an academic career in otolaryngology. Visit our website to learn more and apply. <https://med.virginia.edu/otolaryngology/research/fellowship/>

## INTERNAL RESEARCH FUNDING

### ROBERT W. CANTRELL MD, RESEARCH GRANT / PAUL A. LEVINE, MD RESEARCH GRANT

Objective- To support innovative basic science, translational and clinical research by residents and faculty. To support worthy proposals that were not selected for funding by external mechanisms. One award cycle per year providing 2 grants up to \$8,000 each.

### SUBINOY DAS OTORHINOLARYNGOLOGY INNOVATION GRANT PROGRAM

Objective- To foster translational research partnerships linking medicine, law, regulatory governance, and business disciplines to provide immersive faculty and resident-driven product development experiences early in an Otolaryngologist's career. One award cycle per year providing 1-2 grants up to \$10,000 total.

## DIVISION PEARL REFERENCES

### The Nasal Valve (Page 7)

1. Barrett DM, Casanueva FJ, Cook TA. Management of the nasal valve. *Facial Plastic Surgery Clinics*. 2016 Aug 1;24(3):219-34.
2. Rhee JS, Weaver EM, Park SS, Baker SR, Hilger PA, Kriet JD, Murakami C, Senior BA, Rosenfeld RM, DiVittorio D. Clinical consensus statement: diagnosis and management of nasal valve compromise. *Otolaryngology-Head and Neck Surgery*. 2010 Jul 1;143(1):48-59
3. Park SS. The flaring suture to augment the repair of the dysfunctional nasal valve. *Plastic and reconstructive surgery*. 1998 Apr 1;101(4):1120-2.
4. Schlosser RJ, Park SS. Surgery for the dysfunctional nasal valve: cadaveric analysis and clinical outcomes. *Archives of facial plastic surgery*. 1999 Jun 1;1(2):105-10.

### Diagnosis and Management of Chronic Rhinosinusitis (Page 8)

1. Rosenfeld RM, Piccirillo JF, Chandrasekhar, SS, et al. Clinical Practice Guideline: Adult Sinusitis. *Otolaryngol Head Neck Surg*. April 2015; 152(S2):s1s39
2. Desrosiers M. Refractory chronic rhinosinusitis: pathophysiology and management of chronic rhinosinusitis persisting after endoscopic sinus surgery. *Curr Allergy Asthma Rep*. 2004;4(3):200-207.
3. Graham SM. Reasons for Failure in Endoscopic Sinus Surgery. *Current Otorhinolaryngol Report*. 1, 45-50 (2013).

### Balloon Eustachian Tuboplasty (Page 11)

1. Ockermann T.; Reineke U.; Upile T.; Ebmeyer J.; Sudhoff H.H.. Balloon dilation eustachian tuboplasty: A feasibility study. *Otol Neurotol* (2010) 31 (7) 1100-1103.
2. Poe D.S.; Hanna B.M.. Balloon dilation of the cartilaginous portion of the eustachian tube: Initial safety and feasibility analysis in a cadaver model. *Am J Otolaryngol* (2011) 32 (2) 115-123.
3. Poe D.S.; Silvola J.; Pyykko I.. Balloon dilation of the cartilaginous eustachian tube. *Otolaryngol Head Neck Surg* (2011) 144 (4) 563-569.
4. Catalano P.J.; Jonnalagadda S.; Yu V.M.. Balloon catheter dilatation of eustachian tube: A preliminary study. *Otol Neurotol* (2012) 33 (9) 1549-1552.
5. Ockermann T.; Reineke U.; Upile T.; Ebmeyer J.; Sudhoff H.H.. Balloon dilatation eustachian tuboplasty: A clinical study. *Laryngoscope* (2010) 120 (7) 1411-1416.
6. McCoul E.D.; Anand V.K.. Eustachian tube balloon dilation surgery. *Int Forum Allergy Rhinol* (2012) 2 (3) 191-198.
7. McCoul E.D.; Anand V.K.; Christos P.J.. Validating the clinical assessment of eustachian tube dysfunction: The eustachian tube dysfunction questionnaire (ETDQ-7). *Laryngoscope* (2012) 122 (5) 1137-1141.
8. Poe DS; Anand V; Dean M., et al. Balloon dilation of the Eustachian tube for dilatory dysfunction: A randomized controlled trial. *Laryngoscope* (2018) 128(5):1200-06.
9. Meyer TA; O'Malley EM; Schlosser RJ., et al. A Randomized controlled trial of balloon dilation as a treatment for persistent Eustachian tube dysfunction with 1-year follow-up. *Otol Neurotol*. (2018) 39:894-902.
10. Cutler JL; Meyer TA; Nguyen SA., et al. Long-term outcomes of balloon dilation for persistent Eustachian tube dysfunction. *Otol Neurotol*. (2019) 40(10):1322-25.
11. Skevas T; Dalchow CV; Euteneuer S., et al. Cervicofacial and mediastinal emphysema after balloon Eustachian tuboplasty: A retrospective multicenter analysis. *European Archives of Oto-Rhino-Laryngology* (2018) 275(1):81-87.
12. Adil E.; Poe D.S.. What is the full range of medical and surgical treatments available for patients with Eustachian tube dysfunction? *Curr Opin Otolaryngol Head Neck Surg* (2014) 22. 8-15.

# RESIDENT LIFE

## MEET THE CHIEFS

### How do you feel your residency experience helped you prepare for the future?

**Dr. Casale:** Great – I feel very prepared. Everyone has that gut check moment when preparing for the next step, and my confidence has improved significantly over the year. I'm confident in my ability to handle situations independently and take the initiative to offer help to attendings without being prompted.

**Dr. Bartels:** Very well prepared. Working with Drs. Park, Christophel and Oyer has been a huge boon to my future career in FPS. The breadth of training I received is unparalleled, particularly across subspecialties. Our attendings are approachable and promote us to think independently and challenge their decision making without feeling insubordinate.

### What is a major highlight of your residency?

**Dr. Casale:** The sinus course in Pittsburgh was very academically rewarding along with the opportunity to network. UVA is a very close knit group that empowers one another to offer help to attendings without being prompted. Our program offers juniors a ton of operative experience, especially for new surgeons.

**Dr. Bartels:** Applied and received an AAO-HNS grant for my rat mandible research project. Performing an entire surgery independently while an attending supervised was another!

### What's a memorable story of your fellow chief resident?

**Dr. Casale:** When Harry was voted the "Best Intern". I love working with Harry, he's my brother.

**Dr. Bartels:** Garrett is the "BEAST" – a nickname coined during his research block for his incredible work ethic and commitment. One time that stands out was when he emailed a rhinoplasty surgical tips article at 1:30 AM with a follow-up at 2:00.

### What are your plans following residency?

**Dr. Casale:** Neurotology Fellowship at the Michigan Ear Institute.

**Dr. Bartels:** Facial Plastics and Reconstructive Surgery Fellowship in Tampa, Florida.

### What motivated you towards this specialty?

**Dr. Casale:** My interest sparked with the mentorship from Dr. Kesser during medical school all the way through residency. I love the field, the patients, and being able to help people in tangible ways. The ability to restore someone's hearing and how they interact with their surroundings is phenomenal.

**Dr. Bartels:** The combination of foundational knowledge of anatomy and the human aesthetic along with the artistry of each case and how they're totally different. Each defect presents its own set of challenges.



Harry Bartels, MD



Garrett Casale, MD

### Favorites

#### Hike

**Dr. Casale:** Humpback Rock and Riprap trail

**Dr. Bartels:** Starting at Sugar Hollow up to the Appalachian Trail

#### Fitz-Hugh Project

**Dr. Casale:** Research block project with Dr. Shin – it was a rewarding and productive experience because it was outside my comfort zone.

**Dr. Bartels:** Bony Facial Trauma Score project

#### Bodo's Order

**Dr. Casale:** BLT on onion

**Dr. Bartels:** Egg provolone with avocado on everything

#### If you could take one thing with you from Charlottesville what would it be?

**Dr. Casale:** The Goochland drive-in movie theater and Carmello's Restaurant & Wine Bar.

**Dr. Bartels:** Bike rides with elevation change and experiencing the four seasons.

### Charlottesville Overrated / Underrated

#### Apple Picking

**Dr. Casale:** Properly Rated

**Dr. Bartels:** Overrated

#### Downtown Mall

**Dr. Casale:** Overrated- It's hard to get to and park! The restaurants and movie theaters are great though.

**Dr. Bartels:** Underrated



UNIVERSITY  
*of* VIRGINIA

Department of Otolaryngology-  
Head and Neck Surgery

What You Oto Know  
Spring 2021 VOL. 2, NO. 1