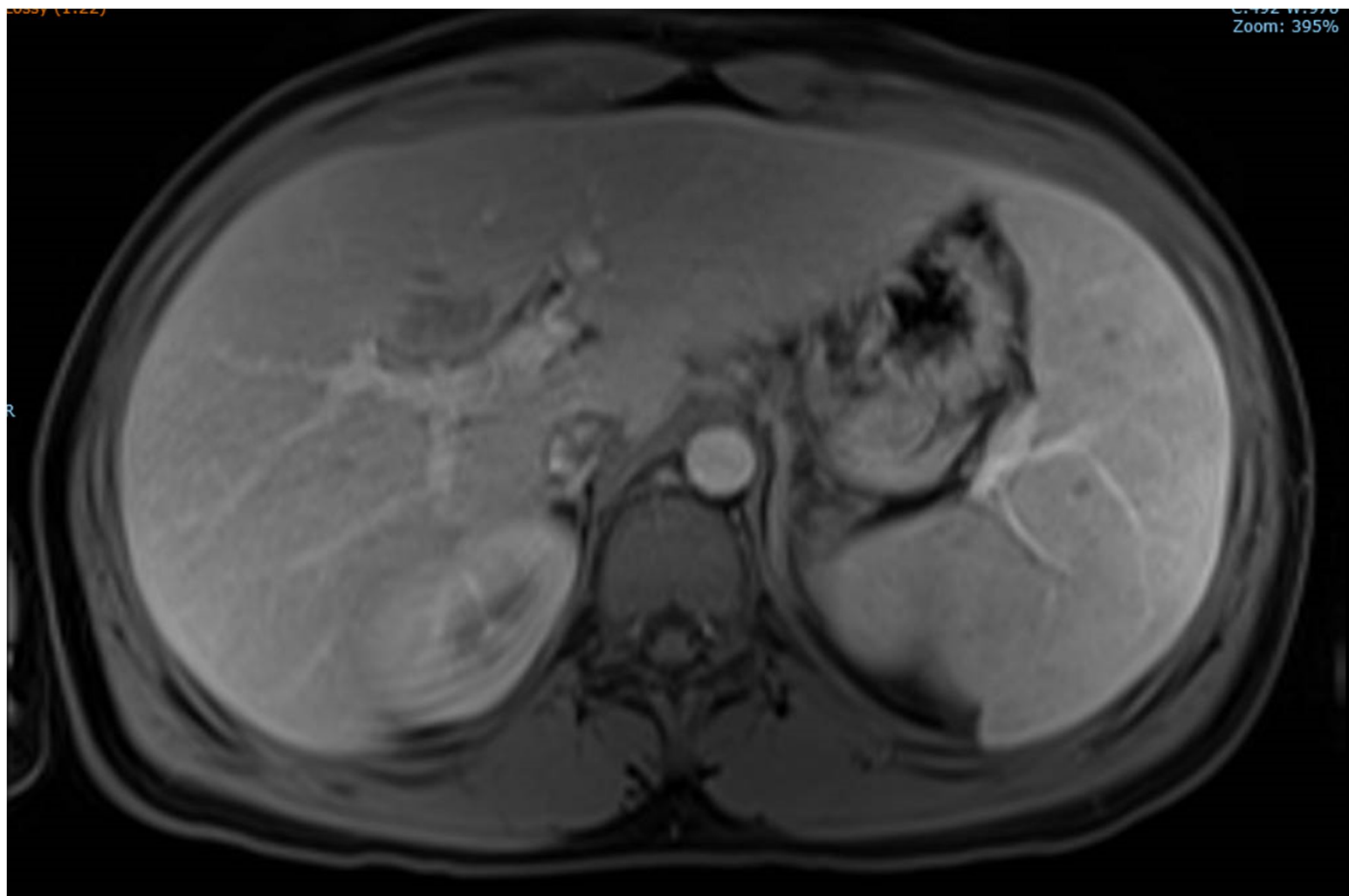


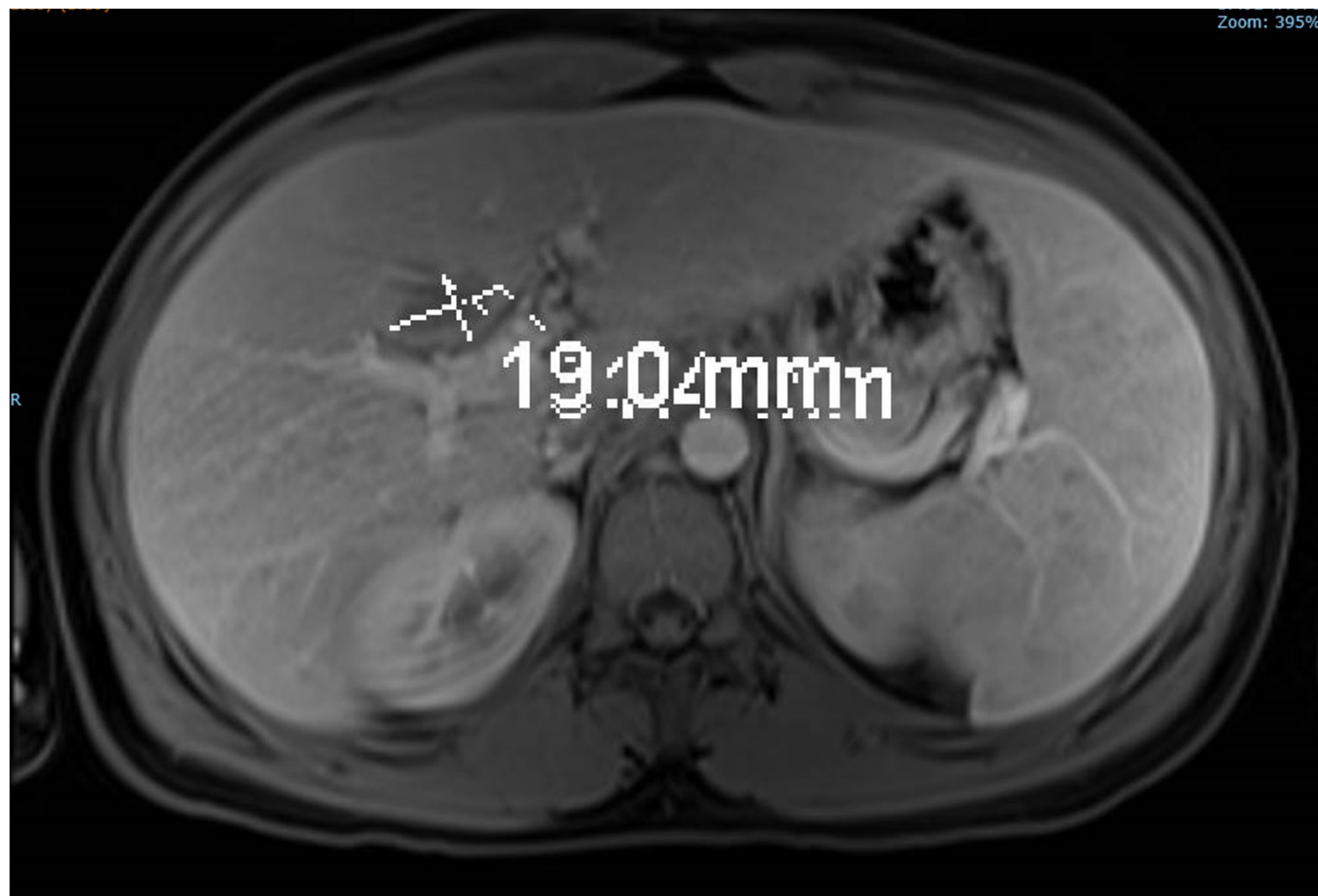
Fever of unknown origin with liver lesions

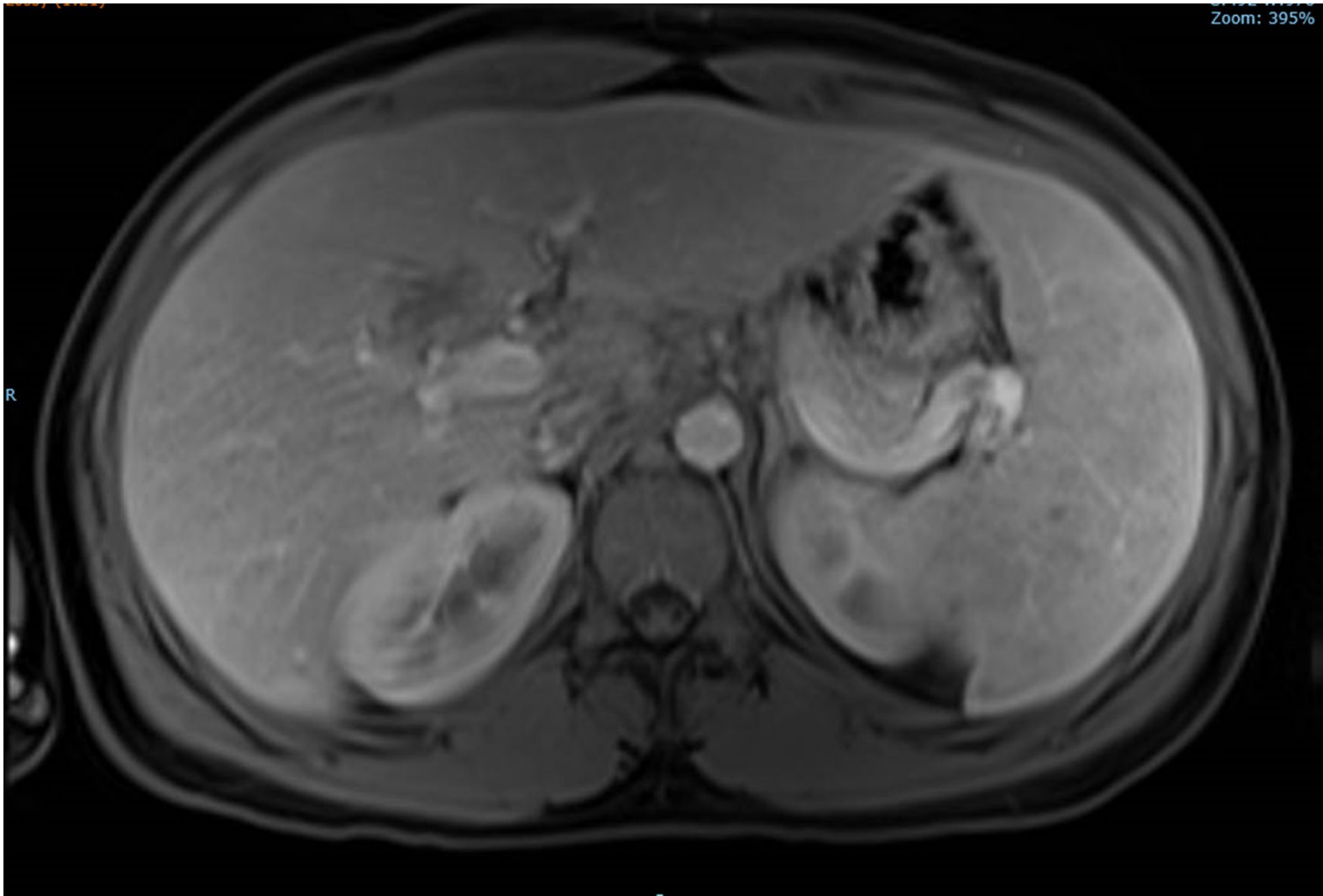
HingKiu Chan, MS4

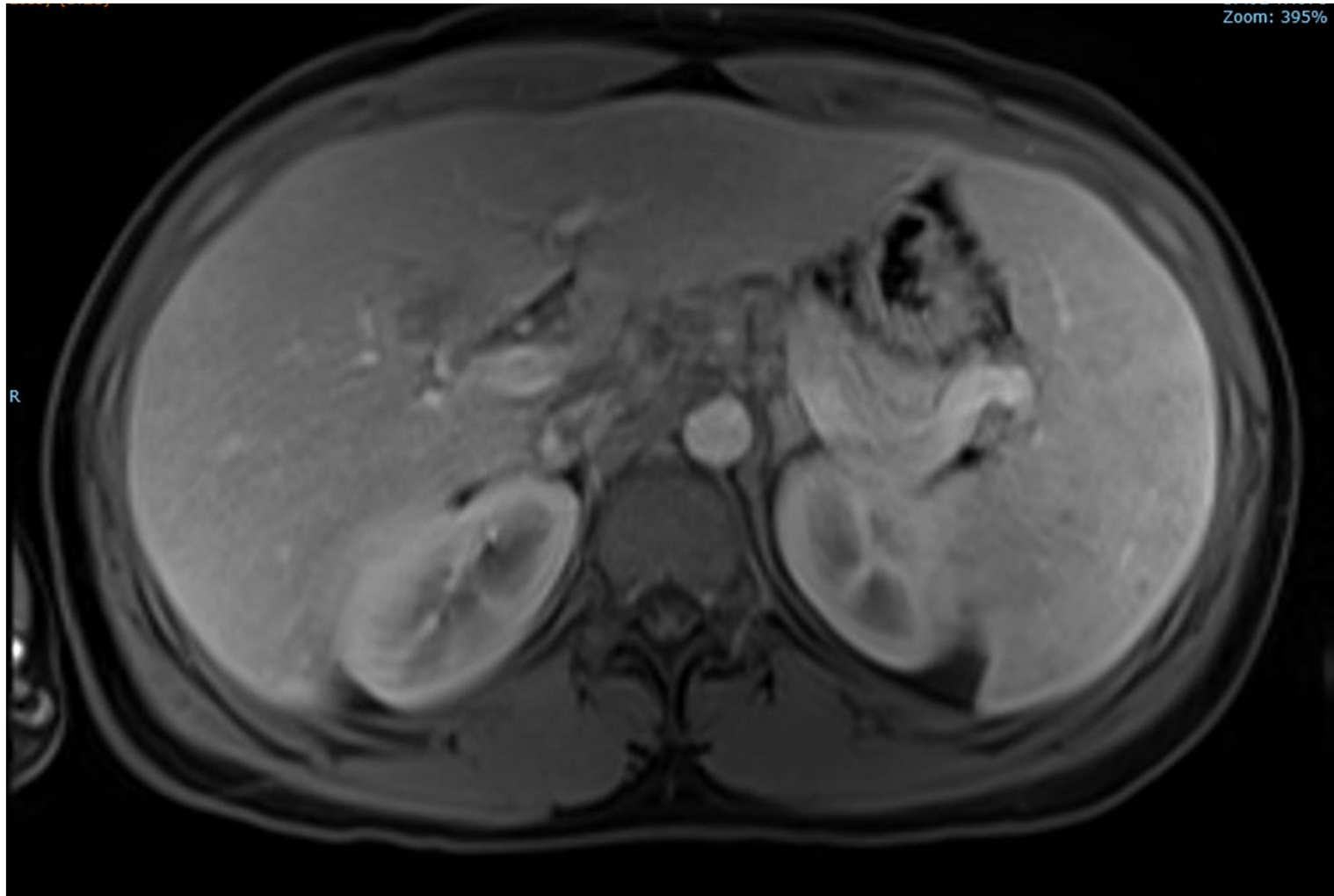
HPI

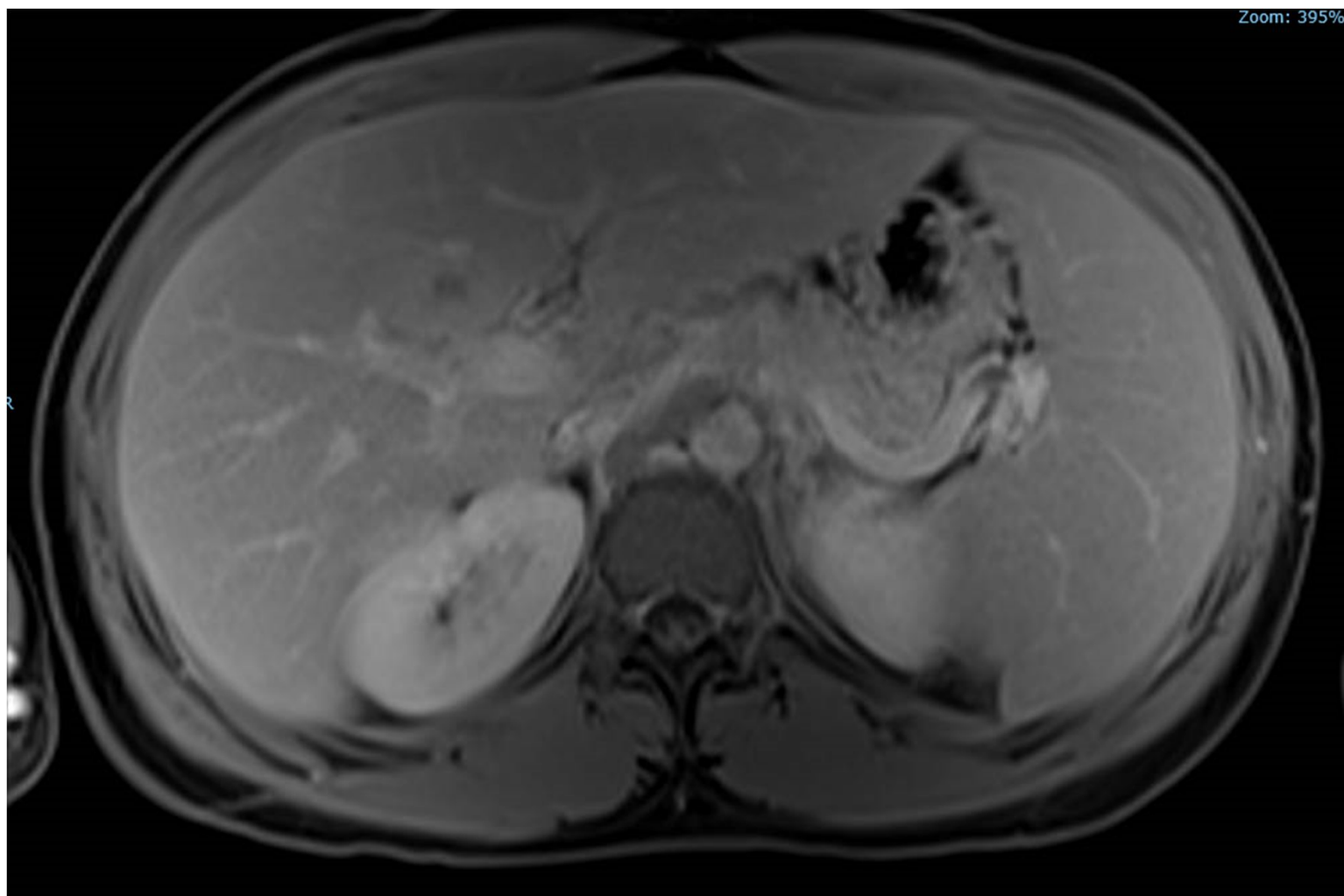
21 y.o man with history of Crohn's disease on immunosuppressive medications transferred from OSH presents with 3 weeks of fever and new lesions found on MRI. Associated symptoms include headache, nausea, non-bilious vomit, back pain, decrease appetite, RLQ pain that radiates to RUQ. Labs show transaminase. Blood and urine culture NGTD. No previous hx of PSC.



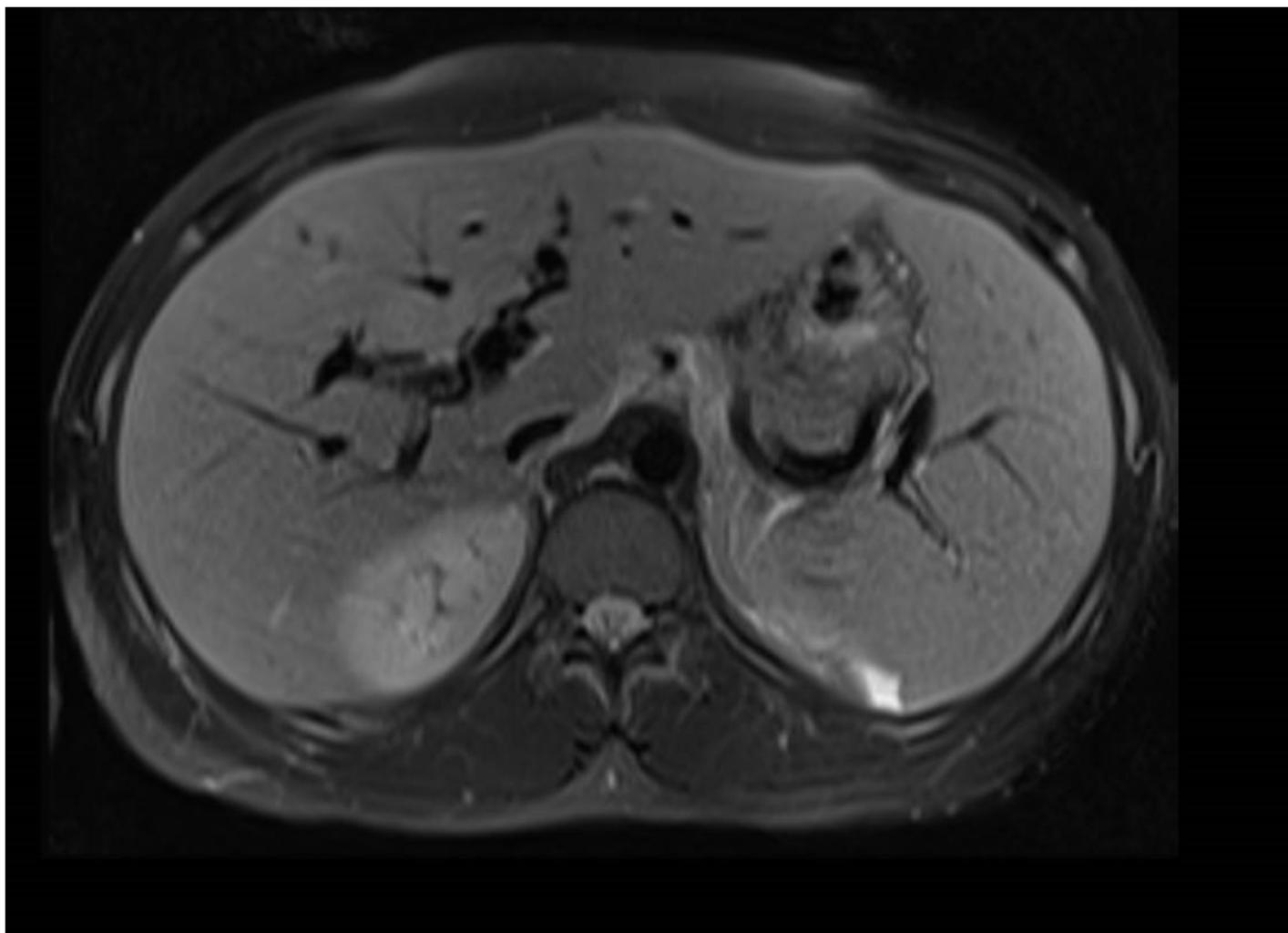


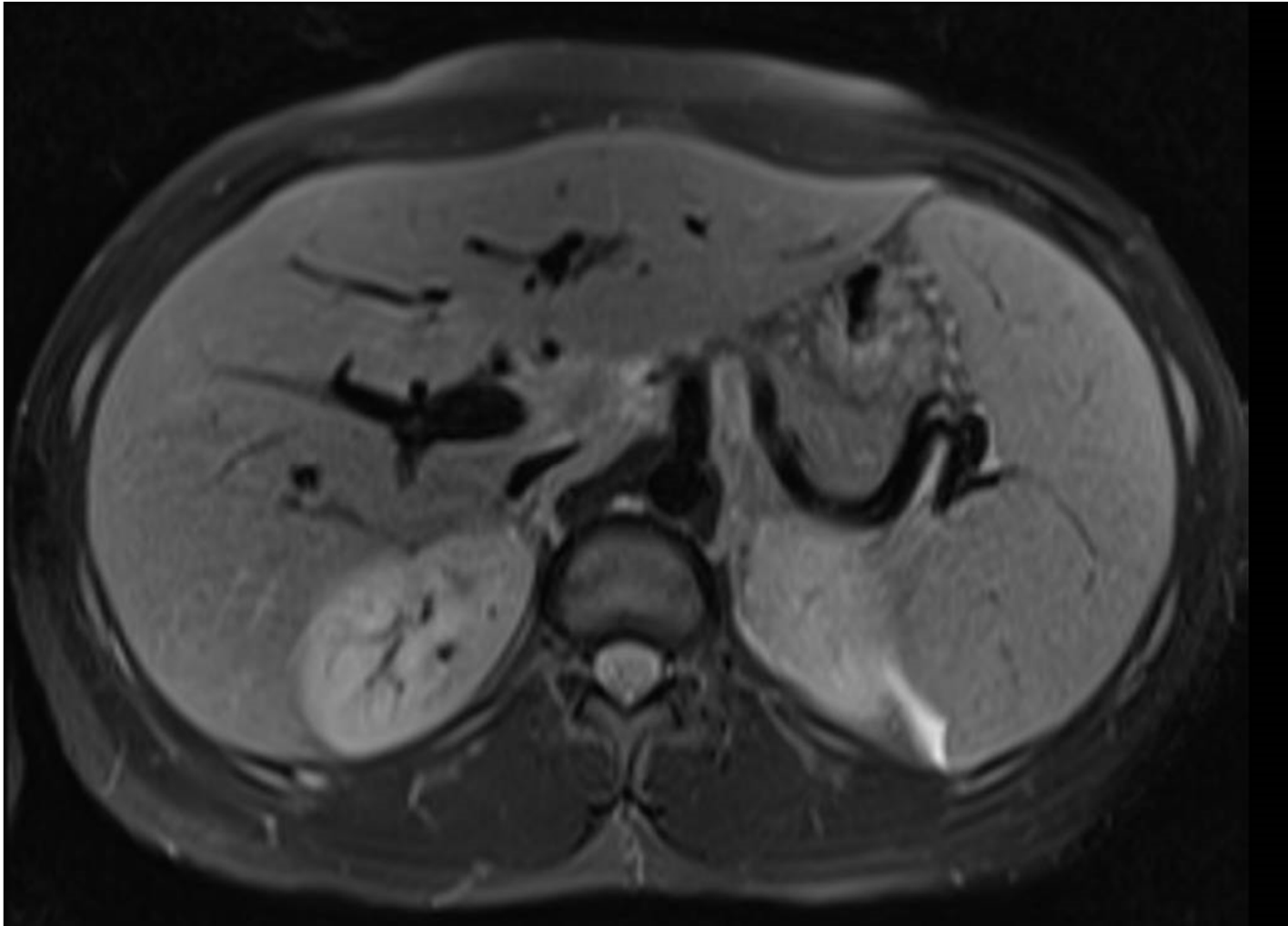


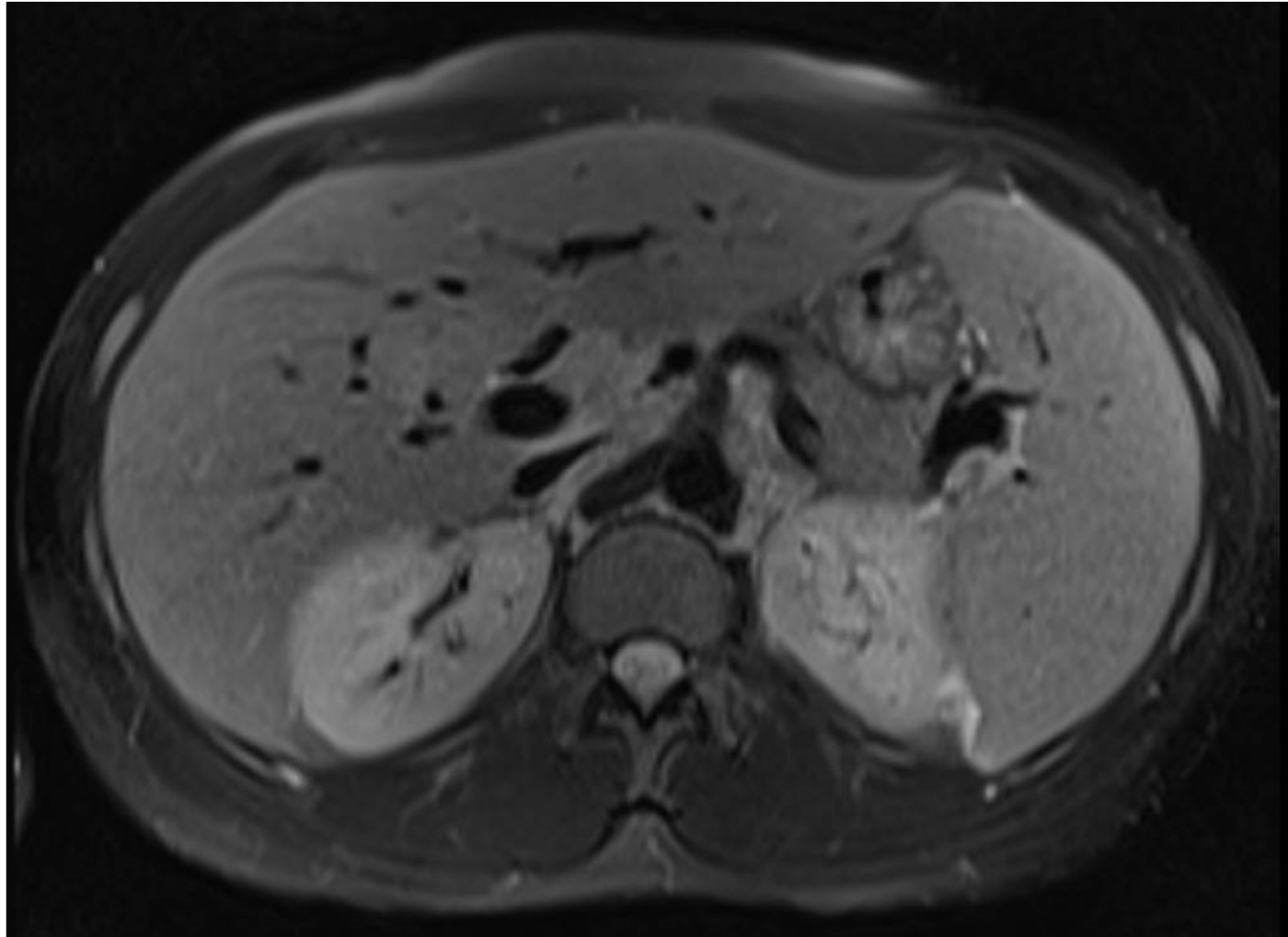




Zoom: 395%

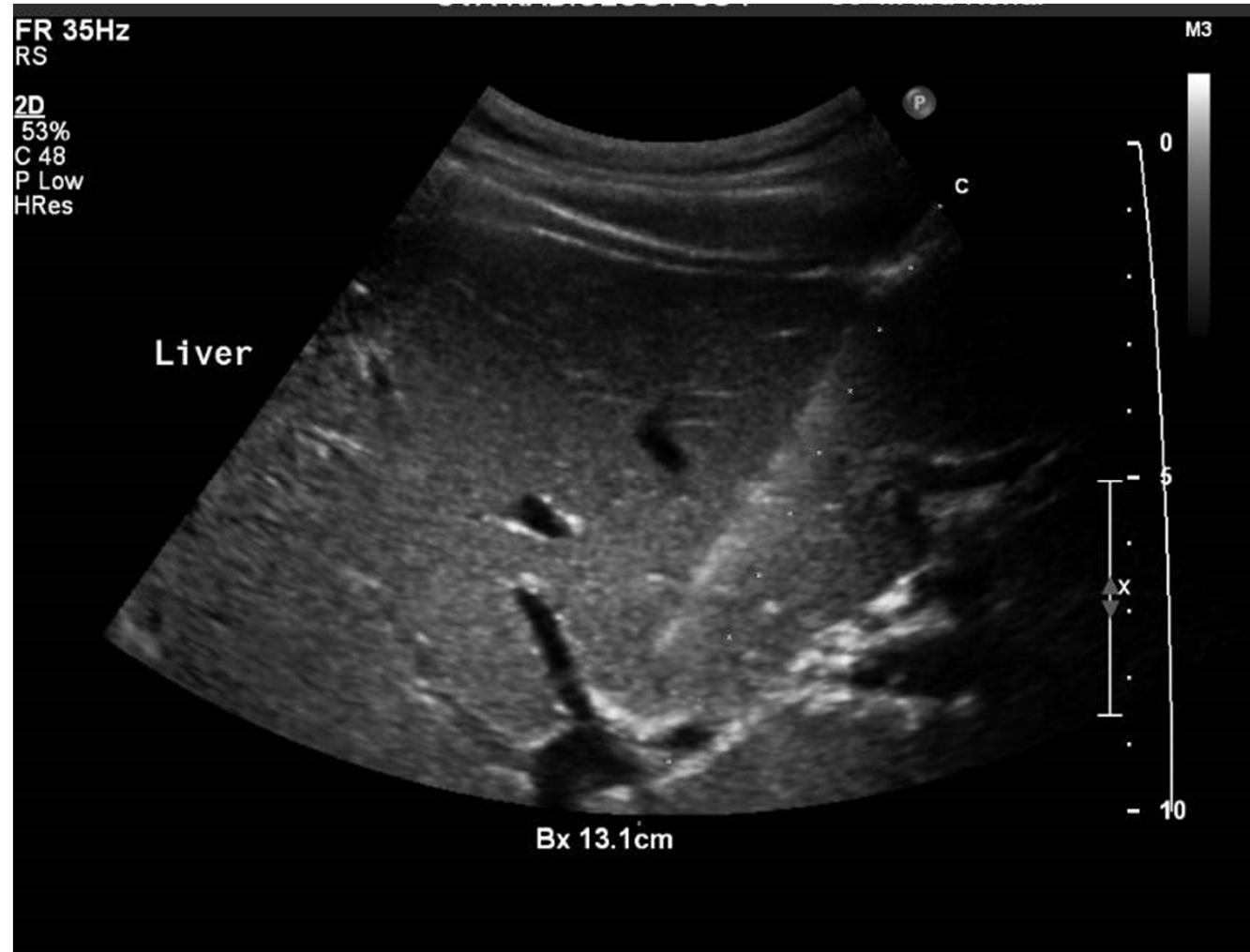

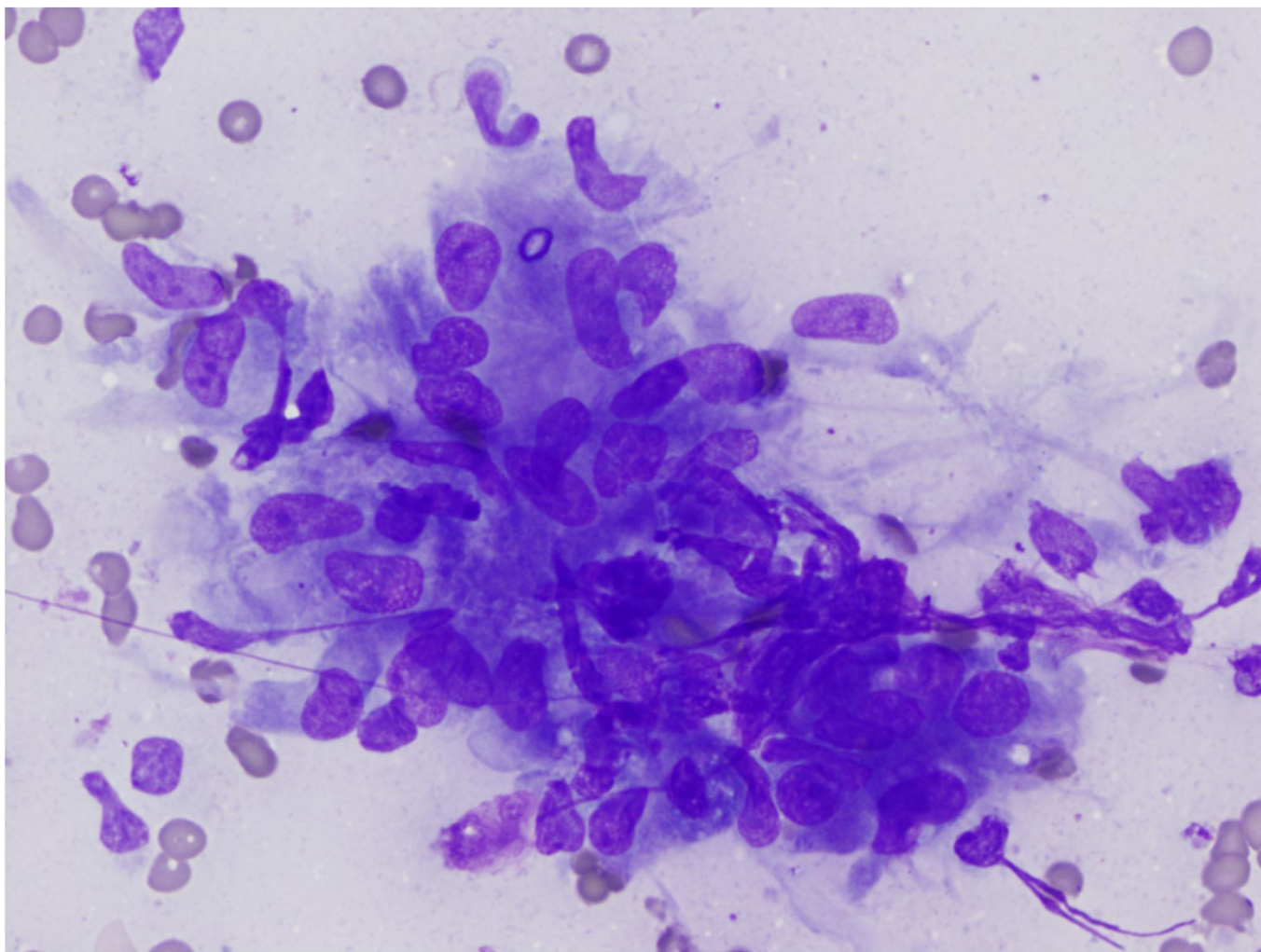


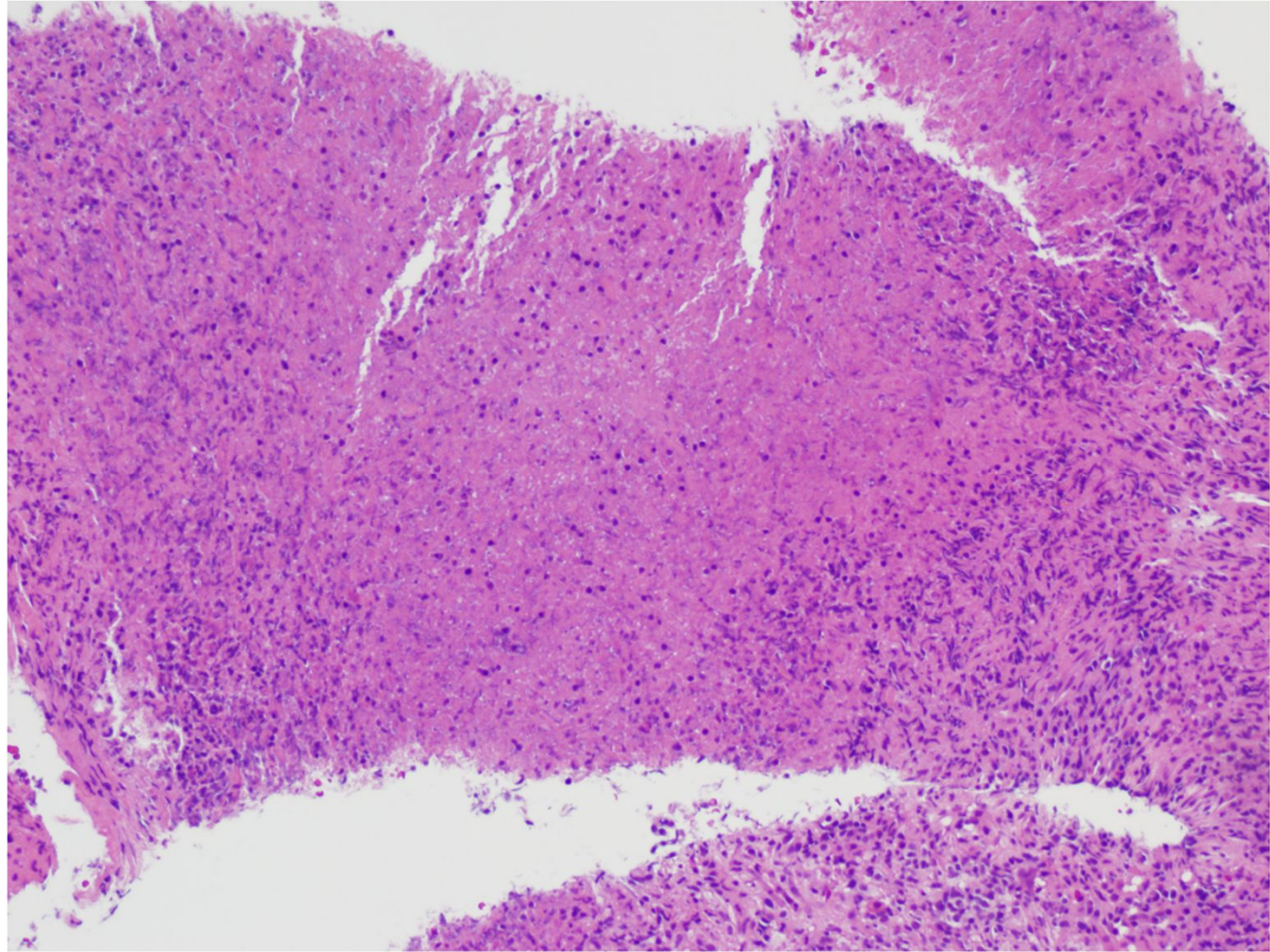


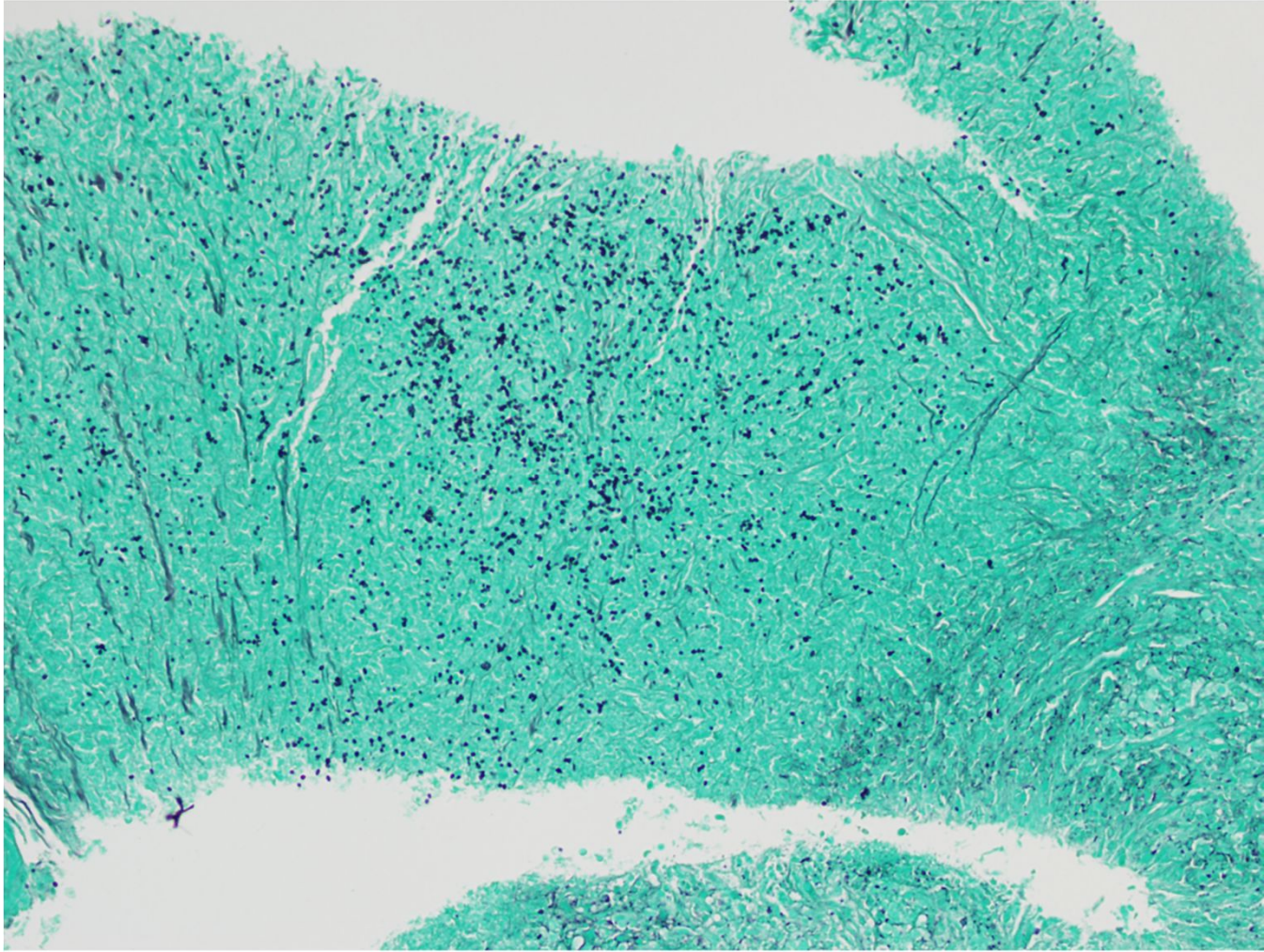
DDX

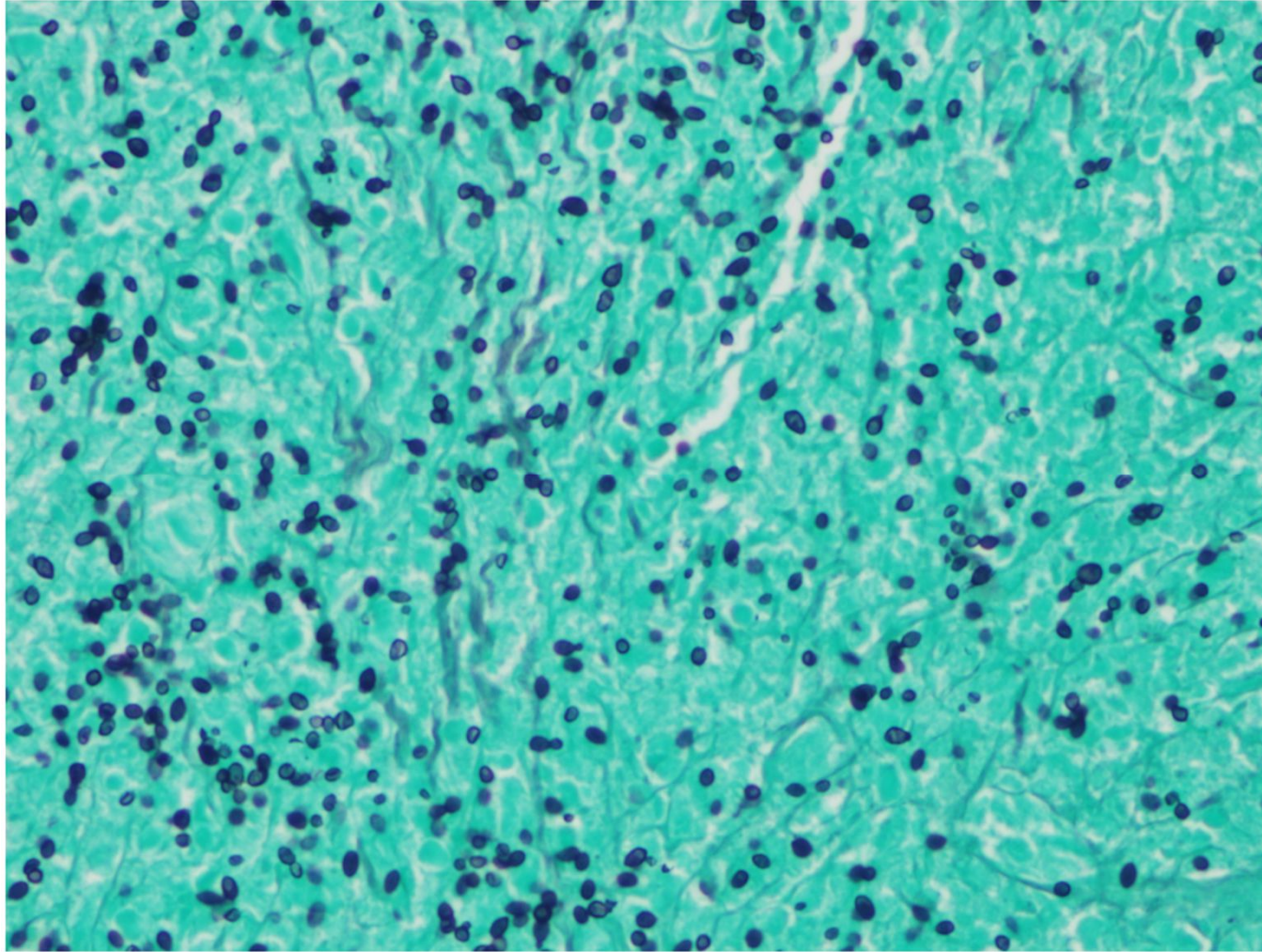
- Fungal infection
- Lymphoma
- Cholangiocarcinoma
- PSC
- Metastatic disease











Diagnosis

Disseminated Histoplasmosis

- Urine antigen was positive
- Patient's condition is mild/moderate and required 12 months of Itraconazole treatment and may need prophylaxis in the future
- Patient was discharged the next day